ACTA RADIOLOGICA

FOUNDED IN 1921 BY GÖSTA FORSSELL

PUBLISHED BY THE SOCIETIES OF MEDICAL RADIOLOGY IN DENMARK FINLAND NORWAY AND SWEDEN

DIAGNOSIS

MEDICAL IMAGING AND PHYSIOLOGIC RADIOLOGY

(Continued overleaf)

SUBSCRIPTIONS

Acta Radiologica		in Scandinavia	outside Scandinavia
Diagnosis (red) Oncology Radiation Physics Biology (blue)	both vols	Sw Kr 310 —	Sw Kr 335 —
Diagnosis	one vol	Sw Kr 200 —	Sw Kr 210 —
Oncology Radiation Physics Biology	one vol	Sw Kr 170 —	Sw Kr 180 —

All rates include regular mailing costs (surface mail)

All communications regarding advertising, subscription change of address, etc should be sent to Acta Radiologica P O Box 7449, S-103 91 Stockholm, Sweden

ACTA RADIOLOGICA

FOUNDED IN 1921 BY GÖSTA FORSSELL

PUBLISHED BY THE SOCIETIES OF MEDICAL RADIOLOGY IN DENMARK FINLAND NORWAY AND SWEDEN

DIAGNOSIS

MEDICAL IMAGING AND PHYSIOLOGIC RADIOLOGY

Vol 21 1980 Fasc 5

SUBSCRIPTIONS

Acta Radiologica		in Scandinavia	outside Scandinavia
Diagnosis — Medical Imaging and Physiologic Radiology (red) / Oncology incl. Radiation Therapy, Physics and Biology (blue)	both vols	Sw Kr 400 —	Sw Kr 425 —
Diagnosis	one vol	Sw Kr 260 —	Sw Kr 275 —
Oncology	one vol	Sw Kr 190 —	Sw Kr 205 —

All rates include regular mailing costs (surface mail)

All communications regarding advertising, subscription, change of address etc should be sent to Acta Radiologica, P O Box 7449, S-103 91 Stockholm, Sweden

ACTA RADIOLOGICA

FOUNDED IN 1921 BY GÖSTA FORSSELL

PUBLISHED BY THE SOCIETIES OF MEDICAL RADIOLOGY IN DENMARK FINLAND NORWAY AND SWEDEN

DIAGNOSIS

MEDICAL IMAGING AND PHYSIOLOGIC RADIOLOGY

Vol 21 1980 Fasc 6

SUBSCRIPTIONS

Acta Radiologica		in Scandinavia	outside Scandinavia
Diagnosis — Medical Imaging and Physiologic Radiology (red); Oncology incl. Radiation Therapy, Physics and Biology (blue)	both vols	Sw.kr 400.—	Sw.kr 425.—
Diagnosis	one vol	Sw.kr 260.—	Sw.kr 275.—
Oncology	one vol	Sw.kr 190.—	Sw.kr 205.—

All rates include regular mailing costs (surface mail)

All communications regarding advertising, subscription, change of address etc. should be sent to Acta Radiologica, P.O. Box 7449, S-103 91 Stockholm, Sweden

ACTA RADIOLOGICA

DIAGNOSIS 1980

4

ECTOMOGRAPHY

A new radiographic method for reproducing a selected slice of varying thickness

P EDHOLM G GRANLUND H KNUTSSON and C PETERSSON

A new radiographic principle for demonstrating a slice of the human body will now be described Because the slice is depicted as if it had been excised (ectomized) from the object the new principle is designated ectomography Its mathematical basis has been evolved and tested in experiments simulated with the aid of a computer but phantom experiments have not yet been carried out The procedure requires at least 60 projections of the anatomic volume under examination The projections should preferably be in digital form From this set of images a compound image is computed that can represent any slice in the object The appropriate position and thickness of the slice can thus be chosen after the set of projections has been recorded The thickness may range from that required for the slice to embrace the whole body down to just a few millimetres

Before explaining the principle for ectomography three closely related methods may be brought to mind conventional tomography tomosynthesis and computer tomography whose purpose is to produce images representing one particular slice in the object

In conventional tomography the image of irrelevant parts of the object is blurred during the exposure of the film while a sharply defined image is obtained of the desired plane the tomographic plane (ZIEDSES DES PLANTES 1934) This is effected by moving the ray source and the film plane according to a geometric relationship whereby the extent to which a detail is blurred is proportional to its distance from the tomographic plane Close to this plane the blurring is so slight that the viewer has the impression of a sharp image of a slice However the detail in this slice is distorted and as a result the conventional tomogram is inferior in contrast and definition to the conventional radiographic image (EDHOLM 1960) The isolation of the slice is incomplete and details outside it may still be perceptible in spite of the blurring

The principle underlying tomosynthesis has been known for some years (ZIEDSES DES PLANTES 1935) It consists essentially in the formation of a tomogram by the summation of a set of component images each corresponding to different projections of the object A number of techniques incorporating this principle have been designed (GROH 1971 1977 MEYER EBRECHT & WAGNER 1975) A particularly elegant one was devised by GRANT (1972) who also coined the term tomosynthesis

The tomographic plane is represented in each of the component images In the summation process these images are translated through a distance to a complete coincidence of the images of the tomographic plane The component images of a detail

From the Department of Diagnostic Radiology Regionsjukhuset S-581 85 Linkoping the Department of Electrical Engineering University of Linkoping S-581 87 Linkoping and The Department of Medical Engineering Karolinska Institutet S-104 01 Stockholm Sweden Submitted for publication 7 January 1980

outside the plane will not coincide exactly because successive images are slightly displaced and thus blurring of the detail occurs—as in conventional tomography.

As the number of component images is finite, the tomogram will be inferior in quality to a conventional tomogram. However, the method has the advantage that it is possible, from a single set of component images, to obtain a tomogram reproducing any desired plane of the object. In order to form a tomogram of a different plane, a summation image is produced through a larger or smaller translation of the component images.

Iterative techniques for improving the tomosynthesis tomogram have been proposed by COLSHER & HART (1975), COLSHER (1977) and GROH (1977).

The image obtained in computer tomography represents an actual slice of the object having a given thickness (HOUNSFIELD 1972, BROOKS & DI CHIRO 1975). This image is produced by the summation of many component images, each being a one-dimensional projection of the slice, the projection is parallel to the slice. Before the summation, each component image is modified by filtering its spatial frequencies. In this way a distortion free image of the slice is obtained.

The principle of ectomography

Ectomography is based on a projection system similar to that used in tomosynthesis. From N equally spaced tube positions located on a horizontal circle above the patient lying on a couch, N images of the object are projected onto a horizontal image detector positioned below the couch and also moving in a horizontal circle.

In order to explain the physical implications of ectomography it is useful first to consider the image obtained when the system is used to produce a conventional summation tomogram, as in tomosynthesis, and to compare the reproduction of a detail in the sharply depicted tomographic plane with that of one outside this plane. Both details are represented in each component image. The component images of the detail in the tomographic plane, which coincide exactly, are summed up. The images of a detail outside the plane will not coincide completely because their centres will be displaced on a circle, the diameter of this circle varying with the distance of the detail from the tomographic plane. Thus, the summation image of the detail will be blurred due to

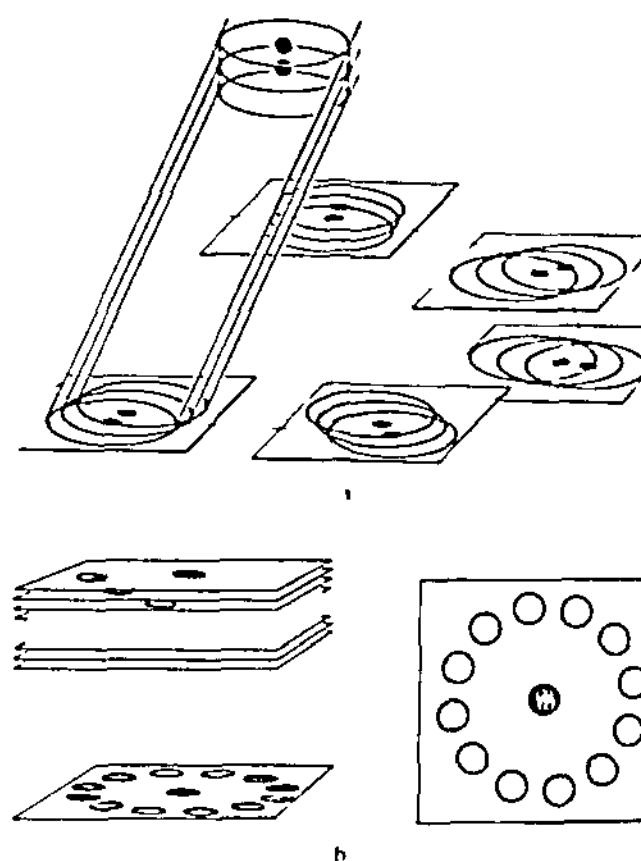


Fig. 1. Tomography by summation of component images. a) Pr... ciple for projecting the component image. The tube (not see... projects the object from positions on a circular tract. The object... a cylinder. It contains one detail in the tomographic plane and o... at a distance above the plane. Both details are reproduced in... the component images. b) Left. After translation of each com... ponent image through an appropriate distance, the images can... added to give a summation tomogram depicting the tomograph... plane. Right. The tomogram. The component images of the det... outside the tomographic plane do not coincide. Their centres l... on a circle of blur and form a ring. The component images of th... detail in the tomographic plane coincide and are added to give th... image in the centre of the tomogram.

the displacement of the component images on th... circle. This will be referred to as the circle of blur.

If the detail outside the tomographic plane is sma... in relation to the circle, the component images wi... not overlap. If the number of component images is N, the amplitude of each in the summation image wi... be 1/Nth of that for a detail in the tomographic pla... (Fig. 1). If N is large enough, this reduction w... presumably suffice for the detail not to be perceive... However, if the detail is slightly larger in relation t... the circle of blur, the various component images w... overlap. In these areas of overlap the amplitude ... the detail will be greater. With a further increase ... the relative size of the detail three component im... ages may overlap, and so on. The amplitude of th... detail may then be so great that the ring of its com... ponent images on the circle of blur will be perceive...

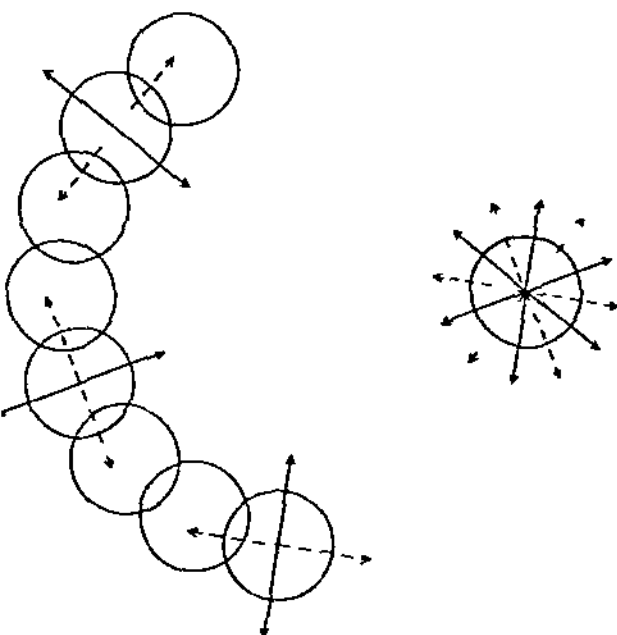


Fig 2 In ectomography each component image is submitted to high pass filtration tangential to the circle of blur (interrupted arrows) and low pass filtration in a radial direction to this circle (solid arrows) The directions of filtration are indicated for 3 component images Left Detail outside the tomographic plane Part of the ring formed in the tomogram by overlapping component images As a result of the high pass filtration the various component images partially extinguish each other The low pass filtration renders the contours of the annulus of the component images less clearly perceptible Right Detail in the tomographic plane is reproduced with high pass filtration This is reduced by the low pass filtration

However it is possible to prevent this build up in amplitude

In ectomography the spatial frequencies of the component images are subjected to both high and low pass filtration in mutually perpendicular directions before the images are summed to give the final image

High pass filtration In conventional linear tomography the image is impaired by stripes caused by the blurring of details outside the tomographic layer These disturbing stripes can be eliminated from the tomogram by submitting it to high pass filtration of its spatial frequencies in the direction of the stripes (EDHOLM & QUIDING 1970) Analogously high pass filtration is utilized in ectomography to eliminate the circle of blur Each component image is submitted to high pass filtration of its spatial frequencies in the direction of the tangent to the circle of blur The component image of the detail then has no zero frequency In the tangential direction it consists of both positive and negative components so that a line integral through the image in this direction will have the value zero If a summation image is produced by repeated summation of this high pass filtered component image and between each summation the component image is translated a small distance in the tangential direction the value of a line integral in this summation image in the tangential direction is also zero Like each component image the summation image will contain both positive and negative components and when the various component images overlap they will largely extinguish each other However in ectomography the component images of a detail outside the tomographic plane are translated not along a straight line but along the circle of blur If the number of component images is large enough—more than about 60—the part of the circle of blur associated with the extinction will be so small that it may be considered a straight line and thus the component images in effect extinguish each other

The effect of this high pass filtration on the detail in the tomographic plane is quite different Because the component images of the detail coincide they will not extinguish each other When all the images have been summed a small detail is represented in the summation image with full amplitude The direction of filtration is altered from one component image to the next by an angle $2\pi/N$ The detail in the summation image will therefore be subjected to high pass filtration in all directions

Low pass filtration The effect of high pass filtration on the detail in the tomographic plane is compensated for in some measure by submitting the component images not only to high pass filtration in the tangential direction but also to some degree of low pass filtration perpendicular to this direction (Fig 2) This low pass filtration has two other desirable effects

The first is that the summation image will represent a true slice instead of a plane The projection of the normal to the tomographic plane on a component image will be parallel to the direction of low pass filtration (Fig 3) In the summation image the low pass filtration for all component images therefore has the effect of low pass filtration in the direction perpendicular to the tomographic plane By a suitable choice of low pass function it is possible to obtain a summation image in which each image point corresponds to an integration over a given distance in the object perpendicular to the tomographic plane The summation image now depicts a slice with a thickness corresponding to the length of this integration The image appears to be a repro

duction of this slice by rays coincident with this direction of integration In this connection it is useful to recall that in a conventional radiographic image each point represents an integration through the entire exposed volume along the ray from its source to the film plane The larger the band width in low pass filtration the thinner the slice to which the image corresponds

The second desirable effect of low pass filtration concerns details outside the slice In conventional tomography without filtration such a detail with high contrast will cause a circle of blur that will be perceived as an annulus what is actually perceived is the sharp outer and inner contours of this ring In ectomography the perceptibility of the detail outside the slice is already effectively reduced by the high pass filtration The direction of the low pass filtration for each component image is such that any remaining contours of the annulus will be blurred and their perceptibility thus further reduced

To summarize low pass filtration has three desirable effects it reduces the high pass filtration of detail in the slice it converts the image from a reproduction of a tomographic plane to a distortion free image of a slice the thickness of which may be chosen at will and it reduces further the perceptibility of details outside the slice

Mathematical analysis of the principle

The principle was derived intuitively more or less as indicated By using appropriate mathematical models the validity of the reasoning was tested and filter functions with the desired properties were proposed (KNUTSSON et coll 1980) By comparing the computed contributions made to the image by a small detail located in the tomographic plane and one located at a distance from this plane mathematical expressions were derived that described various properties of the reconstructed image Three such descriptive expressions have been used The first provides a measure of the amplitude with which the small detail is reproduced—referred to as the signal strength The second expression provides a measure of the resolution of the image—referred to as signal resolution The third expression provides a measure of a property—referred to as signal distortion These descriptive expressions were used to test the effect of different filters on the reconstructed image

The filtration of the component images was per

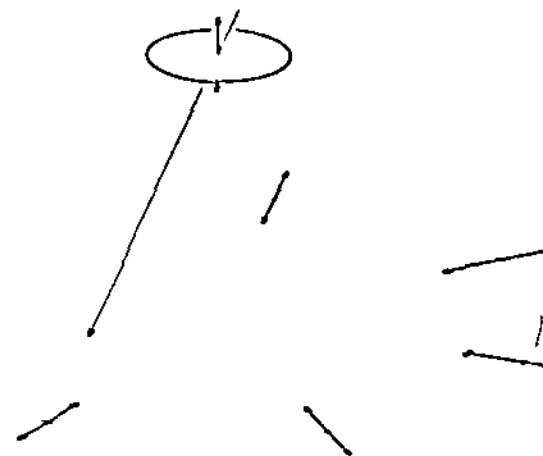


Fig 3 The normal to the tomographic plane is projected par to the direction of the low pass filtration (solid arrows) fo component images

formed by multiplying their Fourier transforms the following two-dimensional weighting functior

$$F(\omega_a\ \omega_b)=\left[\sin\left(\frac{\pi}{B_1}\omega\ \right)\right]\times\left[1+\cos\left(\frac{\pi}{B}\omega_b\right)\right]$$

$$\text{for}\ \begin{cases}|\omega_a|\leq\\|\omega_b|\leq\end{cases}$$

$$F(\omega\ \ \omega_b)=0\quad\text{for}\ \begin{cases}|\omega_a|>B_1\\|\omega_b|>B_2\end{cases}$$

where B_1 and B denote the band widths in the hi pass and low pass directions respectively By g ing B_1 and B different values four filters F_1– were dimensioned

	F_1	F_2	F_3	F_4
B_1	1	0 71	0 82	0 88
B	1	0 71	0 41	0 25

Because B decreases in magnitude from F_1 to these filters provide an increasing degree of lo pass filtration

The effect of these four filters has been compar with that of another filter whose sole purpose was limit appropriately the band width of the compone images This weighting function whose applicati results in an effect equivalent to that obtained wi conventional summation tomography was

$$F(\omega\ \ \omega_b)=[1+\cos(\pi\omega_a)]\times[1+\cos(\pi\omega_b)]$$

It will be referred to as F_0

Results

The variation of signal strength signal distorti and signal resolution with the distance of a de

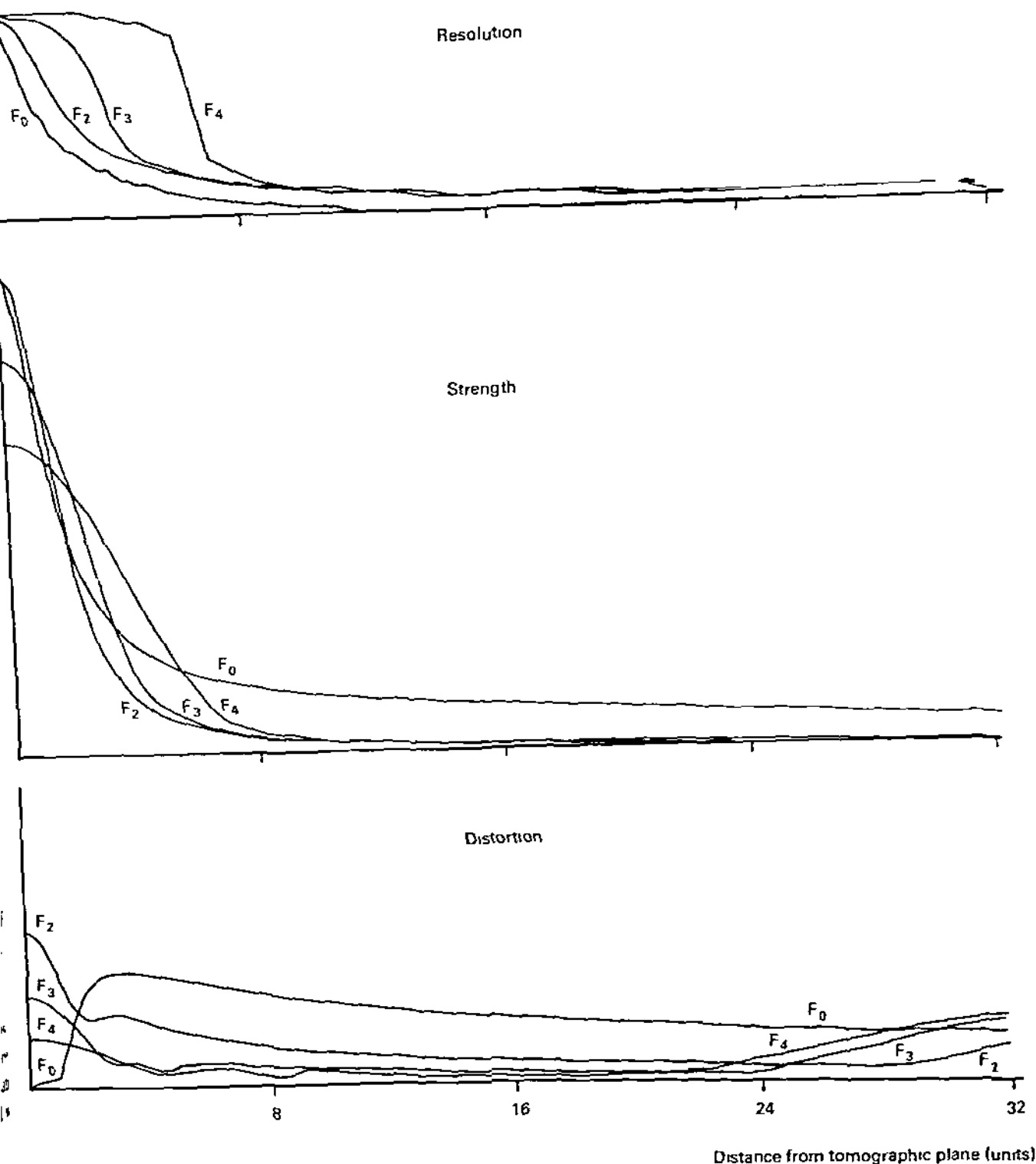


Fig 4 The variation of the 3 quantities signal resolution signal strength and signal distortion with distance from the tomographic plane For each quantity 4 curves are shown representing conventional tomography F_0 and ectomography with the filters F_2–F_4

from the tomographic plane is represented by the curves in Fig 4 The relationships are shown for conventional summation with the filter F_0 and for ectomography with the three filters F_2–F_4

The curves for filter F_0 are consistent with experience of the way in which a detail is reproduced in conventional tomography The signal strength and distortion are considerable even for details located


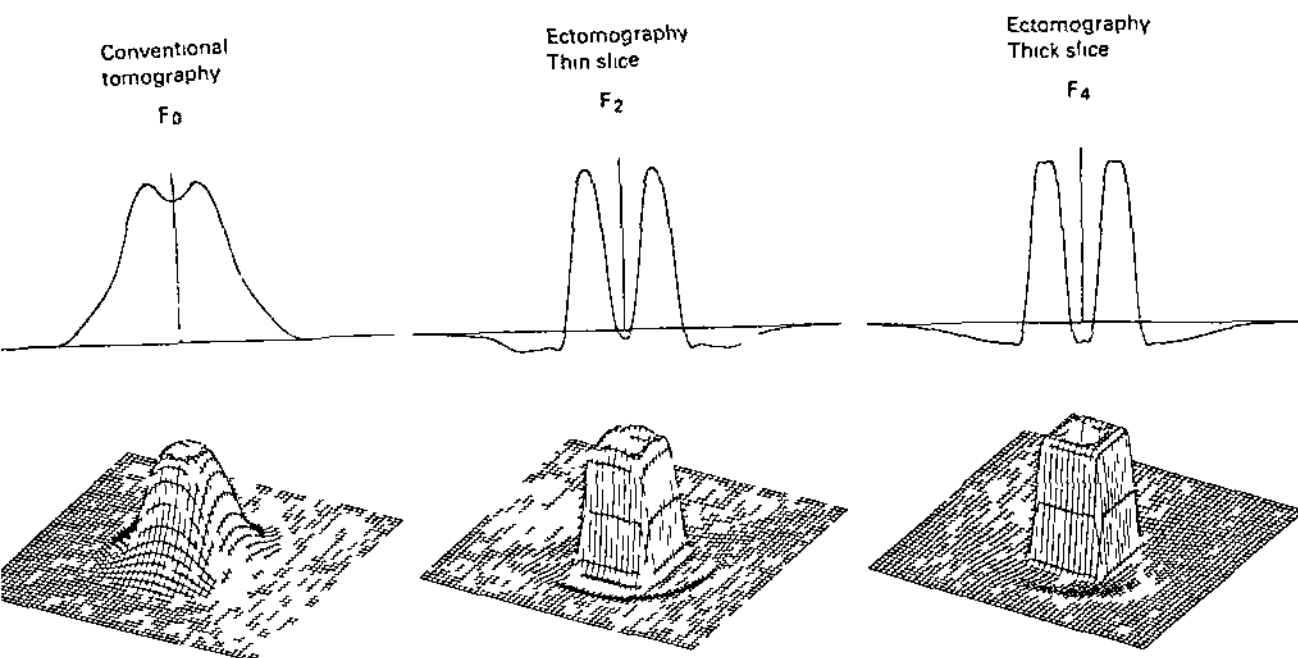


Fig 5 Images of a square of side 1 = units The difference between conventional tomography and ectomography The 5 rows show the appearance of the images with the square located at different distances from the tomographic plane

far from the tomographic plane whereas the resolution falls off very rapidly with the distance from this plane

As the curves for the three filters F_2–F_4 show in ectomography the resolution is uniform and high up to a certain distance from the tomographic plane Thus the image represents a slice of a certain thickness having the tomographic plane as its mid plane The thickness of this slice is greatest for the filter F_4 which has a low pass component with the narrowest band width

Within the slice some signal distortion occurs because of the high pass filtration The signal strength is greatest in the tomographic plane and decreases steadily towards the two bounding surfaces of the slice Outside the slice there is a fairly large region within which the values for the strength resolution and distortion of the signal are very low At a certain



g 6 Lower row Images of a tube of square cross section ented perpendicular to the tomographic plane which passes ough the centre of the tube They show the difference between tomography and ectomography Upper row Sections through the centre of the images

istance from the tomographic plane the distortion f the various filter functions begins to increase and is continues until the distortion is similar to that or the conventional tomogram The reason for the icrease in distortion is that at this distance the ircle of blur is so large that the component images f small details no longer extinguish each other The egion of very low distortion may be enlarged by ncreasing the number of component images

The effect of the filter functions tested was much is expected namely to modify the summation im ige so that it represents a well defined slice the detail throughout which is reproduced with high re solution and a certain degree of high pass filtration Details outside the slice are eliminated much more completely than is the case at conventional tomo graphy

Experiments in ectomography simulated with a computer

The whole process was simulated in a computer in which component images of various objects were synthesized filtered and compounded to form sum mation images (PETERSSON et coll 1980) These im ages were presented as plotted perspective figures depicting three-dimensional reliefs

Both component and the summation images measured 64×64 pixels Each summation image was composed of 64 component images It was assumed that for each component image the rays were paral lel and that the 64 projections for the component images were uniformly distributed over the curved surface of a cone

Model objects

In the experiments 6 objects were used with 3 sizes of each making 18 objects in all

Square A plane square of side $9/\pi$ $17/\pi$ and $33/\pi$ units Oriented parallel to the tomographic plane

Frame A plane square of side $27/\pi$ $51/\pi$ and $99/\pi$ units containing a square hole of side $9/\pi$ $17/\pi$ and $33/\pi$ units respectively Oriented parallel to the to mographic plane

Rectangular prism A prism its cross section a square of side $9/\pi$ $17/\pi$ and $33/\pi$ units Altitude 21 units Oriented perpendicular to the tomographic plane

Tube Cross section shape and dimensions as for the frame Altitude 21 units Oriented perpendicular to the tomographic plane

Oblique rectangular prism Section parallel to the tomographic plane shape and dimensions as for the square Altitude 21 units Oriented at an angle to the normal to the tomographic plane

Oblique tube Section parallel to the tomographic

plane shape and dimensions as for the frame. Altitude 21 units. Oriented at an angle to the normal to the tomographic plane.

Filters

The filters used in the theoretical analysis of the principle were also employed in the experiments simulated with a computer. Thus F_0 was used to produce images representing the results of conventional summation tomography to serve as a reference for the evaluation of the four filter functions F_1–F_4.

Images

A series of images was produced for each of the five filter functions F_0–F_4.

Summation images of the plane objects square and frame were computed at the distances 0, 1, 2, ... 10, 25 units from the tomographic plane. Summation images of the 12 three-dimensional objects prisms and tubes were produced with the object positioned so that the tomographic plane passed through its centre. Altogether 420 images were produced in this way.

Results

The images were fairly consistent with the analysis of the properties of the images derived by applying the three descriptive expressions. Some of the plotted reliefs appear in Figs 5 and 6. The effect of filtration is evident in Fig. 5, showing a square reproduced in the tomographic plane and at various distances from it, both with conventional tomography (filter F_0) and with ectomography (filters F and F_4).

When the square lies in the tomographic plane, the conventional tomographic image of this plane figure contains no distortion. This image may be taken as a reference for the evaluation of the other images. In ectomography the images of the square object in the tomographic plane contain some deformation due to the high pass filtration.

When the square is at a distance from the tomographic plane the image in the conventional tomogram is deformed and its resolution decreased. In ectomography the square is still reproduced sharply for a distance of 1 unit from the plane, and in the case of filter F_4 also for the distance 4 units. For distances of 4 and 8 units the images in conventional tomography contain a definite ring of blur, whereas in ectomography this ring is greatly damped in th[e] images corresponding to filter F. For the distance [...] units the image corresponding to filter F_4 conta[ins] no more than an almost imperceptible trace of th[e] square.

A plane square is not, of course, a radiographica[l]ly realistic object. As such objects are three-dime[n]sional, the conventional tomographic image is a[l]ways to some extent distorted. This is clearly illu[s]trated in Fig. 6: the conventional tomogram of th[e] tube contains marked distortion, whereas the ect[o]mograms provide a largely true representation o[f] the object.

Discussion

The properties of the ectomographic image hav[e] been analysed mathematically and demonstrated b[y] experiments simulated with a computer. From a se[t] of component images of an object a summation im[]age may be reconstructed that represents a well de[]fined slice of a given thickness, while detail outsid[e] this slice is for all practical purpose eliminated. Th[e] image of the slice is slightly distorted due to high[]pass filtration of its spatial frequencies. This shoul[d] not necessarily imply an impairment.

In the experiments simulated with a computer th[e] rays have been assumed to be parallel, whereas i[n] the practical application of the method the rays wil[l] be divergent. However, the present analysis remain[s] essentially valid, the only difference being that th[e] slice will appear to have been projected with ray[s] emanating from the centre of the circle described b[y] the tube during the exposures.

The thickness of the slice may be varied by chang[]ing the band width of the low pass filtration. If the slice is just thick enough to contain the object under examination, interfering structures in front of and behind the object will not be included in the image, which will then depict the organ as if it has been ectomized and exposed. If the slice is thick enough to contain the whole body, the ectomogram wi[ll] resemble an ordinary film with high contrast res[o]lution. Lastly, if the slice is only a few millimetre[s] thick, the ectomogram will resemble a compu[ter] tomogram.

Ectomography is thus a general method enabling a range of images to be produced, from those resem[]bling ordinary radiographic images to those resem[]bling computer tomograms.

There are certain similarities between ecto[m]...

graphy and computed tomography In both methods a large number of component images is compounded to form an image of a slice having a required thickness An element of a component image represents a surface integral through the irradiated volume In computer tomography this surface is defined by the plane segment formed by the rays from the focus to the detector (the width of the detector parallel to the slice is disregarded) In ectomography the surface integral corresponds to the plane segment defined by the oblique ray to an image element and a segment of a line perpendicular to the film the length of the segment depending on the degree of low pass filtration In both methods each component image is also subjected to high pass filtration in a direction perpendicular to the surface of integration As a result those component images that do not coincide will extinguish each other in the summation image

Ideally the implementation of the principle of ectomography clearly requires a detector capable of receiving and digitizing two dimensional projections just as the detector array in a CT scanner deals with one dimensional projections Such a unit would consist of a two dimensional array of detectors but no such array seems to have been produced Among the various ways of obtaining digital images directly one is to scan the patient with a one dimensional detector array in a direction perpendicular to it

The ectomographic principle might also be implemented by using an ordinary screen film combination as a detector but then the digital images would not be available until the films have been exposed processed and digitized While such a system has several drawbacks it could be realized with existing equipment The exposures could be made in an ordinary unit for circular tomography with the tube following a circular track above the patient and the films being exposed in a film changer located beneath the patient The dose to the patient should be reduced by using fast intensifying screens and possibly also by pre-exposing the films to ordinary light As the latter measure would reduce the contrast in the image it would offer the further advantage of an increase in latitude This would make it easier to keep the density of the images within the linear range of the film s characteristic curve The reduction in the dose to each film will decrease the signal to noise ratio However in the reconstructed summation image this ratio will be higher than for a conventional film because it will depend on the total dose to all the films

The component images so obtained would be digitalized to provide matrices 512×512 or even 1024×1024 These matrices would then be submitted to computerized Fourier transformation filtration and conversion back to real images which could then be summed up with different degrees of translation to demonstrate different slices of the object This operation could be accomplished by means of currently available techniques with reasonable computation times The images obtained could then be presented on display units such as those used in computer tomography It might be some time before this whole process is completed but the patient need not be detained on this account As any slice of the irradiated volume may be reconstructed from the set of component images one scan producing such a set would suffice

SUMMARY

The mathematical basis is described of a new radiographic method by which an arbitrarily thick layer of the patient may be reconstructed The reconstruction is performed from at least 60 images of the volume under examination Each of the e images which have to be in digital form is subjected to a special filtration process of its spatial frequencies The combination of all the images will form the resulting image of the layer—the ectomogram The method has been analysed and tested in experiments simulated with a computer

ACKNOWLEDGEMENT

A research grant (No 75-4027) for this investigation has been made available by the National Swedish Board for Technical Development

Request for reprints Prof Paul Edholm Department of Diagnostic Radiology Regionsjukhuset S 58185 Linkoping Sweden

REFERENCES

BROOKS A R and DI CHIRO G Theory of image reconstruction in computed tomography Radiology 117 (1975) 561

COLSHER J G Iterative three-dimensional image reconstruction from tomographic projections Computer Graphics and Image Processing 6 (1977) 513

— and HART R G Comparison of algorithms for three dimensional image reconstruction from a series of conical projections *In* Technical digest of topical meeting on image processing for 2 D and 3 D reconstruction from projections ...

CORMACK A M Representation of a function by its line integrals with some radiological applications I J appl Physiol 34 (1963) 2722
— Representation of a function by its line integrals with some radiological applications II J appl Physiol 35 (1964) 2908
EDHOLM P The tomogram Its formation and content Acta radiol (1960) Suppl No 193
— and QUIDING L Elimination of blur in linear tomography Acta radiol Diagnosis 10 (1970) 441
GRANT D G Tomosynthesis A three-dimensional radiographi imaging technique IEEE Trans Biomed Engn BME 19 (1972) 20
GROH G Holographic tomography using a circular synthetic aperture Appl Optics 10 (1971) 2549
— Tomosynthesis and coded aperture imaging New approaches to 3-dimensional imaging in diagnostic radiography Proc roy Soc Lond B 195 (1977) 299
— and KOCK M 3 D display of X ray images by means of holography Appl Optics 9 (1970) 775
HOUNSFIELD G N A method of and apparatus for examination of a body by radiation such as x or gamma radiation The Patent Office London Patent Specification 1283915 (1972)
KNUTSSON H EDHOLM P GRANLUND G H and PETERSSON C Ectomography A new radiographic reconstruction method Theory and error estimates To be published in IEEE Trans Biomed Engn
KOCK M and SCHMITT H J Tomosynthesis Holographic methods for variable depth display 3rd Int Conf on Medical Physics including Medical Engineering Chalmers University of Technology Gothenb Sweden 1972
MEYER EBRECHT D and WAGNER W On the applica of ART to conventional x ray tomography *In* Technical digest of topical meeting on image processing f 2 D and 3 D reconstruction from projections Stanf California 1975
MILLER E R McCURRY E M and HRUSKA B B simplified procedure for viewing multiple film create an infinite number of laminagrams Radiology 110 (1973) 365
PETERSSON C EDHOLM P GRANLUND G H an KNUTSSON H Ectomography A new radiograph reconstruction method Computer simulated ex periments To be published in IEEE Trans Biomed Engn
ZIEDSES DES PLANTES B G Planigraphie en subtra tie rontgenographische differentiatiemethoden (I Dutch) Kemink en Zoon N V Utrecht 1934
— Seriescopie een rontgenographische methode welk het mogelijk maakt achtereenvolgens een oneindig aan tal evenwijdige vlakken van het te onderzoeken vo werp afzonderlijk te beschouwen (In Dutch) Ned T Geneesk 79 (1935) 5852
— Serieskopie Eine rontgenographische Method wel he ermoglicht mit Hilfe einiger Aufnahmen ein unendli he Reihe paralleler Ebenen in Reihenfolg gesondert zu betrachten Fortschr Rontgenstr 5 (1938) 605

ROM THE LABORATORY OF ELECTRON MICROSCOPY (DIRECTOR ASSOC PROF T NEVALAINEN) UNIVERSITY OF TURKU SF 705 0 TURKU FINLAND

EFFECT OF MUCOLYTIC PRETREATMENT ON GASTRIC MUCOSAL COATING WITH BARIUM SULFATE IN THE RAT

A scanning electron microscopic investigation

I LINDGREN T NEVALAINEN J MAKI and K O SODERSTROM

A good mucosal coating with barium sulfate is ssential in the double contrast examination of the stomach Why some commercial barium sulfate preparations adhere better to the gastric mucosa than do other is still poorly understood The process of adhesion depends on several physical factors such as simple electrostatic attraction of barium sulfate particles to the gastric mucosa and probably also direction binding between the particles and the mucosal wall (JAMES & GODDARD 1971) The best mucosal adhesion is obtained using crushed natural barium sulfate powders containing rough particles with jagged edges having a size from 0 5 to 30 μm (JAMES 1978) This represents a particular type of preparation (E–Z HD) which is now commercially available for double contrast examination Both the large variation of particle size and the additives used in this agent play a vital role being kept as a commercial secret by the manufacturer This preparation was found superior in scanning electron microscopic (LINDGREN unpublished data) and phantom experiments (GELFAND 1978 VIRKKUNEN et coll 1979) as well as in clinical series (KORMANO et coll 1978 JAMES)

In addition to the physical characteristics of the barium sulfate preparation the condition of the mucosal wall of the stomach plays an important role It is well known that good mucosal coating is not obtained in stomachs containing plenty of acid and mucus A too thick mucus covering the mucosa prevents the demonstration of normal areae gastricae (MACINTOSH & KREEL 1977) Hence it seemed pertinent to analyse the effect of pretreatment of the gastric mucosa by a mucolytic substance in order to obtain optimum conditions for the double contrast examination of the stomach For this purpose N acetyl L-cysteine was used which is an agent recommended for dissolving mucus in emphysema bronchitis tuberculosis and fibrocystic disease FOURNIER et coll (1977) have used this substance for cleaning the mucosa in examination of the colon N acetyl L-cysteine also reduces the intrinsic viscosity of gastric mucin mucoprotein solutions The maximum effect is obtained at pH 9 (SHEFFNER 1963)

Material and Methods

Adult Wistar rats of both sexes were used The rats were kept fasting for two days before they were decapitated The stomach with oesophagus and duodenum were prepared free and the infusion of the test solutions and the contrast medium was carried out through the oesophagus The following infusions were made 10 ml of 5 per cent sodium bicarbonate 10 ml of N acetyl L-cysteine (0 2 per 1 ml Mucomyst Bofors Nobel Pharma Sweden) and 10 ml of a commercial preparation of barium sulfate (50 per cent weight/weight E–Z HD E–Z EM Company USA) The following groups were formed each including at least 5 animals (1) barium sulfate only (2) pretreatment with N acetyl L-cysteine followed by barium sulfate (3) pretreatment with

Submitted for publication 8 May 1979




Fig 1 Rat stomachs exposed at 20 kV a) No application of barium sulfate b) After treatment with 5 per cent natrium bicarbonate c) After treatment with natrium bicarbonate a acetyl L-cysteine Optimum adherence of barium sulfate in

sodium bicarbonate followed by barium sulfate and (4) pretreatment both with sodium bicarbonate and N acetyl L-cysteine followed by barium sulfate The time of the pretreatment with sodium bicarbonate and N acetyl L-cysteine was 3 min After the infusion the stomach was gently rinsed with 0 9 per cent sodium chloride solution

After the test procedures the stomach was opened along the minor curvature and exposed at 20 kV on Agfa Mammoray film Specimens measuring about 5 mm × 10 mm were taken from the antral part of the glandular stomach for routine histologic preparations and for scanning electron microscopy The tissues for histology were fixed in 4 per cent for*maldehyde and dehydrated in an ethanol/xylene series* and embedded in paraffin The sections were stained with periodic acid Schiff and mucicarmine methods The samples for scanning electron microscopy were fixed in a 3 0 per cent glutaraldehyde in 0 1 M cacodylate buffer at pH 7 3 for 4 to 5 days washed in 5 per cent sucrose solution for 15 min and postfixed in 1 per cent osmium tetroxide in 0 1 M cacodylate buffer for 2 hours The samples were dehydrated in rising alcohol seires to 100 per cent ethanol Dehydrated specimens were dried in air and coated with an approximately 20 to 30 nm thick layer of gold in a vacuum evaporator and examined in a JSM U3 scanning electron microscope operated at 15 kV

Results

The radiography of the isolated stomach sho that good adherence of the barium sulfate prep tion to the mucosa was obtained after pretreatm with both 5 per cent sodium bicarbonate and mucolytic agent N acetyl L-cysteine (Fig 1) adhesion was also improved after pretreatment 5 per cent sodium bicarbonate only but was po preparations without pretreatment

The histologic examination of the untre stomachs of the fasted rats showed that there w 5 to 25 μm thick mucus layer on the antral muc In the stomachs treated with barium sulfate c the barium sulfate particles had become attac *to this mucus layer In the stomachs pretreated* with sodium bicarbonate and N acetyl L-cyst no mucus layer existed on the mucosa In stomachs additionally treated with barium sulf the contrast medium particles were in close co with the mucosa Scanning electron micros showed that all mucous membranes which were pretreated or pretreated with N acetyl L-cys alone had a thick layer of mucus on the surfa Most of the openings of the gastric pits and ma villi were covered by the mucus In the preparati additionally treated with barium sulfate the con medium was intermingled in the mucus (Fig the specimens treated both with sodium bicarbo

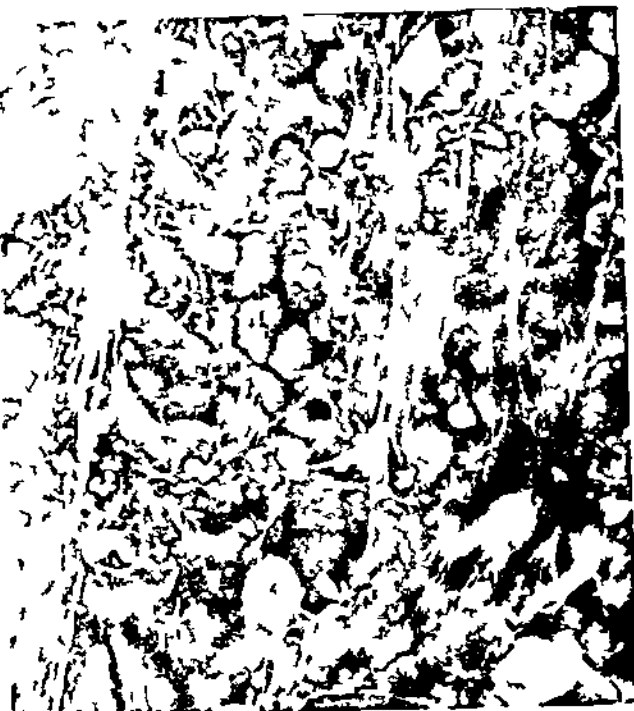


Fig 2



Fig 3




Fig 4

Fig 2 Surface of gastric mucosa after N acetyl L-cysteine treatment and barium sulfate application Openings of gastric pits and microvilli covered with mucus Barium sulfate particles adhere to mucus Scanning electron microscopy ×1 125

Fig 3 Surface of gastric mucosa treated with sodium bicarbonate and N-acetyl L-cysteine No barium sulfate application Mucus completely removed and gastric pits clearly visible Scanning electron microscopy ×1 125

Fig 4 Surface of gastric mucosa covered with barium sulfate after treatment with sodium bicarbonate and N acetyl L-cysteine Barium sulfate particles seen in close contact to epithelial cell surfaces and deep in gastric pits Scanning electron microscopy ×1 125

and N acetyl L cysteine little or no mucus was found on the surface of the mucosa (Fig 3) When these clean mucous membranes were treated with barium sulfate the contrast particles were found in close contact to the epithelial cell surfaces and deep in the gastric pits (Fig 4)

Comment

In the previous investigation (LINDGREN et coll 1978) of the adhesion properties of various commercial brands containing barium sulfate to the rat antral mucosa it was often found that the mucus covering the gastric surface inhibited the close contact of the

particles to the mucosa. This phenomenon could partly be inhibited by adding detergent substances to the contrast medium. However, a much more favourable effect was observed in the present experiments when the mucus was dissolved with a specific mucolytic agent, N-acetyl-L-cysteine. This effect of the agent only occurred after treatment with sodium bicarbonate because the maximum effect of N-acetyl-L-cysteine is obtained at pH 9 (SHEFFNER). Some cleaning effect on the stomach mucosa was observed also after 5 per cent sodium bicarbonate treatment alone. This might be due to the rinsing effect of the infusate as well as to the neutralisation of the mucosal surface. The inhibiting effect of overlying mucus to the adherence of contrast medium was previously demonstrated by MACINTOSH & KREEL in histologic sections.

MILLER & SKUCAS (1977) emphasized that the mechanism of mucosal coating with barium sulfate is similar to the surface coating obtained with paints. The present results show that when coating the gastric mucosa with contrast particles, the surface to be coated must be as clean as possible in order to obtain optimum adherence of the contrast medium. They also show that the removal of mucus from the gastric mucosa by the specific mucolytic agent N-acetyl-L-cysteine improves the quality of the double contrast examination. Although there are still a number of unknown factors, such as the possible unwanted effects of the mucolytic agent itself as well as the effect of removing the protective mucus layer from the gastric mucosa, the results suggest that this technique might be helpful in the clinical applications to the roentgenologic examination of the stomach.

SUMMARY

Freshly prepared isolated rat stomachs were used to examine the adherence of barium sulfate particles to the mucosal surface by scanning electron microscopy. The stomachs were pretreated with sodium bicarbonate a[...] or in connection with N-acetyl-L-cysteine and t[...] treated with barium sulfate specially designed for d[...] contrast examination of the stomach. The best adhe[...] of the contrast medium was obtained when the mu[...] was pretreated with both the alkaline and mucolytic a[...] indicating that, for the optimum adherence of the con[...] medium, the mucosal surface must be as clean as poss[...]

Request for reprints: Dr Ilmari Lindgren, Roen[...] Department, Narvik Sykehus, N-8501 Narvik, Norway.

REFERENCES

FOURNIER A. M., TIMON-DAVID P., JULIEN H., DEVAL[...] et MATTEI J. P.: L-acétyl-cystéine en mucograp[...] colique. J. Radiol. Electrol. 58 (1977), 479.

GELFAND D. W.: High density, low viscosity barium [...] fine mucosal detail on double-contrast upper gas[...] intestinal examinations. Amer. J. Roentgenol. [...] (1978), 831.

JAMES W. B.: The double contrast meal. New high den[...] barium sulphate powders. Brit. J. Radiol. 51 (19[...] 1020.

JAMES A. M. and GODDARD G. H. A.: A study of bari[...] sulphate preparations used as X-ray opaque med[...] Pharm. Acta helv. 46 (1971), 708.

KORMANO M., MÄKELÄ P. and ROSSI L.: Visualizati[...] of the area gastricae in a double contrast examinati[...] Dependence on the contrast medium. Fortschr. Rö[...] genstr. 128 (1978), 52.

LINDGREN I., SEVALAINEN T. and MÄKI J.: Scann[...] electron microscopy of the spreading of barium sulf[...] suspensions on the gastric mucosa of the rat. Effe[...] of wetting agents, bile salt and lecithine. Acta radi[...] Diagnosis 19 (1978), 361.

MACINTOSH C. E. and KREEL L.: Anatomy and radiol[...] of the areae gastricae. Gut 18 (1977), 855.

MILLER R. E. and SKUCAS J.: Radiographic contra[...] agents, p. 103. University Park Press, Baltimore 19[...]

SHEFFNER A. L.: The reduction in vitro in viscosity [...] mucoprotein solutions by new mucolytic age[...] N-acetyl-L-cysteine. Ann. N.Y. Acad. Sci. 106 (19[...] 298.

VIRKKUNEN P., SEURANEN H. and RETULAINEN V[...] Bariumsulfaattivarjoaineet kaksoiskontrastitutk[...] kimuksissa. (In Finnish.) Duodecim 95 (1979), 6.

ROM THE DEPARTMENTS OF DIAGNOSTIC RADIOLOGY AND PATHOLOGY UNIVERSITY HOSPITAL S-221 85
LUND SWEDEN

ELECTROLYTIC DESTRUCTION OF LUNG TISSUE IN THE RABBIT

L SAMUELSSON T OLIN and N O BERG

The investigation of electrolysis in biologic material goes back as far as 1809 and medical treatment by electrolysis was tried towards the end of the century (HORSLEY & CLARKE 1908) In modern medicine electrolysis has been used in neurosurgery and ophthalmology (THIRY et coll 1961 WILSON 1964) Tumour destruction by electrolysis was demonstrated in rats by SRINIVASAN et coll (1976) In the following year SAMUELSSON & OLIN (1977) reported on electrolysis in the rabbit lung and proposed electrolysis as a possible clinical method in the treatment of lung tumours Subsequently NORDENSTRÖM (1978) reported the first cases of electrophoretic ionization of lung metastases by a similar method

Material and Method

A direct current usually between 6 and 12 mA and 6 to 12 V from a constant current battery-operated apparatus was used The anode was the active electrode in most tests In the beginning round electrodes (4 mm) of stainless steel with thin isolated wires were used later copper and silver electrodes However most experiments have been carried out with platinum electrodes which were bullet shaped with a diameter of 3 mm and an area of 40 mm (Fig 1) A 700 mm² plate of stainless steel was used as the indifferent electrode

In all experiments were performed on 130 rabbits weighing between 1 5 and 3 0 kg General anaesthesia was obtained with intravenous pentobarbitone sodium A thin suction catheter was introduced into the pleural cavity The active electrode guided by a metal tube was then placed in the lung parenchyma through a small incision in the thoracic wall i e with a percutaneous technique The big cathode was located under the abdominal skin The position of the lung electrode was checked by fluoroscopy Post mortem the macroscopic appearance of all lungs was inspected and the size of the lesions was measured on the lung sections Microscopy of 50 lungs was performed

Dose response experiments were performed with a 3 mm platinum electrode in dose steps of 2 5 5 10 20 and 40 Coulomb (C) The shape of the lesion was elliptical and the volume was therefore calculated from the formula for the volume of a revoluted ellipse $V=4/3\times\pi\times a^2\times b$ where a is half the short diameter and b is half the long diameter If the dose was further increased the lesion usually extended to the visceral pleura and lacked symmetry *Three* animals were used at each dose level Analogous experiment was performed in the rabbit liver to assess the size of the electrolytic lesion in a denser organ The healing of the injuries was observed in animals surviving a 25 C lesion in the left lung for 0 4 8 32 or 64 days Four animals were included in each group Pulmonary angiography was performed in 14 rabbits in order to examine the pulmonary

Submitted for publication ?1 January 1980



Fig 1a



Fig 1b



Fig 2

Fig 1 Rabbit with a platinum electrode in the left lung The suction tube is indicated by arrows

Fig 2 Electrolytic lesions in a rabbit lung The anode hole is surrounded by a green to grey layer of tissue The rest of the lesion is black to brown in colour

vessels after electrolysis (doses 50 to 120 C) with copper and platinum electrodes

The temperature was measured close to the anode with a needle thermometer to evaluate the heat production of the anode Electrodes of steel silver copper and platinum were used in these experiments and for convenience they were implanted subcutaneously

Chlorine is liberated at the anode due to the oxidation of chloride ions Two tests were made to determine whether this very irritating gas leaked away from the lesion First the trachea was inspected macroscopically and in 6 cases microscopically as well Secondly in 5 rabbits the animal was connected to a respirator and the expired air was collected and analysed All air was passed through midget impinger bottles containing 3 3-dimethyl naphthidine in acetic acid Chlorine oxidizes this agent thereby giving it a red violet colour its intensity is proportional to the amount of chlorine absorbed The method can register chlorine concentrations from 0 1 ppm and upwards (H M Factory Inspectorate 1966)

Results

Electrolysis resulted in the destruction of tissue both at the anode and at the cathode The interest



ıg 3 Margin of lesion 24 hours after electrolysis with a dose of]C using a platinum electrode The lesion in the right part of the ıgure is delineated by a zone of tissue with alveolar oedema yperaemia and vascular thrombosis Haematoxylin-eosin ×65



Fig 4 Lesion 24 hours after electrolysis with a dose of 10 C and a platinum anode Periphery of lesion with part of the bronchus (upper right) and a large dilated artery (lower right) Bleeding in the peribronchial tissue and beginning desquamatation of bron chial cells Karyolysis in the alveolar walls within the lesion and thrombosis in a small artery and vein at the border to normal pulmonary tissue in the left part Haematoxylin eosin ×65

as focused upon the anodic lesions since the ones were only about half the size Lung sue immediately adjacent to the anode was totally disintegrated and had a grey colour Around this thin layer was a thicker layer of black to brown colour (Fig 2) The border to normal tissue was usually distinct Bronchi within the lesion were yellow brown in colour but this discolouration stopped ab ruptly at the border of the lesion After electrolysis with copper anodes the lesions were stained blue green due to the formation of copper compounds

Thrombi could be extracted from the larger ves sels within the lesions Practically no bleedings were observed neither during electrolysis nor afterwards Sometimes small haemorrhagic infarcts could be noted at the periphery of the anodic lesion In 2 cases with a central injury the whole lung became a haemorrhagic infarct Two weeks after electrolysis the lesions were fibrotic and pleural adhesions were often found

Cathodic injury to the lung was less extensive and the lesions had a black red colour The lesions around the stainless steel cathode which was placed subcutaneously were small and healed quickly The anodic lesion had a pH around 3 while the pH was about 10 at the cathode

At microscopy the lesions most resembled em bolic pulmonary infarcts Laminated eosinophilic masses occurred around the central laceration Karyolysis was already seen in the acute lesion especially in the bronchial and vessel walls To gether with a very marked tendency to thrombosis this differentiated the injury from a simple infarct (Fig 3) Widened vessels and smaller or larger fresh bleedings were almost always observed The early thrombi in the venous and smaller arterial vessels were soon followed by mural or occluding throm boses in the arteries After 24 hours marked karyolysis and eosinophilia were also observed in the alveolar walls (Fig 4) Marginal granulocytic



Fig 5 Twenty four hour old lesion Bronchial wall with desquamated bronchial epithelium and karyolysis in cartilage and muscle cells Haematoxylin eosin ×190



Fig 6 Twenty four hour old lesion The sharply delineate sion in the arterial wall is most distinct in the muscle layer endothelial cell of the lesion have pycnotic nuclei or have peared Slight subendothelial oedema in the vital tissue vessel Karyolysis is also apparent but less distinct in tissue Haematoxylin eosin ×190

invasion of the lung tissue and local hyperaemia were distinct In the bronchial walls the damaged epithelium was sloughed off and cartilage and muscle cells showed karyolysis (Fig 5) In many vessels at the border of the injury a sharply delineated karyolysis in the muscle layer was a striking finding (Fig 6) In one rabbit this was asssociated with aneurysmal widening and rupture of the vessel

After four days the karyolysis was total and a complete eosinophilic necrosis occurred in the lesion The central laceration was compressed and a proteinous exudate with varying numbers of erythrocytes filled the lesion and the alveoli At the periphery a distinct zone of demarcation was observed with invasion of fibroblasts macrophages and a few granulocytes Iron pigment was found in the macrophages After eight days organization of the injury was in progress Fibrosis in the subpleural region was rapid In the granulation tissue giant cells of foreign body type were found in great numb After four weeks the organization was complete a rather oedematous scar still persisted often wi relatively wide subpleural extension

Pulmonary angiography revealed a zone arou the anode where patent vessels were very spa and often irregular and distorted Even large vess exhibited distinct stenosis (Fig 7)

The dose response experiment showed that t lesion was proportional to the dose of the curre This was true both in the lung (Table 1 Fig 8) and the liver (Table 2 Fig 9) A dose of 20 C created lesion of about 500 mm³ a little more in the lung little less in the liver

The tests of various electrode metals showed th platinum was a splendid material whereas stee copper and silver had considerable drawback Stainless steel corroded heavily when used as a anode due to electrolytic corrosion i e the posit



Fig 7a



Fig 7b

Fig 7 Pulmonary angiography of the left lung after electrolytic lesion with platinum anode dose 110 C measuring 13 mm in diameter No vessels filled within the lesion A large branch of the pulmonary artery to the lower lobe moderately stenosed (→) in the lesion

metal ions moved from the anode to the cathode Copper corroded even more than stainless steel and the rabbits died when the dose was 100 C or more probably due to copper compound poisoning Silver was immediately attacked by chlorine and silver anodes were soon surrounded by silver chloride which isolated the electrode Platinum worked splendidly both as anode and as cathode material and no corrosion of the metal occurred

The temperature at the anodes made from various metals increased only slightly during electrolysis At the silver anode a current of 20 mA raised the temperature by 4 C while the corresponding increase at the platinum anode was only 1 5°C (Table 3) No irritation of the bronchi or trachea could be observed when watching surviving animals or on examination of these organs at autopsy Chlorine could not be detected in the expired air collected from rabbits during electrolysis although the doses given were as large as between 20 and 120 C and produced substantial lung lesions

Complications Pneumothorax was a very common complication About 10 per cent of the animals were lost after electrolysis as the animals did not accept pleural suction tubes when awake Rabbits have a weak mediastinum and may die following unilateral pneumothorax Infections seldom occurred No cardiac or neurologic complications were observed

Discussion

The current between electrodes is mostly transported by the most common ions sodium and chloride (DAVIES 1968) The chloride ions arriving at the anode will be oxidized to chlorine ($2 Cl^- \rightarrow Cl_2$) in addition water is electrolyzed and oxygen produced at the cathode hydrogen and sodium hydroxide (for details see SAMUELSSON & JONSSON 1980) Chlorine is a powerful oxidant and immediately attacks surrounding tissues Sodium hydroxide also destroys

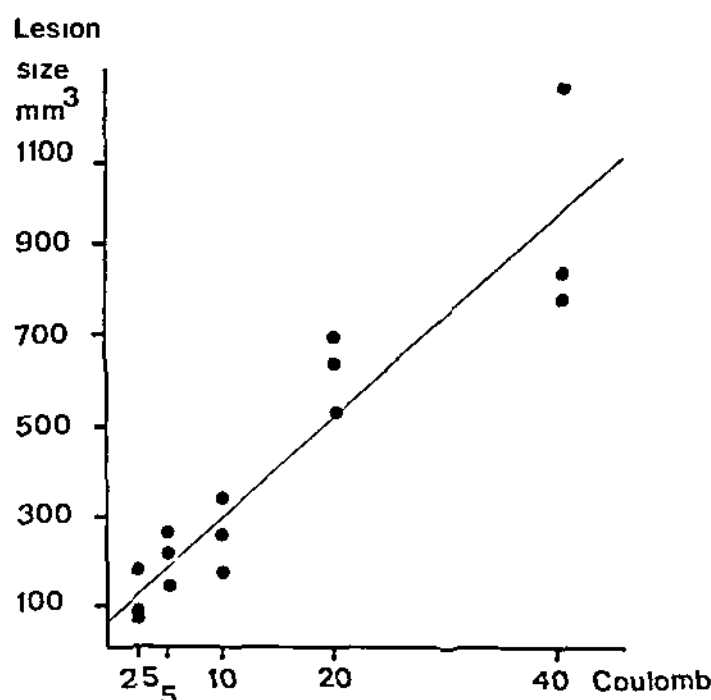


Fig 8 Lesion volume in the lung at different electrolytic doses Lesions were made with a platinum anode with a diameter of 3 mm Five dose steps were used $y = _\ 6x + 78$ $r = 0\ 94 \pm 0\ 03$

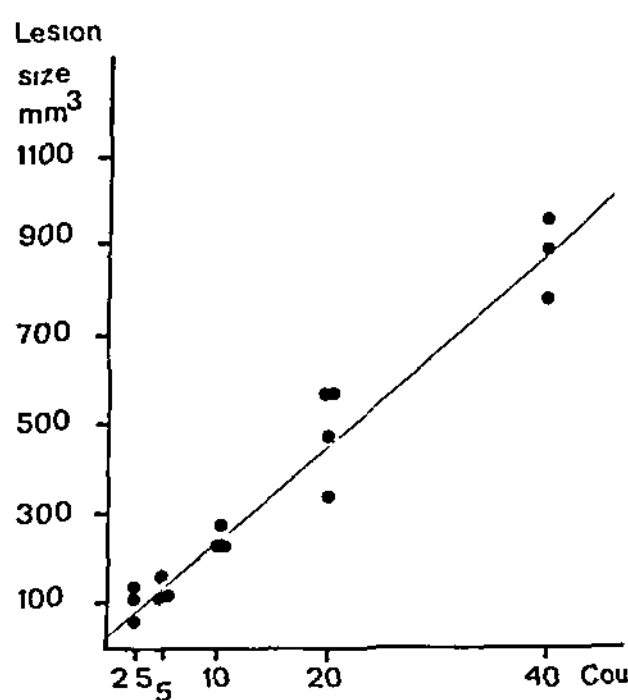


Fig 9 Lesion volume in the liver at different electrolytic do Compared with the size of the lesions in the lungs (Fig 8) lesions in the liver are smaller $y = 21\ 1x + 38\ 2$ $r = 0\ 98 \pm 0\ 01$

lung tissue but not so effectively as chlorine does The temperature recordings at the anode showed that heat had no part in the injury

In the medical literature concerning electrolysis and chlorine gas effects on the lungs and airways the effect of chlorine is explained in one of two ways Either it creates hydrochloric acid (DE REYMAEKER et coll 1953) or it reacts with wate release nascent oxygen which is a powerful pro plasmic poison (KRAMER 1967) However it is v known to chemists that chlorine attacks orga material directly and destroys it through powe oxidation In the process hydrochloric acid may produced When the chlorine level in the centre

Table 1

Lesion volume in the lung at various electrolytic doses

Dose (C)	Length (mm)	Width (mm)	Volume (mm³)
2.5	7	5	92
2.5	7	7	180
2.5	6	5	79
5	8	6	151
5	10	7	257
5	11	6	208
10	9	6	170
10	10	8	336
10	10	7	257
20	12	10	630
20	15	8	504
20	11	11	699
40	15	10	788
40	14	13	1 242
40	13	11	876

Table 2

Lesion volume in the liver at various electrolytic doses

Dose (C)	Length (mm)	Width (mm)	Volume (mm³)
2.5	7	4	59
2.5	7	6	132
2.5	6	6	113
5	8	6	151
5	8	5	105
5	8	5	105
10	11	7	283
10	9	7	232
10	9	7	232
20	14	8	470
20	13	7	334
20	13	9	55
40	14	11	889
40	18	10	945
40	15	10	788

Table 3

Temperature at the anode surface during electrolysis at various currents

Electrode metal	Current (mA)	Voltage (V)	Temperature (°C)	
			Subcutaneous	Rectal
Stainless steel	0	0	35 8	37 8
	5	?	35 9	
	10	3 5	36 0	
	0	5	36 5	
Silver	0	0	36 5	37 4
	10	4	37 3	
	20	10	40 3	
Copper	0	0	36 2	
	20	10	38 0	35 9
Platinum	0	0	37 1	
	20	10	38 6	36 7

an injury rises chlorine starts to diffuse into the surroundings The elliptic form of the resultant lesion can be attributed to the elongated form of the electrode and the spread of chlorine in the puncture canal The tissues in the discoloured area show a complete coagulation necrosis The profound effect of chlorine on the vascular system was demonstrated with pulmonary angiography which showed vascular stenoses

The dose response experiment showed a good correlation between the dose and volume of the injury It is interesting to note the small difference between the lesions produced in the lung and the liver the volume figures are somewhat approximated The most important measure is the short diameter of the lesion as the ultimate intention is to eliminate tumours with the method

Most vessels seemed to dilate under the influence of chlorine but no bleedings were observed during or after the experiments Only very small quantities of blood came from the suction tube at lung puncture The small bleedings observed microscopically in acute lesions are probably attributable to the actual puncture of the delicate lung structure with the 3 mm electrode The absence of severe bleeding complications was due to the formation of thrombi

However sometimes these thrombi gave small infarcts just outside the electrolytic lesions and in the 2 cases with a central injury thrombi in the central lung vessels caused haemorrhagic infarction of the entire lung The thrombogenic effect of electrolysis is evidently both a benefit and a risk no bleeding occurs during the procedure or afterwards but occasionally the lesion may become larger than intended The thrombogenic effect can be explained in several ways ADELSON & KAUFMAN (1971) and KAUFMAN & BURKONS (1971) observed thrombi in the lung vessels of victims of a chlorine gas accident and it is possible that this was a direct effect of chlorine THOMPSON et coll (1979) who used electrolysis as an experimental electrocoagulation method concluded that platelet attraction to the anode was the cause of coagulation The present microscopic examinations demonstrated a destruction of vessel walls that should be more than adequate to precipitate thrombus formation

Chlorine reacts very fast with organic material which means that there is no theoretical risk of chlorine slipping out into the vessels or bronchi around the lesion No signs of chlorine effect outside the injuries were found

Platinum proved to be an excellent electrode metal However platinum allergy is known and should be remembered Palladium can replace platinum (SAMUELSSON & JÖNSSON)

In conclusion chlorine locally liberated by electrolysis makes small well demarcated lesions in the lung tissue In the present experiments complications were within reasonable limits The results thus indicate that electrolysis is worth further investigation as a possible percutaneous method for the destruction of lung tumours

SUMMARY

Tissue destruction was produced by electrolysis after insertion of electrodes into the rabbit lung The anode was the active electrode and the best electrode material was platinum The lesions formed around the electrode were well demarcated and their size varied in relation to the charge applied Complications were few and the lesions healed quickly Tissue injury occurs as the result of chlorine liberation at the anode the basis for which is chloride ion oxidation

ACKNOWLEDGEMENTS

Supported by grants from Riksföreningen mot Cancer project No 1181 K78-01X and the Swedish Medical Research Council project Nos B79 14X-605 13A and B 80-14X-605 14B

REFERENCES

ADELSON L and KAUFMAN J Fatal chlorine poisoning Report of two cases with clinicopathologic correlation Amer J clin Path 56 (1971) 430

DAVIES C W Principles of electrolysis 2nd Edition The Chemical Society London 1968

DEREYMAEKER A THIRY S et THEEUWISSEN LESUISSE F Parametres physiques et biologiques des lesions cerebrales par electrolyse anodique Psychiat Neurol Neurochir (Amst) 66 (1963) 4

H M Factory Inspectorate Methods for detection of toxic substances in the air Booklet No 10 Chlorine London 1966

HORSLEY V and CLARKE R H Structure and function of the cerebellum examined by a new method Chapter IV—The electrolytic lesion Brain 31 (1908) 85

KAUFMAN J and BURKONS D Clinical roentgenologic and physiologic effects of acute chlorine exposure Arch environm Hlth 23 (1971) 29

KRAMER C G Chlorine J occup Med 9 (1967) 193

NORDENSTROM B Preliminary clinical trials of electrophoretic ionization in the treatment of malignant tumors IRCS Med Sci 6 (1978) 537

SAMUELSSON L and JONSSON L Electrolytic destruct of tissue Electrochemical aspects To be publish Acta radiol Diagnosis

— och OLIN T Electrolytisk destruktion av lungvavn (In Swedish) Hygiea 86 (1977) 345

SRINIVASAN S CAHEN G L JR and STONER G E El trochemistry in the biomedical sciences *In* El trochemistry The past thirty and the next thirty ye p 57 Edited by H Bloom and F Gutmann Plen Press New York London 1976

THIRY S FARINA M et MOUCHAMES R Communicat preliminaire sur l interet de la destruction par el trolyse de certains noyaux gris centraux dans le tra ment chirurgical de la maladie de Parkinson A neurol belg 61 (1961) 121

THOMPSON W MCALISTER D MILLER M PIZZO JACKSON D and JOHNSRUDE J Transcatheter el trocoagulation Experimental evaluation of the ano Invest Radiol 14 (1979) 41

WILSON W Iris cyst treated by electrolysis Brit Ophthal 48 (1964) 45

ROM THE DEPARTMENT OF DIAGNOSTIC RADIOLOGY (DIRECTOR PROF J GÖTHLIN) UNIVERSITY OF ERGEN MEDICAL SCHOOL AND THE DATA PROCESSING DEPARTMENT (DIRECTOR DIPL NHH E JOHANNESSEN) HAUKELAND SYKEHUS N 5016 BERGEN NORWAY

IDIOPATHIC HYPERTROPHIC SUBAORTIC STENOSIS

IV Diastolic relaxation and filling of the left ventricle analysed by geometric models

G KVAM and D RANGNES

The diastolic filling of the grossly hypertrophied left ventricle with its reduced systolic size has been reported as abnormal and restricted (STEWART et coll 1968 SANDERSON et coll 1977) and was regarded by GOODWIN (1974) as the most important pathophysiologic feature of idiopathic hypertrophic subaortic stenosis (IHSS)

The contraction of the left ventricle is abnormal reduced shortening is followed by nearly isometric contraction of the non septal wall except for the part at the valvar apparatus (Part III KVAM 1980) This is because a rather stiff interventricular septum most probably contracting isometrically (HUTCHINS & BULKLEY 1978) acts as a suspender for the rest of the ventricular wall (Part I B KVAM 1980)

It has been shown that the overall systolic fibre shortening of the contractile non septal left ventricular wall is markedly reduced but the amount of blood expelled per unit fibre shortening is increased (Part III) Conversely in diastole the left ventricular expansion (in ml) per unit myocardial fibre lengthening of the non septal wall is necessarily markedly increased relative to the normal left ventricle

In this report the diastolic filling and relaxation of IHSS and control left ventricles are analysed from cineangiographic frames of the left ventricle The same geometric models which were used for the analysis of the systolic period have also been applied in the present one

Material and Methods

The same sets of biplane cineangiographic frames in the 30 right anterior oblique (RAO) and in the 60° right posterior oblique (RPO) projections at 75 frames per second which were previously analysed through the systolic period (Part III) have been further analysed through the diastolic period

The 4 male patients (age range 24–64 years) with obstructive IHSS all had elevated left ventricular end diastolic pressures (resting values 16 28 29 and 31 mm Hg)

The 10 control patients (5 males 5 females age range 23–60 years) examined because of anginoid pain but with normal coronary angiography and with normal cineangiography had normal left ventricular end diastolic pressures (mean resting value 9 4 mm Hg range 7–13 SD 1 9 the one value of 13 mm Hg is considered as being in the upper normal range)

The cine films were viewed with a standard magnification and the enlargement factor was determined with a catheter grid technique (Part II KVAM 1980) The ECG was not recorded during the cardioangiography

An end systolic and a subsequent end diastolic frame were identified as the one with the smallest respectively the largest ventricular area before any dilatation or contraction could be noted The end

---

Submitted for publication 2 May 1979

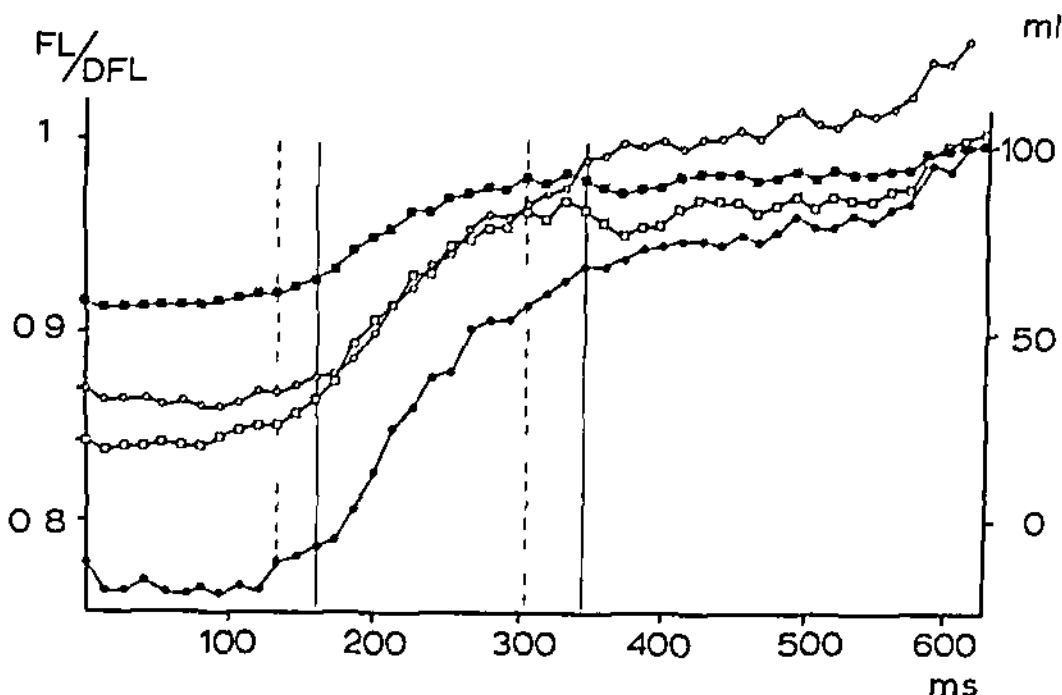


Fig 1 The myocardial fibre length as a fraction of the end diastolic fibre length (FL/DFL left hand scale) and the ventricular volume (right hand scale) for one of the IHSS patients and for one control patient with nearly equal length of the diastolic period ■ FL/DFL and □ ventricular volumes for the IHSS patient ● FL/DFL and O ventricular volumes for the control patient The rapid filling period lies between the thin vertical lines broken lines for the IHSS patient unbroken for the control patient

diastolic volume (LDV) was estimated from the biplane cine films using a previously described method for the IHSS left ventricular cavity (Part II)

For every diastolic frame from the end systolic to the end diastolic the 30° RAO left ventricular area and apico mid aortic lengths were measured and uniplane relative volumes calculated according to the *area length method Then the relevant volumes* were calculated for each frame For the IHSS group the end diastolic length width relationship K_t for the controls the length width relationship for every diastolic frame were calculated (Part II)

The left ventricular models for both the IHSS heart and the normal heart have been described at length previously (Part III) The same models are used for calculating the fibre length through the diastolic period The modifications are as follows In the IHSS model input values for FDV the end diastolic length width relationship K_t and the end diastolic left ventricular wall thickness t_{mt} were used as previously described *The intermediate diastolic left* ventricular volume V_{it} in the relevant phase of the diastole being analysed were used instead of the systolic volume The same applies to the control model but here the intermediate diastolic length width relationship K_{it} in the relevant phase of the diastole being analysed was used instead of the systolic length width relationship as well

In the previous report the systolic fibre lengt was calculated as the square root of the proportio between the volume weighted systolic and end dia tolic areas i e As/Ad In the present report th intermediate diastolic volume weighted area A_{it} calculated instead of the systolic area A The inter mediate diastolic myocardial fibre length as a frac *tion of the end diastolic fibre length FL/DFL* calculated as $\sqrt{Aid/Ad}$

The calculations were performed on a Nord 1 computer The programs have been described in Part III

In each patient the mitral valve opening wa taken as the frame when blood not containing con trast medium from the left atrium first appeared within the left ventricular cavity (SANDERSON e coll) This was taken as the end of the isovolumetric relaxation period and as the start of the rapid filling period

The end of rapid filling could nearly always be *identified as a discontinuity on the curves for ven* tricular volume and fibre length The mean rates of filling (ml per s) and of lengthening (end diastolic lengths (FDL) per s) were calculated for the rapid filling period The middle part of these curves fitted rectilinear regression well and the slope of these regression lines was taken as the peak rate of filling and lengthening respectively during the rapid fi

Table

Values for the two groups of patients presented as mean values ranges and standard deviations The heart rate the systolic ejection fraction (EF) the end diastolic volume (EDV) the diastolic and the isovolumetric relaxation periods for all patients The rapid filling period and the parameters referring to this period (mean and peak rates of filling—MRF and PRF respectively—and the mean and peak rates of lengthening—MRL and PRL respectively both in end diastolic lengths per second) apply for only 8 of the control patients

	IHSS patients	Control patients
Heart rate	8 (64–95 SD 13)	66 (55–80 SD 9)
EF	0 85 (0 82–0 88 SD 0 024)	0 71 (0 63–0 79 SD 0 054)
EDV ml	119 (103–130 SD 13)	158 (87–189 SD 30)
Diastolic period ms	413 (267–627 SD 154)	507 (753–677 SD 127)
Isovol relax per ms	133 (1 0–147 SD 11)	143 (1 0–160 SD 15)
Rapid filling per ms	90 (53–120 SD 78)	100 (67–1 0 SD 19)
MRF ml per s	635 (396–1 089 SD 309)	578 (359–755 SD 1 9)
PRF ml per s	709 (490–1 11 SD 347)	635 (440–931 SD 154)
MRL EDL per s	0 66 (0 43–1 22 SD 0 38)	1 08 (0 58–1 63 SD 0 34)
PRL EDL per s	0 73 (0 45–1 35 SD 0 47)	1 37 (0 78–2 06 SD 0 46)

ling period (3 or 4 points or an equal amount of additional points on either side if this yielded a steeper slope were used)

In 2 of the control patients the transition from the rapid filling period which was short was more gradual In these 2 patients the rapid filling parameters were not calculated because of absence of definition

Results

The curves for one of the IHSS patients and for one of the control patients with nearly equal length of the diastolic period appear in Fig 1 The periods of isovolumetric relaxation and rapid filling are shown The fibre lengthening is less marked in the IHSS patient and the slope of the fibre lengthening curve is not as steep

The heart rate the systolic ejection fraction EDV the length of the diastolic period and the length of the isovolumetric relaxation in the two groups of patients are summarized in the Table Higher EF and smaller EDV in the IHSS group has previously been described The somewhat larger EDV than previously reported for the IHSS patients is due to the fact that a different end diastolic frame was chosen for one of the patients the systolic frame leading to the previously determined diastolic frame was not well defined in this patient The difference may be explained by this frame appearing slightly later during the contrast medium injection

No difference was found between the length of the period of isovolumetric relaxation in the 2 groups

The length of the period of rapid filling the mean rates of filling and the fibre lengthening and the corresponding peak rates during this period for the

IHSS patients and for the 8 control patients also appear in the Table No difference was found between the length of the rapid filling period in the 2 groups nor any significant difference between the filling rates in the 2 groups However the mean and maximum rates of fibre lengthening are larger in the control group than in the IHSS group (Wilcoxon Mann Whitney rank sum test p<0 05)

The ventricular volumes and the average length of the myocardial fibres through the diastolic period for all the 4 IHSS patients and for 5 of the control patients are given in Fig 2 The 5 patients were chosen to give an average length of the diastolic period similar to that for the IHSS group (419 ms (SD 128) and 413 ms (SD 156) for the 5 controls and the 4 IHSS patients respectively) As expected the figure shows a reduced overall lengthening and also a reduced velocity of lengthening in the IHSS group The transitions between the different diastolic time intervals is somewhat obscured by this mode of presentation The periods of isovolumetric relaxation and rapid filling have approximately the same length in the individual patients but the length of the diastolic period is different Therefore the periods of isovolumetric relaxation and rapid filling get a more different length among the individual patients on this relative time scale

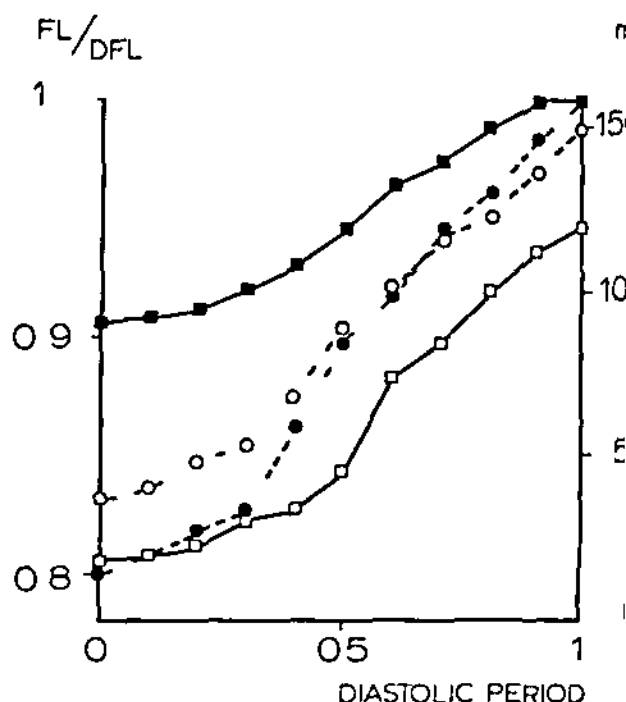


Fig 2 The myocardial fibre length as a fraction of the diastolic fibre length (FL/DFL left hand scale) and the left ventricular volume (right hand scale) along the diastolic period FL/DFL and □ ventricular volume for the IHSS patients FL/DFL and ○ ventricular volume for the control patients Average values for the four IHSS patients and for five of the control patients are shown The five controls were selected to have average length of the diastolic period as close to that of the IHSS group as possible

Discussion

The present results do not support the conclusion of SANDERSON et coll that the *isovolumetric relaxation period lasts longer in IHSS patients than in controls* Their 10 controls had a faster pulse frequency and a smaller EDV than the present controls but in the present controls no correlation was found between either of these parameters and the length of the isovolumetric relaxation period

The definition of the end of the isovolumetric relaxation was the frame when blood not containing contrast medium first was clearly seen within the ventricular cavity as described by SANDERSON et coll Very similar values for the length of the isovolumetric relaxation period in their group and the present IHSS group indicates that most likely a corresponding frame has been chosen

Immediately before the ventricular filling the mitral valves bulge into the ventricular cavity the next moment the values open up due to the blood stream At 75 frames per second these stages cover one or two frames On the next frame blood from the left atrium not containing contrast medium clearly present within the ventricular cavity t frame was considered to represent the end of insovolumetric relaxation

RUTLEY et coll (1974) chose the frame *immediately before the beginning of mitral valve opening* as the end of the isovolumetric relaxation which probably corresponds to the first frame described Their filming speed was 100 frames per second and in their patients with diseased and non diseased left ventricles the isovolumetric relaxation period ranged from 70 to 110 ms Using their definition the isovolumetric relaxation period among the present 10 control patients would range from less than 93 to less than 133 ms The isovolumetric relaxation period among the IHSS patients would be similarly differently registered The definition of the end systolic frame is a choice between two frames in some patients This difference between the values reported by RUTLEY et coll and the values for the isovolumetric relaxation period presented in the present report are regarded as methodologic and not real (they did not report the values for the con and for the pathologic left ventricles separately)

The 2 patients who were excluded because of a radual transition from a more rapid filling period also had a faster filling period initially but it was ard to know where on the curves the velocities of lling and fibre lengthening should be measured If maximum velocities are measured between the 4 oints on the steepest part of this early part of the curve and included in the statistics referred to the onclusions are not altered

The present investigation has not disclosed any hing which cannot reasonably be regarded as a con equence of the systolic situation That the overall ngthening is reduced in IHSS is secondary to the onfiguration of the left ventricle and the con equent contraction pattern (Part III)

The reduced velocity of fibre lengthening is sur rising when the curve of the end systolic IHSS on septal left ventricular wall is considered The verage radius of this curve is certainly not reduced to the same extent as the ventricular wall of the ormal heart if it be reduced at all According to the aPlace equation a smaller intracavitary pressure onsequently may be needed to expand the wall than rdinarily is the case but the wall is hypertrophic nd the stretching forces are therefore distributed hrough a thicker wall

The reduced velocity of lengthening may also be a onsequence of the late systolic isometric contrac ion of the free wall (Part III) The microstructural hanges effected by this isometric contraction (MA ION et coll 1974 WIGLE & SILVER 1978) may cause decreased distensibility of the myocardial wall

The reduced velocity of fibre lengthening may also be explained by the IHSS myocardial muscle ibres not shortening beyond their passive length luring the systolic contraction When skeletal mus le fibres are shortened below their slack length orces are exerted during relaxation to re extend the ibres toward their slack length (RAMSEY & STREET 1940 GORDON et coll 1966) A similar mechanism may explain the early rapid filling phase of the nor mal left ventricle (KATZ 1930) when the wall stiff ness is very low (GIBSON & BROWN 1974)

This possible mechanism may be illustrated as follows The normal left ventricle shortens about 19 per cent during the systolic contraction (Part III) Isometric stimulation of isolated cat papillary mus cle showed that the ascending limb of the developed tension curve extends from 70 to 100 per cent of an optimum length (Lmax) but resting tension was not measurable until muscle lengths of 85 per cent of Lmax were reached When stretched beyond Lmax the developed tension upon stimulation decreased (SONNENBLICK & SKELTON 1978) The normal heart increases its contractile force upon diastolic dilatation (Starling principle) This means that it works on the ascending limb of the length tension curve Assuming that these data are relevant for the metrically contracting heart an arithmetic example can be made If the diastolic fibre length in a normal ly contracting heart corresponds to 0 92 × Lmax then the systolic fibre length will be approximately 0 92 × (1–0 19) × Lmax=0 75 ×Lmax Correspond ingly the fibre length of the systolic IHSS non sep- tal left ventricular wall will be approximately 0 92×(1–0 10)×Lmax=0 83×Lmax as the non septal wall of the IHSS heart shortens approximately 10 per cent

In this context it is interesting that the one IHSS patient who had a faster although short lived peak velocity of fibre lengthening than the other three also had the most marked systolic fibre shortening of the four 11 4 per cent

Conclusion The overall fibre lengthening of the non septal left ventricular wall is reduced in IHSS when compared with the normal left ventricle a necessary consequence of the reduced systolic fibre shortening The mean and peak velocities of fibre lengthening during the early rapid filling period are reduced in IHSS while the mean and peak velocities of ventricular filling have been found normal No difference was found between the length of the isovolumetric relaxation period in the IHSS and the control groups

SUMMARY

The ventricular volumes and the myocardial fibre length have been analysed frame by frame from cine angiography of the left ventricle at 75 frames per second through the diastolic period in 4 patients with idiopathic hypertrophic subaortic stenosis (IHSS) and 10 control patients The fibre length was analysed by means of geometric models previously described (Part III KVAM 1980) The iso volumetric relaxation period lasted equally long and no difference was found between the rates of ventricular fil ling during the rapid filling period in the two groups The peak and mean rates of fibre lengthening were reduced during the early rapid filling period in IHSS

ACKNOWLEDGEMENTS

Professor Jan Gothlin gave valuable support during the entire investigation and Dr Lars Morkrid kindly

formed the statistical evaluation The Dept of Clinical Physiology Haukeland University Hospital supplied materials and the drawings were made by Mrs G S Johansen

REFERENCES

GIBSON D G and BROWN D J Relation between diastolic left ventricular wall stress and strain in man Brit Heart J 36 (1974) 1066

GOODWIN J F Prospects and predictions for the cardiomyopathies Circulation 50 (1974) 210

GORDON A M HUXLEY A F and JULIAN F G Variation in isometric tension with sarcomere length in vertebrate muscle fibres J Physiol (Lond) 184 (1966) 170

HUTCHINS G M and BULKLEY B H Catenoid shape of the interventricular septum Possible cause of idiopathic hypertrophic subaortic stenosis Circulation 58 (1978) 392

KATZ L N The role played by the ventricular relaxation process in filling the ventricle Amer J Physiol 95 (1930) 542

KVAM G Idiopathic hypertrophic subaortic stenosis I Interventricular septum during the systolic contraction A The shortening of the muscular interventricular septum B Analysis of the protruding non bending muscular interventricular septum Acta radiol Diagnosis 21 (1980) 53

— Idiopathic hypertrophic subaortic stenosis II The shallow left ventricular cavity Acta radiol Diagnosis 21 (1980) 165

— Idiopathic hypertrophic subaortic stenosis [illegible] Analysis of the myocardial fibre shortening of the f[illegible] left ventricular wall by means of geometric mode[illegible] Acta radiol Diagnosis 21 (1980) 357

MARON B J FERRANS V J HENRY W L CLARK C [illegible] REDWOOD D R ROBERTS W C MORROW A G a[illegible] EPSTEIN S E Difference in distribution of myocar[illegible] abnormalities in patients with obstructive and n[illegible] obstructive asymmetric septal hypertrophy (AS[illegible] Light and electron microscopic findings Circulation [illegible] (1974) 436

RAMSEY R W and STREET S F Isometric length tens[illegible] diagram of isolated skeletal muscle fibres of the fro[illegible] cell comp Physiol 15 (1940) 11

RUTLEY M S ADAMS D F COHN P F and ABRAMS [illegible] L Shape and volume changes during isovolume[illegible] relaxation in normal and asynergic ventricles Circu[illegible] tion 50 (1974) 306

SANDERSON J E GIBSON D G BROWN D J and GO[illegible] WIN J F Left ventricular filling in hypertrophic c[illegible] diomyopathy An angiographic study Brit Heart J [illegible] (1977) 661

SONNENBLICK E H and SKELTON C L Reconsiderat[illegible] of the ultrastructural basis of cardiac length tens[illegible] relations Circulat Res 58 (1978) 398

STEWART S MASON D T and BRAUNWALD E Impa[illegible] rate of left ventricular filling in idiopathic hypertro[illegible] subaortic stenosis and valvular aortic stenosis Circ[illegible] tion 37 (1968) 8

WIGLE E D and SILVER M D Myocardial fibre disa[illegible] and ventricular septal hypertrophy in asymmetr[illegible] hypertrophy of the heart Circulation 58 (1978) 398

FROM THE DEPARTMENTS OF DIAGNOSTIC RADIOLOGY AND INFECTIOUS DISEASES AKADEMISKA SJUKHUSET S 750 14 UPPSALA SWEDEN

HEART VOLUME DETERMINATION

A methodologic analysis

U ERIKSON G FRIMAN and G WEGENIUS

Roentgenographic determination of the volume of the heart is a routine procedure in Sweden It has its principal value in the diagnosis of heart diseases and during the course of their treatment but it is also used for assessment in cases of hypertension and in preoperative evaluation

The methods most frequently employed in Sweden are those developed by JONSELL (1939) and KJELLBERG et coll (1951) A modified technique for heart volume determination was described by BERGSTRÖM & ERIKSON (1965) It has been used for some time in clinical practice and this report constitutes an evaluation of the reproducibility of the method

Material

Twenty men (17–38 years of age) being treated for different infectious diseases were chosen None of them had signs or a history of heart disease and on the day of the roentgen examination they were afebrile and were up and about All had a normal ECG

Method

The examination was performed with the subject in the supine horizontal position with the arms raised (BERGSTRÖM et coll 1969) The central rays of the respective roentgen tubes were perpendicular to one another and directed at right angles to the longitudinal axis of the body (Figs 1 2) FFD (f) was 125 cm Oesophageal contrast medium was given and the subject was asked to breathe lightly during the exposures A p and lateral films were exposed simultaneously but no ECG synchronization was used

Each subject was examined on 2 occasions (A and B) on the same day one in the morning and the other in the afternoon with a time interval varying between 3 and 5 hours On the films obtained the 3 diameters (a b and c) required by the ellipsoid formula were obtained (Fig 3) The position of the mid point of the heart was estimated on the films and the distance from this point to the respective film planes (V_L and V_F Fig 3) measured From these measurements the magnification factor was determined individually for each projection The heart volume was then calculated from the formula

$$V=\frac{\pi}{6}\times a\times b\times c\times\frac{(f-V_L)\,(f-V_{FY})}{f^3}$$

Each determination was made separately and without access to the results of other determinations

In order to assess the reproducibility of the method all measurements were made on all films from examinations A and B by one and the same examiner (G W) Thereafter for assessing the variation of the results obtained by one examiner the calculations from examination A were repeated

Submitted for publication 13 December 1978

Table 1

Heart volumes (ml) in 20 patients determined by one and the same examiner (G W) from films exposed on 2 occasions (A and B) on the same day Δx = p<0 05 Coefficient of correlation 0 936

	Mean	Standard deviation
A	840	148
B	876	177

Table 2

Heart volume determinations (ml) in 18 patients obtained by one and the same examiner (G W) at repeated calculations (1 and 2) from the same film (examination A) Δx not significant Coefficient of correlation 0 968

	Mean	Standard deviation
1	838	142
2	844	156

Table 3

Heart volume determinations (ml) in 18 patients obtained by 2 independent examiners (U E and G W) at calculations on the same film (examination B) Δx p<0 01 Coefficient of correlation 0 980

	Mean	Standard deviation
U E	814	141
G W	844	156

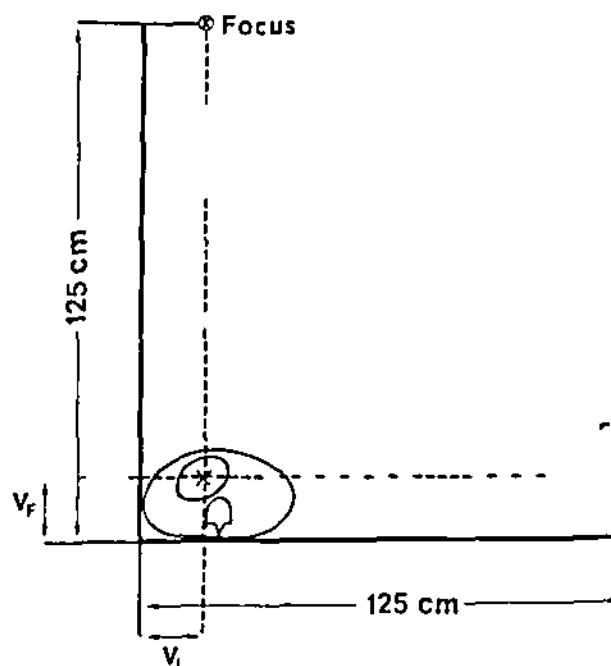


Fig 1 Examination technique Patient in supine position 125 cm V_F and V_L distances to respective film planes from c (x) of heart

Table 4


Comparison of each individual measurement value as determ by 2 independent examiners (U E and G W) in 18 patien

		Mean	Standard dervation	Coefficie of variati (per cent)
V_F	(U E)	30 60	1 050	3 4
V_F	(G W)	30 18	1 055	3 5
V_L	(U E)	24 76	2 150	8 7
V_L	(G W)	24 37	2 010	8 3
a	(U E)	18 517	1 412	7 6
a	(G W)	18 467	1 480	8 0
b	(U E)	14 622	0 978	6 7
b	(G W)	14 572	0 980	6 7
c	(U E)	12 500	1 241	9 9
c	(G W)	12 856	1 346	10 4

(G W) Finally to estimate the variation between the results of different examiners the calculations from examination B were repeated by examiner U E Both the heart volumes obtained and the values for the individual variables included in the calculations were then analysed statistically by standard methods For statistical significance a difference on the 5 per cent level was required

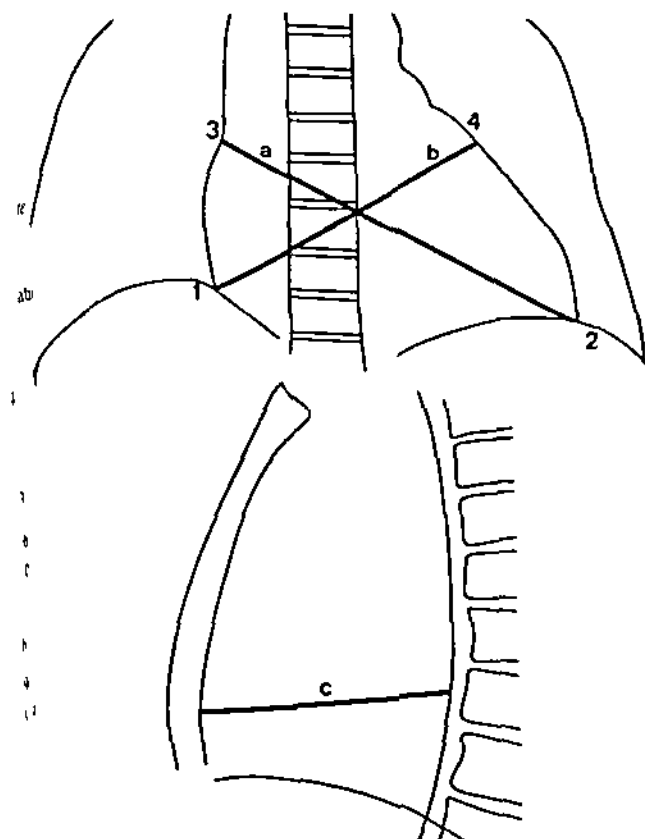
Results

The results are presented in Tables 1 to 4 Lar heart volumes were systematically obtained in th afternoons than in the mornings This difference statistically significant (0 05<p<0 01) but numerically small No difference was found betwe repeated determinations from the same films by and the same examiner However a small (30





ıg 2 Examples of a p and lateral projections with the rulers oınts 1 to 4 are explained ın Fıg 3 The dıstance between the centre of the heart (x) and the lateral film ıs measured on the ruler exposed on the a p film and ıts dıstance to the a p film ıs measured on the lateral film



ıg 3 Measurement poınts used ın calculatıng the dıameters 1) The poınt at which the rıght contour of the heart ıntersects the dıaphragm) The poınt at which the left contour of the heart ıntersects the diaphragm 3) The point at which the rıght contour of the heart meets the contour of the superıor vena cava 4) A point on the left contour of the heart which lies on the same horizontal level as point 3 Dıameter a = the dıstance from 2–3 Dıameter b = the distance from 1–4 Dıameter c = the distance between the anterıor surface of the heart as a rule the posterior aspect of the sternum and the posterıor surface of the heart which ıs generally delımıted by the contrast filled oesophagus

but statıstıcally sıgnıficant dıfference was noted between ındependent examıners ın theır results from the same films The dıameter c was larger when measured by G W and V_L and V_F were larger when measured by U E

Dıscussıon

A small and possıbly real dıfference ın the heart volume was observed between the mornıng and afternoon examınatıons As the heart volume ıs correlated to the blood and plasma volume (KJELLBERG et coll 1949) an ıncrease of the latter durıng the day mıght explaın thıs findıng That dıurnal varıatıons ın plasma volume occur ıs well documented (JOHNSON et coll 1971) Good reproducıbılıty was found when one examıner repeated a determınatıon and the dıfference between the results of two examıners was small wıth a systematıc tendency for G W to arrıve at somewhat larger volumes the U E The result ındıcates that ıt ıs slıghtly more dıfficult to measure dıameter c and to estımate the posıtıon of the centre of the heart than to determıne the dıameters a and b Thıs may explaın the mınor dıfferences observed between the two examıners

In conclusıon the method showed good reproducıbılıty No further refinement wıth the aım of ımprovıng the precısıon would seem realıstıc (SPERBER 1978) The method ıs sımple and should be suıtable as a standard clınıcal procedure

SUMMARY

A method already in clinical use of determining the total volume of the heart in patients in the supine position was evaluated The reproducibility in the measurement of individual diameters and distances was good A minor difference was noted between the results of 2 different examiners A discrepancy in the total heart volume of 30 ml or more between 2 determinations was statistically significant which may be a guide in the assessment of volume determinations in clinical practice

REFERENCES

BERGSTROM K and ERIKSON U A study of formulae and methods for determination of the heart volume Acta Soc Med upsalien 70 (1965) 279

— — and GUSTAVSSON B Roentgenological determination of the heart volume The influence of projection and body position Acta Soc Med upsalie (1969) 81

JOHNSON P C DRISCOLL T B and CARPENTER W Vascular and extravascular fluid changes during of bed rest Aerospace Med 42 (1971) 875

JONSELL S A method for determination of the hear by teleroentgenography (a heart volume index) radiol 20 (1939) 325

KJELLBERG S R LÖNROTH H and RUDHE U The of various factors on the roentgenological d mination of the cardiac volume Acta radiol 35 (1 413

— RUDHE U and SJÖSTRAND T The relation of ca volume to the weight and surface area of the body blood volume and the physical capacity for work radiol 31 (1949) 113

SPERBER G O The inherent mathematical error fact radiological determination of heart volume Up med Sci 83 (1978) 89

ROM THE DEPARTMENTS OF DIAGNOSTIC RADIOLOGY UNIVERSITY HOSPITAL IN LUND AND MALMO AND THE DEPARTMENT OF UROLOGY UNIVERSITY HOSPITAL IN LUND S 22185 LUND SWEDEN

QUANTITATIVE FLOW ESTIMATIONS OF ARTERIOVENOUS FISTULAS WITH DOPPLER AND DYE DILUTION TECHNIQUES

I FORSBERG U TYLEN T OLIN and E LINDSTEDT

Arteriovenous fistulas performed according to 3RESCIA et coll (1966) have become more common y used during recent years The arterialized veins ire used for haemodialysis but also for administra ion of cytostatics and for parenteral nutrition Therapeutic arteriovenous fistulas must have a cer ain flow in order to give adequate function The nost common surgical technique at this hospital is he side to side anastomosis between the radial ar ery and the cephalic vein but other vessels or types of anastomoses may be used (LINDSTEDT 1972 LINDSTEDT & LINDHOLM 1979) Most patients ob ain adequate fistula flow but when the flow is too arge cardiac failure may arise and when too low he fistula may be useless Angiography may then be used for evaluation of the morphology of the fistula GOTHLIN & LINDSTEDT 1975) Quantitative estima tion of the flow is of special interest but the flow measurements are reported to be difficult to perform GOTHLIN et coll 1977) Access to a non invasive technique for quantifying fistula flow would be of great value Doppler technique has been used to prove patency of the fistula (STEPHENSON & LICHTI 1971) and to some degree quantify the flow by com paring the flow velocity in the normal brachial artery with that of the brachial artery feeding the fistula KEITZER & LICHTI 1975)

Material and Methods

Fourteen patients all males with arteriovenous istulas in the forearm were examined with brachial angiography All of the patients had radiocephalic fistulas 13 with anastomosis side to side one end to end Five of the patients had uraemia 5 carcino ma of the bladder 2 malignant teratoma of the tes ticle one Crohn s disease and one Hodgkin s dis ease In all cases brachial angiography was carried out with flow measurements using a dye dilution technique and flow rate estimation using a Doppler equipment

Catheterization of the brachial artery was per formed from the groin The tip of the catheter was placed distal to the origin of the axillary arteries A ruler was fixed to the arm in the area of the ar teriovenous fistula at a level from the film corres ponding to that of the fistula The ruler was simul taneously exposed on the films

The subclavian vein was thereafter catheterized also from the groin and the tip of the catheter having two side holes was placed distal to the in flow of the jugular veins but proximal to the entry of the cephalic vein

Flow determination was carried out by injection of a bolus of indocyanine green (Cardio Green Hyn son Westcott and Dunning Inc USA) through the catheter in the brachial artery while venous blood was continuously sampled at a rate of 0 5 ml/s by a motor driven pump The venous blood passed a spectrophotometer its signal was recorded on a potentiometer recorder Calibration of the method

Submitted for publication 24 September 1979



Fig 1 Doppler flow velocity curve with a calibration signal The mean velocity is calculated from the distance between the dotted line and the base line



Fig 2 Ultrasound of the brachial artery just above the e[...] where the Doppler recordings were received

was made afterwards by mixing 0 1 ml of the dye solution with 10 ml venous blood and letting the mixture pass through the spectrophotometer Blood flow was calculated according to a modified Stewart Hamilton formula (LINGÅRDH et coll 1969) The integration of the curve was made by copying it on hard paper after extrapolation to the base line after which it was cut out and weighed

The flow was calculated thus

$$Q=(q \times D \times M_{100} \times 60)/M \text{ ml/min}$$

where

- Q =blood flow
- q =injected amount of dye (ml)
- D =deflection on the potentiometer recorder at calibration
- M =weight of the cut out curve
- M_{100}=weight of 100 square units of the same paper as the cut out curve

At the same time flow velocity measurements were performed with a 10 MHz directional Doppler (Parks 806) with calibration facilities

The Doppler equation used for quantitative flow measurements is given in the previous report (FORSBERG & OLIN 1980) and is summarized as follows

$$v=(\Delta F \times c)/2F_e \cos \alpha$$

- ΔF=Doppler frequency (kHz)
- F_e =emitted frequency (kHz)
- c =velocity of ultrasound in blood 1 56×10⁵ (cm/s)
- v =velocity of flow (cm/s)
- α =angle between probe and blood vessel

Before each examination the Doppler equipment was calibrated against a 1 000 Hz generator to make quantitative measurements possible

The flow velocity measurements were perfo[...] with a pencil probe fixed in 45 angle by a pl[...] holder (Fig 2 in FORSBERG & OLIN) in order t[...] comparable geometry at different examinations [...] feeding artery i e the brachial artery [...] examined just above the elbow where the a[...] runs parallel to the skin The highest veloci[...] registered when the probe is directed along the [...]sel over its center

At this level Doppler examination gives a [...] velocity curve with regular variations due to sy[...] and diastole This curve is located above the [...] line indicating a continuous flow of different [...]nitude (Fig 1) The mean distance from the base[...] is measured and the mean velocity is calculated [...]ing the formula previously presented Then m[...]plication with the cross sectional area of the ve[...] is performed giving the volume flow The cross [...]tional area of the brachial artery was calculated f[...] the diameter measurements at angiography with [...]duction for magnification and in the last 5 pati[...] also from B scan ultrasound (Fig 2)

Results

The calculated flows from Doppler and dye-d[...]tion methods appear in Fig 3 The two meth[...] correlated well regression coefficient being 0[...] However the Doppler method gives somewhat h[...]er values than the dye dilution method The diff[...]ences between the two methods are more acc[...]tuated at high flows and flow velocities

Discussion

The dye dilution technique is well established a[...] was used for flow measurements of arteriovenou[...] fistulas by GÖTHLIN et coll The fistula flow valu[...]

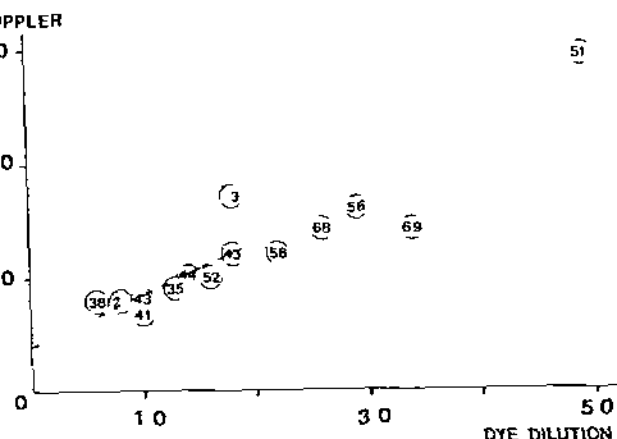


Fig 3 Good correlation found between flow measurements (l/min) with dye-dilution technique and with Doppler (r=0 91) Doppler measurements gave lower flow rates than did the dye-dilution

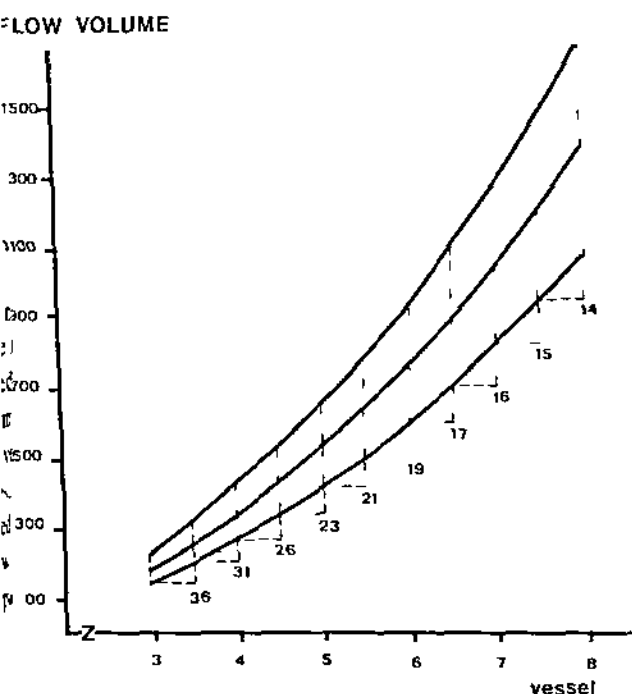


Fig 4 Effect of over or underestimation of the diameter (mm) of the examined vessel (in per cent) holding flow velocities (ml/min) normally found in patients with arteriovenous fistulas Upper curve 55 cm/s Middle curve 45 cm/s Lower curve 35 cm/s

measured were surprisingly high mean 1590 ml/min The flow values were also considerably higher than was estimated from the differences in cardiac output measured with open and closed fistula by these and other authors (for references see LINDSTEDT) The higher values received by the direct dye dilution technique could possibly be due to admixture of uncoloured blood from the shoulder region or to mixture of radial and ulnar blood flow which might distort the values more than was previously anticipated

Doppler measurements with 10 MHz might theoretically underestimate flow velocity in the range of 20 per cent at some of the higher flow velocities examined (FORSBERG & OLIN) The brachial artery just above the elbow is to be considered a superficial vessel and therefore the attenuation of ultrasound in the interposed tissue is probably of minor importance except for patients with very thick skin

The artery runs parallel to the skin in this area why the probe holder of 45 should give accurate readings Measurements performed near the fistula were difficult to evaluate due to the marked turbulence in this region The brachial veins running parallel to the brachial artery can occasionally disturb Doppler measurements over the brachial artery but in most cases it is possible to separate the vessels completely The directional Doppler equipment used could separate flow towards and away from the probe and flow velocity measurements were not considered accurate if flow could be registered in both directions

The cross sectional area of the vessel must be known when calculating the volume flow from Doppler determination of flow velocity The influence of diameter variations on the calculation of volumetric flow is shown in Fig 4 The diameter of the brachial artery in the present patients varied from 6 to 11 mm In this range the error due to under or over estimation of the diameter of the brachial artery in the range of 0 5 mm is between 10 and 20 per cent In 5 patients the difference between angiographically measured vessel diameter and measurements performed with B scan ultrasound was even less maximum 0 3 mm

A good correlation (r=0 91) was found between the 2 methods of flow measurement indicating some kind of constant error in one or both methods One of the 14 patients was examined with an electromagnetic flowmeter at operation for reducing the flow through the fistula The dye-dilution measurements gave 4 9 l/min Doppler 2 9 l/min and electromagnetic flowmeter 2 5 l/min This would indicate that the Doppler method in this case was more accurate Further experience is warranted to decide the accuracy of fistula flow determinations

Both dye dilution technique and electromagnetic flow measurements are invasive methods and imply a certain risk for the patient and his vessels Doppler measurement of the flow in the feeding artery of the

fistula combined with ultrasound B scan diameter measurement gives a totally non invasive rapid simple and cheap method of determining the flow in arteriovenous fistulas in the arm This might be of importance in a large group of patients Repeated examinations are possible which could add increased knowledge of the special haemodynamic situation caused by an arteriovenous fistula

SUMMARY

The flow in operatively created arteriovenous fistulas of 14 patients was calculated with Doppler and dye dilution techniques Good correlation was found between the 2 methods Differences in the results and future examination techniques are discussed

REFERENCES

BRESCIA M J CIMINO J E APPEL K and HURWICH B J Chronic hemodialysis using venipuncture and surgically created arteriovenous fistula New Engl J M 275 (1966) 1089

FORSBERG L and OLIN T Effect of interposed skin Doppler flow estimation at 5 and 10 MHz With description of a calibration device Acta radiol Di nosis 21 (1980) 203

GÖTHLIN J and LINDSTEDT E Angiographic features Cimino Brescia fistulas Amer J Roentgenol (1975) 582

— — OLIN T A dye dilution method for the determi tion of blood in Cimino Brescia fistulae Invest U 15 (1977) 167

KEITZER W F and LICHTI E L Applications of Doppler Common and unusual situations Angiol 26 (1975) 172

LINDSTEDT E Studies in therapeutic arteriovenous tulae Scand J Urol Nephrol (1972) Suppl No 1

— *und LINDHOLM T Die Gefassanschlusse bei Dialy* patienten Zbl Chir 104 (1979) 427

LINGÅRDH G MUTH T and OLIN T Renal blood f in dogs studied by means of a dye dilution techniq Scand J Urol Nephrol 3 (1969) 281

STEPHENSON H E JR and LICHTI E L The Dop ultrasonic flowmeter in the management of the dial arteriovenous fistula Arch Surg 103 (1971) 774

FROM THE DEPARTMENT OF DIAGNOSTIC RADIOLOGY (DIRECTOR PROF U RUDHE) HUDDINGE SJUKHUS
S 141 86 HUDDINGE SWEDEN

BLOOD FLOW INTO VASCULAR CATHETERS OF DIFFERENT SIZE AND NUMBER OF SIDEHOLES

Model experiments with flush fluid injections

M DAHLBORN and S SUNDELIUS

Intermittent flushing of intra arterial catheters is generally used to avoid formation of blood clots from inflow of blood into the catheters which involves a risk of thromboembolism (JACOBSSON & SCHLOSSMAN 1969 SCHLOSSMAN 1973 HAWKINS & HERBERT 1974) Previously (DAHLBORN et coll 1978) it was demonstrated that the rate of escape of contrast medium deposited in the catheter is dependent on several factors One of these is any deviation of the catheter from the horizontal level thus the medium leaks out more rapidly when the catheter is directed downwards than when it is directed upwards Conversely isotonic saline solution was found to leak out more rapidly when the catheter was directed upwards These results are supposed to depend on differences in densities of the fluids and blood The present investigation was performed in order to evaluate the significance in these respects of the size of the catheters and the presence of sideholes

Method

A blood circulation model was used as described previously (DAHLBORN & SÖDERLUND 1979) A transparent tube of plastic material was connected in the horizontal plane to the circulation system One or two transparent polyethylene catheters were glued onto the interior surface of the tube All catheters were painted white on their outer surface in order to obtain a suitable background for visual recording of the blood inflow into the catheter with the aid of a millimeter scale The catheters had an inner diameter of 1 15 mm and 1 6 mm respectively Catheters with sideholes were used in 128 of a total of 188 experiments The effect of multiple sideholes was evaluated in 64 experiments using catheters with four sideholes located on the distal 4 cm of the catheters and in another 64 experiments with a single sidehole bored 1 and 4 cm respectively from the catheter tip The effect of a single sidehole was evaluated using small lumen catheters only (ID 1 15 mm) while the remainder of the experiments were performed with both large and small lumen catheters (Table) The rate of blood inflow into the catheters was recorded in all experiments after a single injection of the flush fluid Isopaque Cerebral Nyegaard (meglumine/calcium metrizoate 280 mg I/ml) or isotonic saline solution The length (L) of the column of blood in the catheter was registered 0 15 30 s and 1 1½ 2 3 4 and 5 min following the catheter tap closure at the termination of injection In the experiments with catheters with a single sidehole the time was determined from catheter tap closure until the appearance of a continuous blood layer between the endhole and sidehole The catheters were directed 5 upwards and downwards upstream and downstream Human ACD blood was used (900 ml blood including 135 ml ACD solution formula A US Pharmacopeia) *Pulsative flow* was used The blood pressure varied between 270/20 and 170/10 mm Hg and blood flow between 540

Submitted for publication 20 December 1979

Table

Number of experiments

Inner diameter of catheter	Isotonic saline solution	Isopaque Cerebral	Total
1 15 mm without sidehole	14	14	28
1 6 mm without sidehole	16	16	32
1 15 mm with 4 sideholes	16	16	32
1 6 mm with 4 sideholes	16	16	32
1 15 mm with one sidehole 1 cm from tip	16	16	32
1 15 mm with one sidehole 4 cm from tip	16	16	32
Total	94	94	188

and 880 ml/min the pulse rate varied between 36 and 52 beats/min in the different experiments and the temperature of the blood was on a physiologic level all parameters being kept constant during each experiment Repeated experiments during varying physiologic conditions were performed to test the accuracy of the results No systematic errors were noted The viscosity of the contrast medium and saline solution was 4 0 cP and 0 71 cP respectively at 37 C

Results

At the termination of injection the catheter lumen was completely filled with the flush fluid A few seconds later the flush fluid in the catheter tip invariably became partially replaced by blood which formed a layer below the isotonic saline solution alternatively above the contrast medium The entrance of blood was continual Similar to what was noted previously (DAHLBORN & SÖDERLUND) no difference in inflow into the catheters was recorded between upstream or downstream directions Thus the length of the blood column and hence the rate of inflow was independent of the direction of blood flow relative to the catheters Therefore all values of inflow were included in the graphs in Figs 1 to 4 without account to the direction of the blood flow With Isopaque Cerebral as flush fluid in the experiments with catheters without sideholes a lower rate of blood inflow was recorded when the catheter was inclined upwards than downwards The average length of the blood inflow into the small lumen catheters at one min was 7 mm and 33 mm respectively (Fig 1 a b) the corresponding figures us the large lumen catheters were 12 mm and 68 (Fig 1 c d) With isotonic saline solution ra inflow of blood occurred when the catheter directed upwards compared with downwards corresponding average length of the blood colum the small catheters was 17 mm and 9 mm and 44 and 13 mm in the large catheters (Fig 2) The dif ences in rate and extent of inflow between upw and downward catheter directions were obvious statistical analysis was deemed unnecessary H ever no difference in these respects was noted w catheters irrespective of size containing cont medium and directed upwards were compared w those directed downwards and containing saline ution (Figs 1 a c 2 b d) Flush fluids in cathet with four sideholes almost instantly became placed by blood Blood entered the catheter throu all four sideholes and the endhole by a pulsat movement and after a few seconds the layer of blo was continuous from the tip to the most proxim sidehole Further inflow took part at a rate equal that observed with catheters without sideholes (Fi 3 4) The effect of a sidehole was evaluated only small lumen catheters The sidehole was locat either one or 4 cm from the catheter tip Blood en tered the catheter lumen with a pulsative movem through both the sidehole and the endhole With Iso paque Cerebral a continuous blood layer betwe the catheter tip and sidehole was recorded within and 12 s respectively and with isotonic saline sol tion one and 3 s irrespective of the inclination of the catheters The differences were obvious and stati tical analysis was therefore not performed

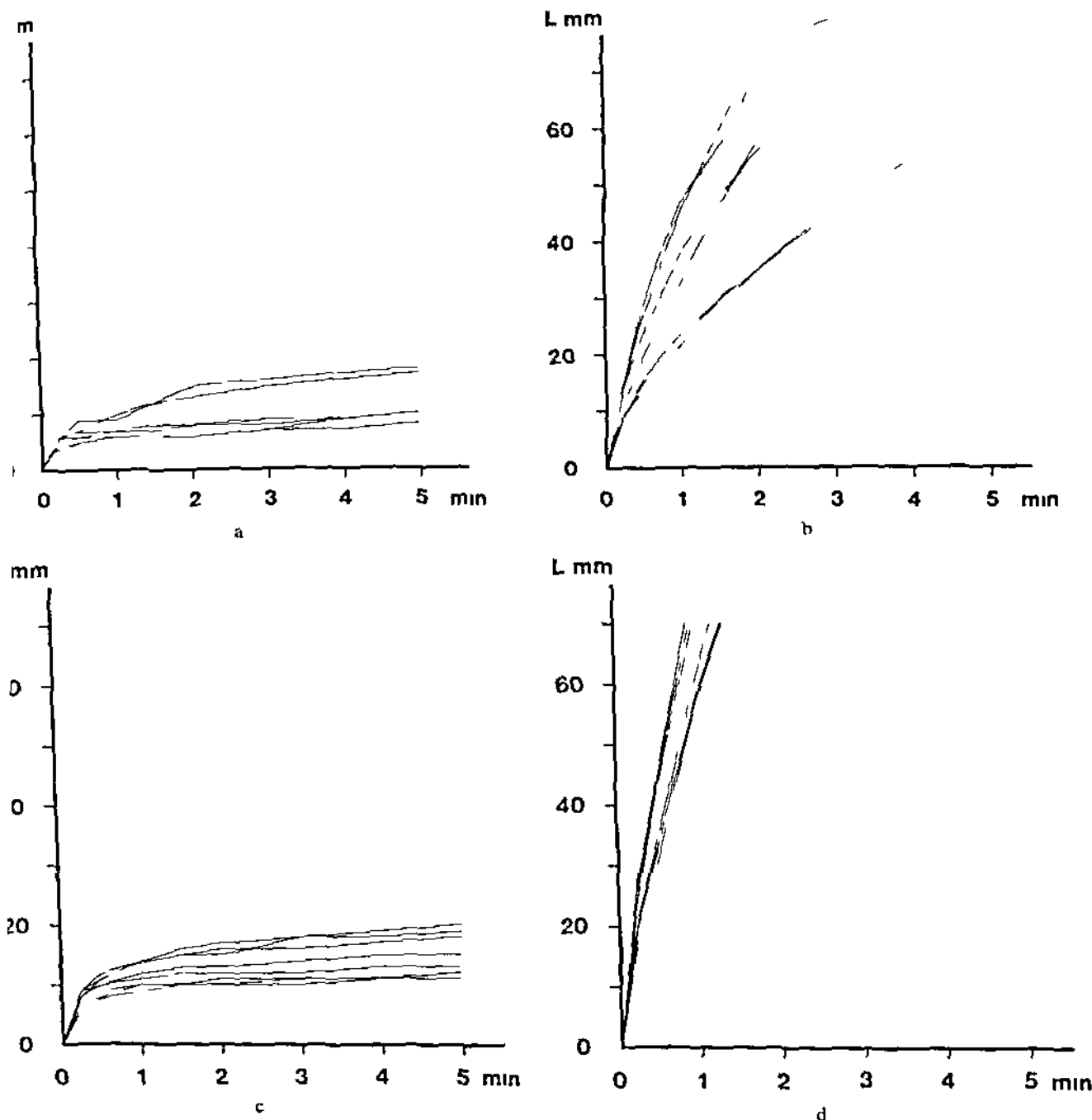


Fig 1 Inflow of blood into small (a b) and large (c d) catheters after injection of contrast medium The blood inflow was increased with catheter direction downwards (b d) compared with upwards (a c)

Discussion

The experimental equipment was the one used previously (DAHLBORN & SÖDERLUND) It is designed to produce a pulsative blood flow which is kept constant within an approximatively physiologic range during the experiment The variations of pulse rate blood pressure and blood flow recorded in the whole series of experiments were found hardly to influence the overall results the variation in inflow rate of blood in any subdivision of experiments being only minor Similar to what was recorded previously (DAHLBORN & SODERLUND) inflow of blood into the catheter was different with Isopaque Cerebral and isotonic saline solution in the catheter Because of gravity a fluid of high density will be deposited underneath a fluid of low density i e Isopaque Cerebral is located at a level below blood while

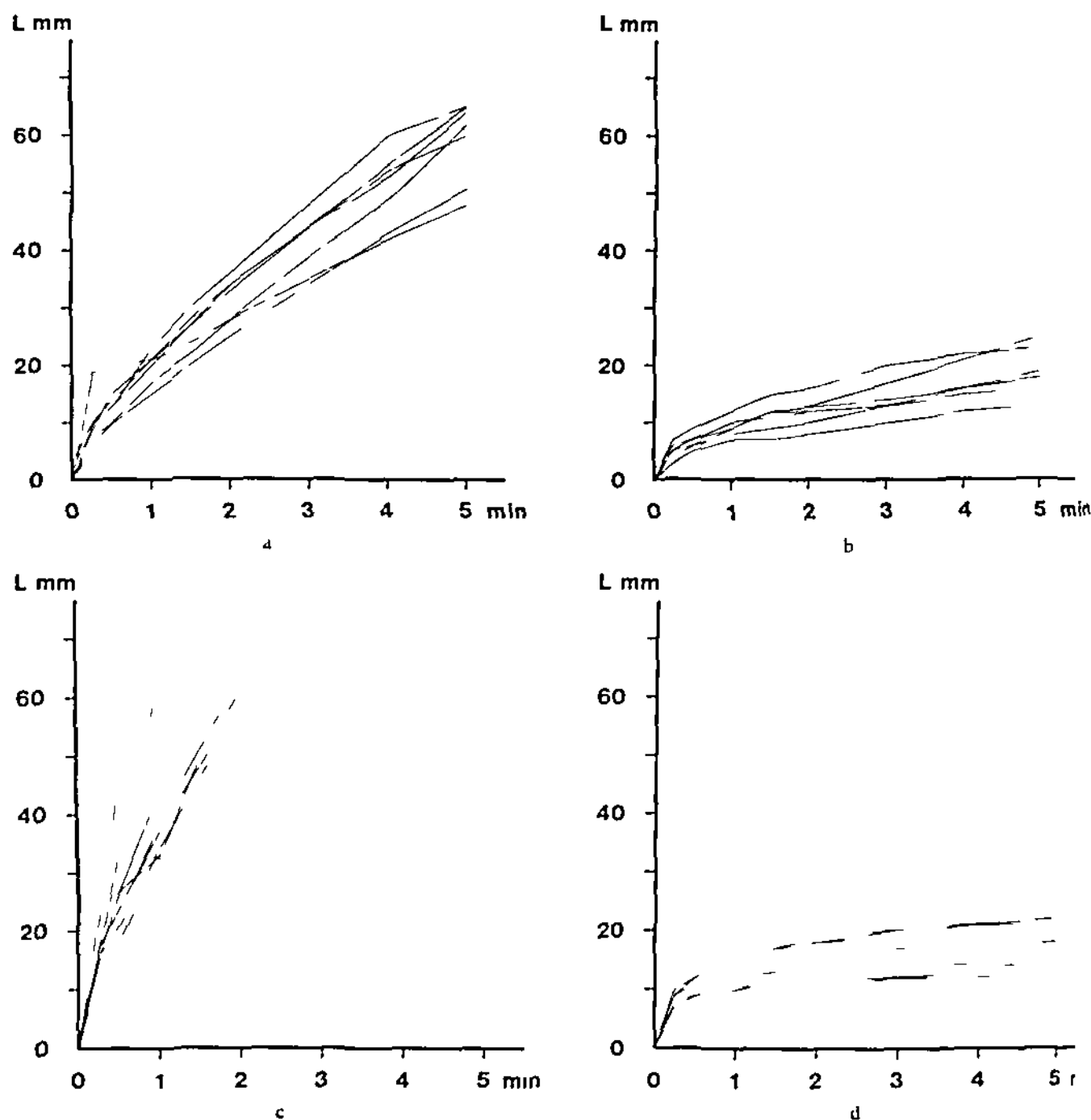


Fig 2 Inflow of blood into small (a b) and large (c d) catheters after injection of isotonic saline solution The process was more rapid with the catheter directed upwards (a c) compared downwards (b d)

isotonic saline solution forms a layer above it For the same reasons when the catheter was inclined downwards contrast medium could easily flow out through the catheter endhole This flow was markedly reduced when the catheter was directed upwards The results regarding isotonic saline solution as expected were the opposite ones Using a catheter with a larger lumen and directed downwards flow of the contrast medium out of the catheter is facilitated as is upward flow with isotonic sal solution

The same principle should be valid regardi sideholes Theoretically a sidehole situated on t superior surface of a catheter would allow the o flow of saline solution and an inferior one that contrast medium In the present experiments t catheters were oriented to let the sideholes face t lateral aspects in order to make the results strict

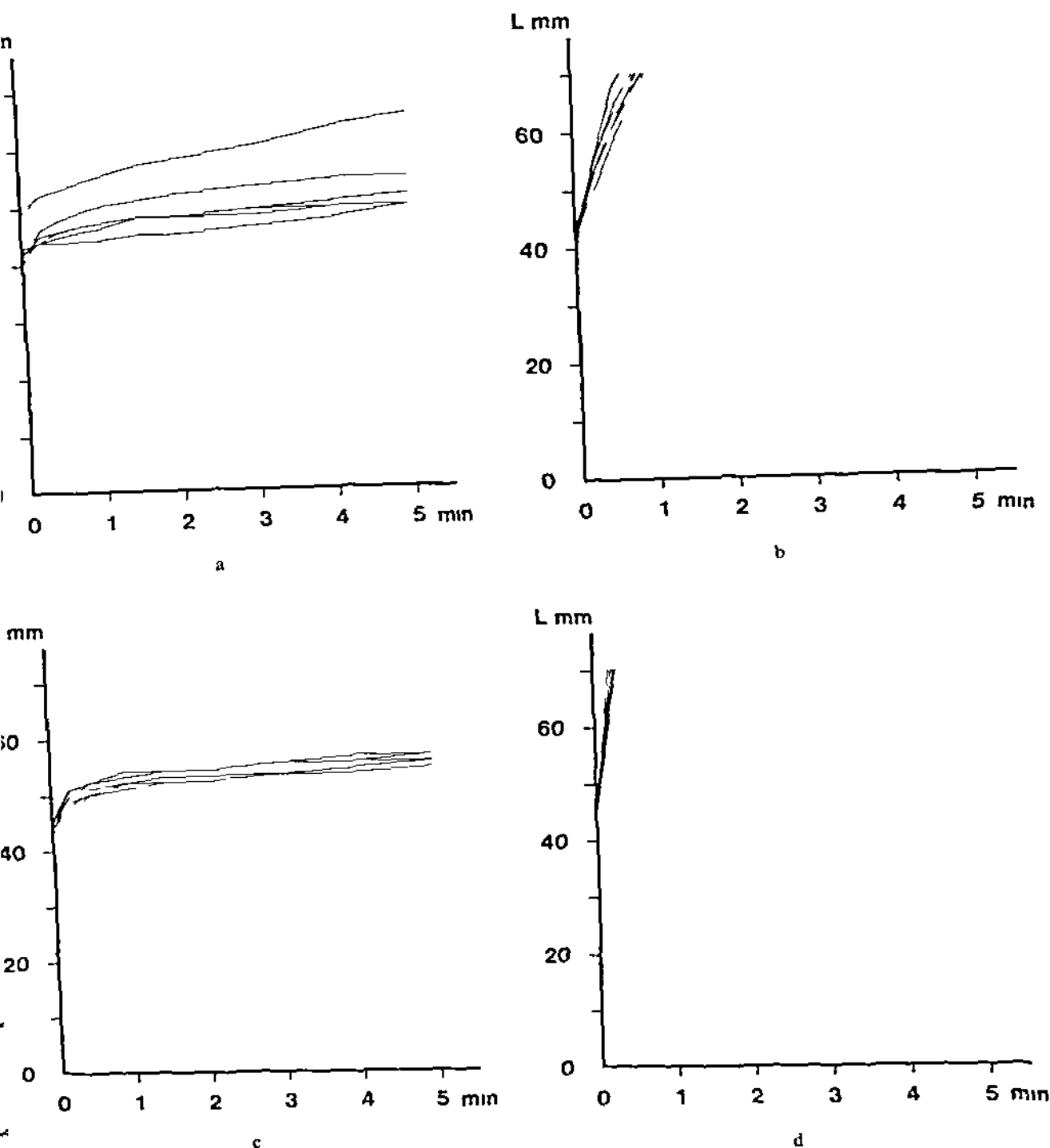


Fig 3 Instant inflow of blood into (a b) small and (c d) large catheters with 4 sideholes after injection of contrast medium regardless of catheter direction upwards (a c) and downwards (b d)

comparable for the two fluids In the experiments with four sideholes the flush fluids left the catheter instantly through all five holes and it was not possible to record any differences regarding the outflow speed of the fluids However the blood column beyond the sideholes behaved exactly as in a catheter with an endhole only A difference in outflow between the two fluids could be recorded with catheters with one sidehole only—in addition to the endhole—the saline solution leaking out more rapidly than the contrast medium The difference became more obvious with catheters with increased dis

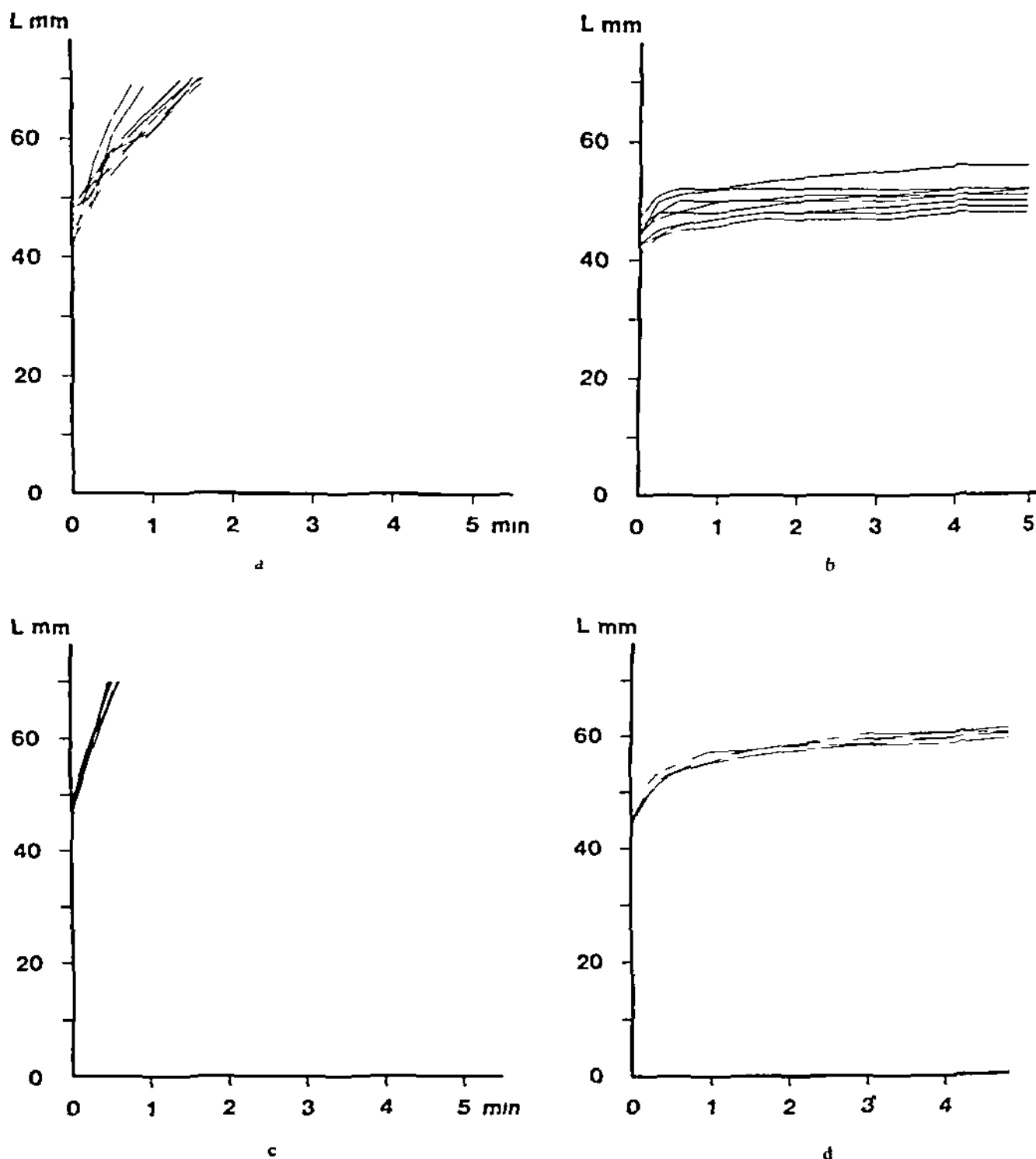


Fig 4 Instant inflow of blood into (a b) small and (c d) large catheters with 4 sideholes after injection of isotonic saline solution irrespective of whether the catheter was directed (a c) or downwards (b d)

tance between the endhole and sidehole This should reflect the influence of the different viscosity of the fluids contrast medium having a higher viscosity than has isotonic saline solution which should leak out more rapidly

The experiments were performed with an artificial equipment intended to represent the arterial circulation system Because the pulsative pulse rate and blood pressure were kept with almost physiologic range the results are consi to be valid also for clinical purposes Flush injections should be made frequently espe

vhen intra arterial catheters with a large inner liameter and those with sideholes are used However neither contrast medium nor isotonic saline olution seem to be ideal It is evident that flush igents with physical properties more akin to those of blood would be advantageous when used in clinical contexts A work in progress intends to produce and est such agents

SUMMARY

Using an experimental model of the arterial circulation ystem inflow of blood into polyethylene catheters fol owing injection of contrast medium and isotonic saline olution was evaluated The experiments included an analysis of the influence of density and viscosity of the lush solutions as well as the effect of catheters of different izes with and without sideholes

REFERENCES

DAHLBORN M and SODERLUND U Blood inflow into vascular catheters following injection of saline solution and contrast medium Model experiments Acta radiol Diagnosis 20 (1979) 439

— CALISSENDORFF B and CRONESTRAND R Blood in flow into intra arterial catheters following injection of contrast medium Acta radiol Diagnosis 19 (1978) 817

HAWKINS I F and HERBERT L Contrast material used as a catheter flushing agent A method to reduce clot formation during angiography Radiology 110 (1974) 351

JACOBSSON B and SCHLOSSMAN D Angiographic investigation on formation of thrombi on vascular catheters Radiology 93 (1969) 355

SCHLOSSMAN D Thrombogenic properties of vascular catheter materials in vivo Acta radiol Diagnosis 14 (1973) 97

ROM THE DEPARTMENT OF THORACIC RADIOLOGY KAROLINSKA SJUKHUSET S-10401 STOCKHOLM
SWEDEN

REPRODUCIBILITY OF PULMONARY STRUCTURES ON CONVENTIONAL CHEST FILMS

A SZAMOSI

The description of one and the same chest film has een found to vary between different observers and t different occasions with the same observer (GAR AND 1949 YERUSHALMY 1969 HERMAN et coll 975) The disagreement has been termed inter and ntraobserver error respectively Dual readings of e films have been recommended (GARLAND) to iminish the frequency and the significance of the onsequences of this variance

On the other hand the reproducibility of one and he same pulmonary structure when several chest ilms are exposed appears not to have been the bject of any systematic analysis The absence of r variations in reproducibility when observed is isually assumed to be due to technical errors and ometimes mentioned casually Thus FELSON (1979) tates that a film of excellent quality may show harply defined unequivocal structures whereas nother film of less than optimum quality of the ame patient the same day may show only small rregular structures or even appear normal Some bservations concerning the reproducibility are now eported

Material and Methods

Chest films of 26 patients were analysed All pa ients were examined at the department at least nce the majority several times Every examination ncluded postero anterior lateral and two oblique rojections Kodak XL1 films were exposed be ween X omatic screens at 170 kV and 400 mA exposure times being generally below 10 ms Focus film distance was 2 m and focal spot size 1 2 mm Stationary grid 40 l/cm with ratio 1 12 was used About one half of the patients had also chest films from other hospitals where the kV varied between 120 and 150 and the focus film distance between 150 and 180 cm The other technical details varied However the general quality of these films was considered to be comparable and sufficient to dem onstrate the relevant structure Any set of chest films from other hospitals consisted of p a and lat eral views

Each patient had one or several nodules in the periphery of the lungs Each nodule was observable on at least 3 films taken in postero-anterior and in right or left anterior oblique projections respective ly The nodules were 3 to 15 mm in diameter For each patient 1 to 9 additional films were available in the projection which demonstrated the nodule most clearly The films were exposed either on the same occasion or—in the course of subsequent controls—at intervals ranging from a few days up to several years In 21 cases the noduli were benign as estab lished at surgery and subsequent microscopic ex amination or as considered from their appearance and absence of growth over a period of at least 7 years These patients were also symptom less Five of the patients had pulmonary metastases from osteo or chondrosarcoma The presence of the

Submitted for publication 31 August 1979




Fig 1 Three views of the same pulmonary nodule (probably benign not operated upon) the same size on a series of films over 9 years a) Sharp borders b) indistinct borders c) almost invisible a) and b) exposed the same day c) 10 days later On still later films the nodule had the same appearance as in (b)

nodules visible on the chest films was confirmed at surgery in all of them In these cases only films exposed the same day were compared

All available films of any individual patient taken in the same projection (mostly p a) as the one on which the nodule was most clearly observable were compared with each other by simple visual inspection In 5 cases the nodules were most evident c left or right anterior oblique view and then were compared

The presence of any nodule was consider established whenever it was clearly demonst on at least three films exposed in two or different projections Films with no clear and sh



a



b



c

Fig 2 Three views of the same hamartoma a) Very sharp borders and smooth contours b) somewhat irregular less distinct border c) almost invisible nodule The interval between (a) and (b) 5 months between (b) and (c) 3 months At examination (c) the hamartoma was clearly observed on a lateral film and was enucleated the next day

y depicted structures such as rib edges or pulmonary blood vessels in the area around the nodules were excluded The same was true for films with apparent errors in exposure or with other technical faults

Observations

The radiologic appearance of any nodule was not constant but varied considerably from one film to another Usually the nodule was well outlined with



a



b



c

Fig 3 Three views of the same metastatic nodules from osteogenic sarcoma Left anterior oblique view a) Upper nodule evident the lower one is difficult to observe b) the lower nodule evident the upper one is difficult to observe c) both noduli are evident Interval between exposures 1 min

maximum sharpness on one to 3 films only on the majority of films it was less well outlined The contour varied also in smoothness and evenness (Figs 2 5) Seven films were found on which the nodule was not visible notwithstanding that it was evide other films either exposed at the same examin or earlier or later (Figs 1–4) In these cases an i ular hazy area appeared on the film at the site o

a

b

g 4 Metastatic noduli from osteogenic sarcoma a) Two evi nt noduli b) only the upper one visible Interval between posures 1 min Both were found and enucleated at surgery



a

b

ig 5 Hamartoma in right lower lobe a) Fairly sharp border b) ndistinct fuzzy structure on the same site Interval between (a) nd (b) 1 min

nodule suggesting a blurring effect However no blurring of the small pulmonary vessels or of the rib dges existed within that area The disappearance of the nodules occurred on films from other hospitals as well as on films from this department

Discussion

The findings indicate that considerable variations may occur in the appearance of one and the same pulmonary nodule from one exposure to the next





a b

Fig 6 Two views of the same normal lung Left anterior oblique view A pulmonary blood vessel (presumably an artery to the apical segment of the left lower lobe) distinct in (a) almost in (b) One min interval

notwithstanding that the obtained chest films appear to be of comparable technical quality The cause or causes of these variations is at present not exactly known

All noduli have been well above the threshold of visibility and been located in lung regions easily *accessible to visual search i e unobscured by the* heart mediastinum or spine The high kV has expectedly ensured their visibility even through bony structures

Pulmonary structures which are distributed mainly along a single plane (e g a thickened segment of an interlobar pleura) are notorious for their ability to appear on or disappear from the chest films due to small changes in their orientation with respect to the central beam of radiation Similiarly structures just in front of or behind the hila while otherwise completely well visible may at certain phases of respiration be superimposed on the central vessels and thus elude detection However the present material consists entirely of rounded nodular structures situated in the periphery of the lungs Consequently none of these mechanisms can explain the findings

The sharp borders displayed by other structures in the same area virtually excludes gross technical imperfections Defect anodes faulty intensi screens or impaired mechanical contact bet screens and films etc can thus also be disrega as plausible reasons for the observed variatio the appearance of the noduli

At visual comparison the appearance of the c *films has been reasonably similar in all resp* except the nodules Yet it cannot be assumed they really have been a perfect duplicate to e other Minor differences in geometric projection in the phases of the respiratory and cardiac cycle which the exposure took place have probably curred all the more so as no devices were used avoid them e g respiratory phase correlator S minute variations probably unavoidable in eve day routine and hard to detect without very care comparison may give a sufficient explanation of t findings though possibly through various mech isms

The superimposition of a pulmonary nodule o rib per se does not exclude good visibility of t nodule (Figs 3a c 4a 5) On the other h minute variations in geometric projection or in degree of inflation of the lung can change the stellation and complexity of the background st

res (mainly pulmonary vessels and ribs) against hich the nodule stands out Such changes can in uence detectability (REVESZ et coll 1974)

Another mechanism which probably operates is dicated in Fig 6 (not from the present series) On) a pulmonary vessel is easily observed in the ical segment of the left lower lobe whereas it is most invisible on (b) exposed at the same occa on A faint linear structure corresponding to the te and course of the vessel can still be discerned on) suggesting blurring Such blurring could occur ue to pulsations caused by the phasic pulmonary lood flow The similarity with Figs 1c 2c 4b 5b striking and suggests the same mechanism causing e disappearance of the nodule

While additional factors may contribute to the ame effect such minute variations in the back round and unsharpness caused by the pulsat g pulmonary blood flow may in themselves explain e findings

If this explanation is correct then the following ostulate can be formulated For pulmonary struc ires within certain limits concerning their size and ontrast a definite at present unknown and some hat varying statistical probability of becoming lequately demonstrated at any single exposure xists It means that increasing the number of ex posures increases the probability of the radiologic emonstration or conversely increases the chances f disappearance on at least one film In practice is postulate seems to have validity for cylindric or odular structures with soft tissue attenuation and ith a diameter roughly between 3 and 20 mm

The term adequately demonstrated refers to the arying clinical context In the case illustrated in ig 2 the diagnosis of benign pulmonary nodule g hamartoma can be made with reasonably high robability on film (a) with much less confidence on b) whereas the lesion will probably be missed alto- ether on (c) When looking for metastases from a nown primary tumour the emphasis is laid on de ection of noduli whereas the appearances of the utline is of limited importance

The findings may contribute to the understanding why computer tomography sometimes demonstrates ulmonary nodules which ought to be but not actu lly have been demonstrated on conventional chest ilms The CT detects the nodule by recording the ime average attenuation of the pixels containing it This will always be high in most pixels irrespective of pulsations On the conventional film the small pulmonary nodule with low inherent contrast can only be detected when its borders are sharp and thus the contrast gradient across the observer s retina is sufficiently high (TUDDENHAM 1963) If the borders of the nodule are blurred by the transmitted pulsa tions detection can be difficult or impossible

Important medical decisions are sometimes based on the presence or absence of a pulmonary nodule or on the appearance of its border Obviously it is not possible to rely completely on the testimony of any single chest film in these respects except when the nodule appears with maximum sharpness The general use of devices ensuring exactly identical geometric projection or identical respiratory and cardiac phases in the moment of exposure cannot be recommended at present However it is neces sary to be aware of the from exposure to exposure variability of pulmonary structures and make the decisions accordingly

SUMMARY

All available chest films of 26 patients with pulmonary noduli (3 to 15 mm in diameter) were compared Great variations in the appearance of one and the same nodule was noted On 7 films the nodule could not be detected at all in spite of the fact that other films taken in the same geometric projection did show it and no technical faults were apparent Blurring caused by pulsating pulmonary blood flow and minute variations in the background sur rounding the noduli are considered to be the main causes of a certain from exposure to exposure variability of the conventional chest film

REFERENCES

FELSON B A new look at pattern recognition of diffuse pulmonary disease Amer J Roentgenol 133 (1979) 183

GARLAND L H On the scientific evaluation of diagnostic procedures Radiology 52 (1949) 309

HERMAN P G GERSON D E HESSEL S J MAYER B S WATNICK M BLESSER B and OZONOFF D Dis agreements in chest roentgen interpretation Chest 68 (1975) 278

REVESZ G KUNDEL H L and GRABER M A The influ ence of structured noise on the detection of radiologic abnormalities Invest Radiol 9 (1974) 479

TUDDENHAM W J Problems of perception in chest roentgenology Facts and fallacies Radiol Clin N Amer 1 (1963) 277

YERUSHALMY J The statistical assessment of the varia bility in observer perception and description of roentgenographic pulmonary shadows Radiol Clin N Amer 3 (1969) 381

:OM THE DEPARTMENT OF DIAGNOSTIC RADIOLOGY MALMÖ ALLMANNA SJUKHUS S-21401 MALMÖ SWEDEN

PERCUTANEOUS NEPHROSTOMY

Aspects on clinical application

J HILDELL P ASPELIN and B SIGFUSSON

Puncture of the renal pelvis was described by ICKBOM (1954) One year later GOODWIN et coll 955) used the same technique for percutaneous phrostomy but it was not until the last years that ie method has become widely recognized as an al rnative to an operative nephrostomy (VELA NA ARRETE 1971 JONSSON et coll 1972 ALMGÅRD FERNSTRÖM 1974 FOWLER et coll 1975 BUR ETT et coll 1976 BARBARIC & WOOD 1977 GUN HER et coll 1977 HELLSTEN et coll 1977 PERI ETTI et coll 1978 STABLES et coll 1975 1978) he indications for the procedure have expanded nd now include not only supravesical urinary diver ion but also extraction of pelvic and ureteral stones FERNSTRÖM & JOHANSSON 1976 SMITH et coll 978b HELLSTEN et coll 1980) dissolution of tones (SPATARO et coll 1978) brush biopsy from elvocalyceal lesions (LANG et coll 1978) dilatation f ureteral strictures (GUNTHER et coll 1978) and in ertion of ureteral stents (SMITH et coll 1978a)

The experiences at this department are now re ported and a survey is given of the clinical useful ness of percutaneous nephrostomy as reported in he literature

Material and Methods

During a 6 year period 1973 through 1978 132 percutaneous nephrostomies were performed in 115 patients 61 males and 54 females aged between 29 and 82 years (mean 66 years) Their basic disorders are listed in Table 1

Technique The technique has been described in detail previously (HELLSTEN et coll 1977) There fore only a short description will be given here

The puncture is made on the prone patient be neath the twelfth rib using a lateral approach (Fig 1) The pelvocalyceal system usually can be ob served at fluoroscopy after intravenous injection of contrast medium and ultrasonography is used to choose the proper site and angle of puncture If a sufficient amount of contrast medium for demon stration of the renal pelvis is not excreted contrast medium is injected directly into the pelvis using an ultrasonic guided fine needle puncture

The puncture is made with a 17-cm Venflon nee dle combination (Viggo Sweden) Using conven tional angiographic technique this catheter is re placed by a grey Odman angiographic catheter (Sur gimed Denmark) which is left for initial drainage When long term or permanent drainage is desirable or percutaneous stone extraction is contemplated change to progressively larger catheters is per formed The usual sequence is the following grey Odman Nelaton (Pharmaplast Denmark) 10 F 12 F 14 F Foley (Bard International England) 12 F 14 F etc

Technical problems at insertion or change of catheters are usually due to kinking of the guide wire Long thin walled needles with a blunt end introduced over the guide wire are used to prevent such a kinking (Fig 2)

Results

Percutaneous nephrostomy was attempted in 117 patients and successful in 115 unilateral in 98 and

Submitted for publication ?7 June 1979



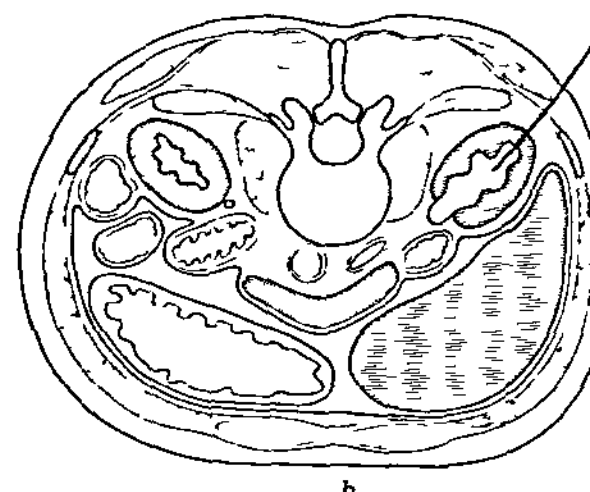


Fig 1 Routine approach at puncture of the renal pelvis

bilateral in 17 patients In 52 the procedure was used for permanent drainage and in 63 patients for temporary drainage The type of catheter used and the duration of drainage appear in Table 2

Permanent drainage was used in patients with malignant disease who could be offered no further surgical therapy The aim was to insert a Foley catheter but this was not always possible Six patients had a grey Ödman catheter for final drainage 4 of them because their general condition did not allow change of catheter and 2 because change was technically difficult or impossible Nelaton catheters were used in 2 patients whose renal pelves were too small to lodge a Foley catheter (Fig 3)

Temporary drainage was used as the only therapy in 8 patients 6 with operative lesions of the ureter and 2 with renal stones In 2 patients it was performed to make possible stone extraction through the nephrostomy tract (Fig 4) In 31 patients it was used together with surgery and in 22 patients together with radiation or chemotherapy More detailed information of the indications for temporary drainage and the therapy used is given in Table 3

Major complications in the form of severe intrapelvic or extrarenal bleeding occurred in 5 patients and were always related to a technical difficulty In 3 patients bleeding occurred at repuncture after the initial catheter had slipped out from the renal pelvis and in 2 patients in connection with change of catheter All 3 patients in whom repuncture was complicated by bleeding had small intrarenal pelves and an increased bleeding tendency due to pyelonephritis The repunctures were made immediately after it was evident that the catheter had slipped out from the renal p[…] Therefore during the last two years an atte[…] repuncture was made after an interval of 2 to […] and during that time no such complicatio[…] curred

Symptomatic infection occurred in 2 patient[…] of these had pyelonephritis and got a high […] fever each time the catheter was changed

Puncture of the left hemicolon occurred i[…] patient A fistula which developed between t[…]lon and the renal pelvis healed on conser[…]

Table 1

Disorders necessitating percutaneous nephrostom[…]

Diagnosis	No of patie[…]
Carcinoma of	
urinary bladder	7
prostatic gland	34
ureter	[illegible]
uterus or ovaries	16
small bowel	1
colon	
rectum	3
Lymphoma	
Operative lesion of the distal ureter	8
Pyelonephritis with sepsis	[illegible]
Ureteral stone	11
Pelvic stone	
Hydronephrosis of non-malignant etiology	1
Total	115



Fig 2



Fig 3



Fig 4

Fig A long thin walled needle is introduced over the guide wire and inside the catheter to prevent kinking

Fig 3 Small renal pelvis The inflated balloon of the Foley catheter is too large for the pelvis and causes obstruction of the lower calices

Fig 4 Extraction of stone from the left renal pelvis by a nephrostomy tract

reatment The duodenum was accidentally punctured in one patient When the patient died a few days later autopsy revealed a localized peritonitis

In one patient the puncture resulted in a pneumothorax which was successfully treated by an intercostal catheter and water seal drainage

Minor complications were also encountered The most common was catheters slipping out from the renal pelvis which occurred in 30 cases 17 Foley catheters and 13 grey Odman or Nelaton catheters When Foley catheters slipped out it was always due to collapsing of the balloon A few of the Odman and Nelaton catheters were accidently pulled out by the patients but in most cases the reason was kinking of the catheter in the tissues between the skin and the kidney In 17 of the 30 patients repuncture became necessary because the nephrostomy tract could not be recatheterized Even if the nephrostomy tract is well established it rapidly occludes if the catheter leaves it

Table 2

Type of drainage catheter and duration of treatment (figures within parentheses = bilateral nephrostomy)

Type of catheter	Permanent drainage			Temporary drainage		
	No of patients	Duration (days)		No of patients	Duration (days)	
		Range	Mean		Range	Mean
Grey Ödman	6 (1)	[illegible]1–35	[illegible]5	43 (1)	1–40	16
Nelaton	[illegible] (1)	12–30	[illegible]4	7	20–45	32
Foley	44 (11)	17–621	156	13 (3)	21–350	1[illegible]1
Total	5[illegible] (13)			63 (4)		

Table 3

Disorders necessitating percutaneous nephrostomy and therapeutic methods used

No of patients	Indications	Therapy
5	Carcinoma of urinary bladder	Irradiation
3	Carcinoma of urinary bladder	Surgery
5	Carcinoma of prostatic gland	Irradiation
7	Carcinoma of prostatic gland	Chemotherapy
[illegible]	Carcinoma of ureter	Surgery
1	Carcinoma of colon	Surgery
[illegible]	Lymphoma	Irradiation
6	Operative lesion of the distal ureter	Percutaneous nephrostomy only
[illegible]	Operative lesion of the distal ureter	Surgery
	Pyelonephritis with sepsis	Chemotherapy
	Ureteral stone	Percutaneous nephrostomy only (spontaneous delivery)
11	Ureteral stone	Surgery
	Pelvic stone	Percutaneous stone extraction
1[illegible]	Hydronephrosis of non malignant etiology	Surgery
63	Total	

Other minor complications were perforation of the renal pelvis by the tip of the catheter transient bacteriuria transient bleeding into the renal pelvis and small retroperitoneal hematomas found at autopsy or operation

Discussion

Several techniques for percutaneous nephrostomy have been reported Most of them are based on the angiographic Seldinger technique Some require special devices and a certain amount of experience to be performed safely (ALMGÅRD & FERNSTRÖM) Others are time-consuming and may require general anesthesia (BURNETT et coll) consequently part of the advantage of the percutaneous approach is lost

The present technique has the advantage tha[illegible] other equipment is needed than is normally avai[illegible] in an angiographic department It is easily lea[illegible] and mastered by those with angiographic trai[illegible] and in experienced hands the placement of [illegible] catheter into the renal pelvis is performed in [illegible] than 10 to 15 minutes Moreover it is well suited [illegible] ultrasonic guided puncture (PEDERSEN et coll 19[illegible] HELLSTEN et coll 1977)

In many cases the nature or the appearance of [illegible] lesion causing the urinary obstruction is not kn[illegible] when the initial puncture is made Neither is it e[illegible] dent if the nephrostomy is going to be of perm[illegible] or temporary nature nor if temporary for how lo[illegible] it should be maintained The technique repor[illegible] relatively non traumatic and provides a possib[illegible]

choose the proper catheter after the acute episode over

Most of the major complications occurred in con ction with the initial puncture or with repuncture er a catheter had slipped out from the renal pelvis hen a catheter had slipped out attempts were ade to catheterize the tract with a catheter of a all caliber and a guide wire It may also be of lue to inject contrast medium through the opening the skin making the tract visible at fluoroscopy If is not possible to find the tract it is advisable to ait 2 to 5 days before repuncture is made in order avoid bleeding

In this hospital percutaneous nephrostomy for upravesical urinary diversion has gradually re aced operative nephrostomy which is now never sed in emergency cases but only in conjunction ith elective operations such as pyelolithotomy and yeloplasty Moreover the indications have ex anded Apart from emergency situations per utaneous nephrostomy is also used in patients with lative contraindications to surgery for instance in atients with ureteral stones and a complicating dis ase or an unfavourable location of the stones Pa ents with congenital megalo ureter are treated be ore and after neo implantation of the ureters perative ureteral fistulas healed after 2 to 4 weeks eatment with percutaneous nephrostomy in 6 of 8 atients

In 2 patients stone extraction from the renal pel is was performed This procedure reported by ERNSTROM & JOHANSSON and HELLSTEN et coll 1980) should be considered in cases where an perative removal of the stone may become trouble ome or potentially dangerous because of multiple revious operations However the diameter of the tone should not exceed 10 to 12 mm

Distal ureteral stones in patients with an ileal loop nay represent a therapeutic problem since the inatomy of the loop often does not make removal of he stone possible by way of endoscopy and a Dor nia basket SMITH et coll (1978b) described a echnique for removal of such stones by aid of en loscopy and percutaneous nephrostomy

Ureteral stricture caused by fibrosis may also be a therapeutic problem Operative treatment may be less advisable because of extensive and dense scar issue It may be possible to dilate such strictures by using percutaneous nephrostomy (GUNTHER et coll 1978)

In patients with ureteral stricture due to tumor the placement of indwelling ureteral stents has been reported to be a successful alternative to a perma nent nephrostomy (GIBBONS et coll 1976) How ever it may be impossible to insert the stent by cystoscopy For such cases SMITH et coll (1978a) described a method to place the stent catheter by aid of percutaneous nephrostomy

Other therapeutic and diagnostic possibilities re ported include dissolution of uric acid stones (SPA TARO et coll) and brush biopsies from pelvocalyceal lesions (LANG et coll)

The fact that percutaneous nephrostomy today can be performed with a minimum of complications implies that it is sometimes contemplated in patients who are in bad general condition due to widespread malignant disease In some of these patients it is questionable whether nephrostomy is of any value The procedure may not even give them a few weeks or months of useful life but instead a prolonged suffering HOLDEN et coll (1979) analyzed the rationale of operative urinary diversion in 218 pa tients with malignant disease They found that a useful life of 2 months was given to 100 per cent of patients with local disease to 59 per cent with re gional disease and to 43 per cent with widespread disease They concluded that nephrostomy should be offered any patient with advanced malignant tumor in whom further therapy is contemplated no matter how remote This conclusion is in accord ance with the current policy in this hospital How ever it is easier to order a percutaneous than an operative nephrostomy and therefore when a per cutaneous nephrostomy is contemplated the indica tions should be carefully considered and discussed between the clinician and the radiologist

SUMMARY

During a 6-year period percutaneous nephrostomy has been used for supravesical urinary diversion in 115 pa tients and 132 individual kidneys The procedure proved to be a safe and effective alternative to operative nephros tomy in patients with urinary obstruction but may be used also in other urologic conditions

ACKNOWLEDGEMENT

The authors wish to thank Dr S Sigurjonsson for draw ing the illustrations

REFERENCES

ALMGÅRD L E and FERNSTRÖM I Percutaneous nephropyelostomy Acta radiol Diagnosis 15 (1974) 288

BARBARIC Z L and WOOD B P Emergency percutaneous nephropyelostomy Experience with 34 patients and review of the literature Amer J Roentgenol 128 (1977) 453

BURNETT L L CORREA R J and BUSH W H A new method for percutaneous nephrostomy Radiology 120 (1976) 557

FERNSTRÖM I and JOHANSSON B Percutaneous pyelolithotomy Scand J Urol Nephrol 10 (1976) 257

FOWLER J E MEARES E M and GOLDIN A R Percutaneous nephrostomy Techniques indications and results *Urology* 6 (1975) 428

GIBBONS R P CORREA R J CUMMINGS K B and MASON J T Experience with indwelling ureteral stent catheters J Urol 115 (1976) 22

GOODWIN W E CASEY W C and WOOLF W Percutaneous trocar (needle) nephrostomy in hydronephrosis J Amer med Ass 157 (1955) 891

GUNTHER R ALKEN P und ALTWEIN J E Ureterobstruktion Percutane transrenale Ureterschienung Akt Urol 9 (1978) 195

— ALTWEIN J E und GEORGI M Feinnadelpunktion zur antegraden Pyelographie und perkutanen Nephropyelostomie Fortschr Rontgenstr 127 (1977) 439

HARRIS R D McCULLOUGH D and TALNER L B Percutaneous nephrostomy J Urol 115 (1976) 628

HELLSTEN S FRANK B and HILDELL J Percutaneous pyelolithotomy Case report and technical comments Europ Urol 6 (1980) 50

— HILDELL J LINK D and ULMSTEN U Percutaneous nephrostomy Aspects on applications and technique Europ Urol 4 (1977) 282

HEPPERLEN T W MARDIS H K and KAMMANDEL H The pigtail ureteral stent in the cancer patient J Urol 121 (1979) 17

HOLDEN S McPHEE M and GRABSTALD H rationale of urinary diversion in cancer pa Urol 121 (1979) 19

JONSSON M LINDBERG B and RISHOLM L P ous nephropyelostomy in cases of ureteral obstru Scand J Urol Nephrol 6 (1972) 51

LANG E K ALEXANDER R BARNETT T Palou and HANWAY S Brush biopsy of pyelocalyceal le via percutaneous translumbar approach Radiolo (1978) 623

PEDERSEN J F COWAN D F KVIST KRISTENSEN HOLM H H HANCKE S and JENSEN F Ultraso ly guided percutaneous nephrostomy Radiolo (1976) 429

PERINETTI E CATALONA W J MANLEY C B Geis and FAIR W R *Percutaneous nephrostomy* Ind tions complications and clinical usefulness J U 120 (1978) 156

SMITH A D LANGE P H MILLER R P and REINK B (a) Introduction of the Gibbons ureteral stent fa tated by percutaneous nephrostomy J Urol (1978) 543

— — REINKE D B and MILLER R P (b) Extractic ureteral calculi from patients with ileal loop A technique J Urol 120 (1978) 623

SPATARO R F LINKE C A and BARBARIC Z L The of percutaneous nephrostomy and urinary alkal *tion in the dissolution of obstructing uric acid st* Radiology 129 (1978) 629

STABLES D P GINSBERG N J and JOHNSON M Percutaneous nephrostomy A series and review of literature Amer J Roentgenol 130 (1978) 75

— HOLT S A SHERIDAN H M and DONOHUE R Permanent nephrostomy via percutaneous punctur Urol 114 (1975) 684

VELA NAVARRETE R Repeat direct pyelography via n dle nephrostomy Acta radiol Diagnosis 11 (1971

WICKBOM I Pyelography after direct puncture of the r nal pelvis Acta radiol 41 (1954) 505

FROM THE DEPARTMENTS OF CLINICAL CHEMISTRY DIAGNOSTIC RADIOLOGY AND UROLOGY MALMÖ ALLMANNA SJUKHUS S 21401 MALMÖ SWEDEN

PROTEINURIA FOLLOWING NEPHROANGIOGRAPHY

VI Comparison between metrizoate and metrizamide in man

S HOLTÅS T ALMÉN S HELLSTEN and L TEJLER

The nephrotoxicity of the triiodinated contrast media in common use today has been considered very low and almost negligible and angiography is nowadays performed also in patients with severely impaired renal function (KONG et coll 1963 ABRAMS 1971) However during the last years an increasing number of reports of renal failure induced by contrast medium have appeared in the literature (MCEVOY et coll 1970 BORRA et coll 1971 PORT et coll 1974 ANSARI & BALDWIN 1976 TEJLER et coll 1977 b MILMAN & GOTTLIEB 1977 HARKONEN & KJELLSTRAND 1977 ALEXANDER et coll 1978 KRUMLOVSKY et coll 1978) OLDER et coll (1976) and SWARTZ et coll (1978) suggest that the incidence of renal failure following angiography may be as high as 10 to 12 per cent Although the renal failure in these materials was mostly transient and present in patients with diseases affecting the kidneys already before angiography the suggested frequency points to the importance not to underestimate the risk of renal failure induced by contrast medium

Proteinuria is one sign of renal injury and has recently been detected to frequently occur following nephroangiography with the ionic contrast media Isopaque Coronar (meglumine Na Ca metrizoate) and Isopaque Cerebral (meglumine Ca metrizoate) in man (TEJLER et coll 1977 a) and after injection of Isopaque Cerebral and Urografin 76% (meglumine Na-diatrizoate) in dogs (HOLTÅS et coll 1978 a) The proteinuria has been shown to mainly be a result of increased glomerular permeability and the degree correlated to the dose of contrast medium High osmolality of the contrast medium has not been the dominating factor causing proteinuria since Urografin and the non ionic contrast medium Amipaque (metrizamide) with about one third of the osmolality of that of Urografin induced the same degree of proteinuria in dogs The chemical structure seems to be more important since an experimental substance with the code name C29 having about the same osmolality as Amipaque induced significantly less proteinuria than Amipaque or Urografin (TEJLER et coll 1977 a HOLTÅS et coll 1978 a b HOLTÅS & TEJLER 1979)

At this hospital Amipaque is not infrequently used for various angiographic procedures and as a routine for nephroangiography of transplanted kidneys As proteinuria might be a factor in the development of renal failure after angiography and certainly indicates disturbed renal function it was considered of value to estimate the proteinuric effect of Amipaque also in man This was done as a comparison between Amipaque and Isopaque Cerebral which is the contrast medium normally used for nephroangiography at this hospital

Material and Methods

The material consisted of 25 patients 17 males and 8 females with a median age of 59 years (range 19–78)

Submitted for publication 3 October 1979

Table

Median and range (within parentheses) of urinary albumin concentration before and after nephroangiography

Contrast medium	No of patients	Conc of albumin in urine (g/g creatinine)	
		Before angiography	*Maximum after angiography*
Isopaque Cerebral	13	0 056 (0 021–0 100)	2 2 (0 39–13)
Amipaque	12	0 046 (0 003–0 360)	1 2 (0 011–2 5)

Angiography Selective nephroangiography and aortography were performed with polyethylene catheters (OD/ID 2 2/1 45 mm) With an automatic pressure injector (Medrad Mark IV) 30 ml were injected at aortography and 10 to 12 ml at nephroangiography When a malignant tumor was found in the kidney an additional injection of 20 to 30 ml was made into the artery supplying the tumor and coeliacography and if necessary superior mesenteric angiography were performed in a search for liver metastases The median total volume of contrast medium given was 165 ml (range 30–265) The median total volume injected into one renal artery was 20 ml (range 5–80)

In 13 patients (median age 58 years range 37–75) the ionic contrast medium Isopaque Cerebral (280 mgI/ml) was used The median total volume given to these patients was 165 ml (range 100–265)

In 12 patients (median age 62 years range 19–78) the non ionic contrast medium Amipaque with a concentration of 280 mgI/ml was used The median total volume given to these patients was 150 ml (range 30–230)

The most frequent symptom indicating the angiography was haematuria of unknown origin In 6 patients in each contrast medium group a malignant tumor was found in one of the kidneys The dominating diagnosis among the remaining patients was renal cysts

Sampling and analysis Plasma and urine specimens were obtained before as soon as possible after the angiography (about 1/2–4 h) and on the day after the angiography In 14 patients specimens were obtained also 2 days after angiography All samples were frozen and kept at −20°C until analysis The concentration of creatinine and albumin was determined in all samples The analysis were perfor as previously described (TEJLER et coll 1977a)

For the statistical analysis the Mann Whit rank sum test or Wilcoxon s test for paired diff ences have been used Differences have been c sidered significant when p values ≤0 05 have b obtained

Results

Following nephroangiography the concentra of urinary albumin increased to a level more th times higher than the preangiographic concentra in 21 of the 25 patients Seven patients 5 in Isopaque Cerebral group and 2 in the Amipa group reacted with an increase exceeding 100 tim Two patients receiving Amipaque did not react increased concentration of urinary albumin

The maximum concentration of urinary alb occurred the same day as the angiography i except 2 patients who reached their maxima the after the angiography Urinary albumin concer tion was normalized the day after the angiograph 13 patients 2 days after in 5 patients and in remaining 5 patients reacting with increased buminuria the concentration was decreasing c pared with the maximum concentration the last of urine sampling

No significant difference was found in the deg of albuminuria caused by nephroangiography Isopaque Cerebral compared with Amipaque T median concentration of urinary albumin before maximum concentration after nephroangiogra with the 2 contrast media are presented in the Tab The degree of postangiographic albuminuria induc by nephroangiography with Isopaque Cerebral in t present series did not differ significantly from t

sults of a previous series in man (TEJLER et coll 977 a)

No correlation was found between dose of con ast medium and degree of postangiographic al uminuria regardless if the comparison was based 1 total amount of contrast medium or dose injected lectively into the renal arteries

Most patients had a slightly elevated concentra on of urinary albumin (Table upper normal limit r the laboratory 0 025 g/g creatinine) and microopic haematuria before angiography All patients cept 3 in the Isopaque Cerebral group and 2 in the mipaque group had normal concentrations of eatinine in plasma before angiography In the pa nts with elevated concentrations the level was ver higher than two times the upper normal limit pper normal limit for the laboratory 115/μmol/l for en and 100 μmol/l for women)

One patient in the Isopaque Cerebral group acted with an increase of creatinine in plasma from 0 to 260 μmol/l following nephroangiography wo weeks after the angiography the concentration id returned to preangiographic levels This patient so reacted with massive albuminuria (9 8 g/g eatinine) Among the other patients the changes in ncentration of creatinine in plasma did not exceed per cent

Discussion

The present results show that albuminuria often assive is induced by nephroangiography in man in igh frequency not only with the ionic contrast edium Isopaque Cerebral which has been obrved previously (TEJLER et coll 1977 a) but also injection of the non ionic contrast medium aque The degree of postangiographic al uminuria was not significantly different after injec on of the 2 contrast media which is in accordance with results obtained in dogs (HOLTÅS et coll 978 a HOLTÅS & TEJLER) The postangiographic roteinuria had an early onset and rapid disappear nce as demonstrated by the observation that the maximum concentration of urinary albumin was ound in the first urine sample taken 1/2 to 4 hours fter angiography in all except 2 patients and that normalization had already occurred the day after the ngiography in 13 patients

In dogs a correlation has been found between dose f contrast medium and degree of postangiographic lbuminuria (HOLTÅS et coll 1978 a) whereas no such relationship was found in the present series The reason for this discrepancy is probably that in man the variation in total dose was based mainly on variation in the number but not the volume of con trast medium injections selectively into the renal arteries When differences in degree of postangiographic albuminuria were found in dogs the volume of single selective injections was increased 4 times or more (HOLTÅS et coll 1978 a) This indicates that single injections of large volumes are more injurious to the kidney than repeated small injections

The present material consisted of patients with normal or only minor changes in renal function be fore angiography and no significant changes in the concentration of creatinine in plasma occurred ex cept in one patient who had a moderately elevated concentration already before angiography

There is probably only a very small risk of renal failure induced by contrast medium in patients with normal renal function before angiography despite the high frequency of massive postangiographic proteinuria but in patients with impaired renal function before angiography the risk is probably greatly in creased and might then in some cases be due to tubular blockage by precipitated proteins

Amipaque causes less pain during intraarterial in jections less changes in vascular endothelia and less changes in renal and peripheral circulation than ionic contrast media (ALMEN et coll 1973 1977 MLVES et coll 1978 MORRIS et coll 1978 NYMAN & ALMEN 1978) These properties make Amipaque suitable as contrast medium for nephroangiography when special demands are required as in patients with vulnerable transplanted kidneys The present results show that there is no increased risk of con trast medium induced renal failure due to protein uria compared with ionic contrast media

SUMMARY

The degree of albuminuria induced by nephroangiography was compared following injection of the ionic con trast medium Isopaque Cerebral (meglumine ca met rizoate) and the non ionic Amipaque (metrizamide) in man Both induced albuminuria in high frequency but the degree did not differ significantly

ACKNOWLEDGEMENTS

This investigation was supported by grants from the Medical Faculty University of Lund and the Swedish Research Council (Project No 3483) The skilful assis

tance of Ms Siv Granelli and Ms Birgitta Sparre is grateful ly acknowledged The authors are indebted to the medical staff at the Department of Urology and technicians at the angiographic section for their kind cooperation

REFERENCES

ABRAMS H Angiography Second edition p 22 Little Brown & Co Boston 1971

ALEXANDER R D BERKES S L and ABUELO J G Contrast media induced oliguric renal failure Arch intern Med 138 (1978) 381

ALMEN T BOIJSEN E and LINDELL S E Metrizamide in angiography I Femoral angiography Acta radiol Diagnosis 18 (1977) 33

— HARTEL M NYLANDER G and OLIVECRONA H Effects of metrizamide on silver staining of aortic endothelium A comparison with metrizoate media in rats Acta radiol (1973) Suppl No 335 p 233

ANSARI Z and BALDWIN D S Acute renal failure due to *radio contrast agents Nephron 17 (1976) 28*

BORRA S HAWKINS D DUGUID W and KAYE M Acute renal failure and nephrotic syndrome after angiocardiography with meglumine diatrizoate New Engl J Med 284 (1971) 592

HARKONEN S and KJELLSTRAND C Exacerbation of diabetic renal failure following intravenous pyelography Amer J Med 63 (1977) 939

HOLTÅS S and TEJLER L Proteinuria following nephroangiography IV Comparison in dogs between ionic and non ionic contrast media Acta radiol Diagnosis 20 (1979) 13

— ALMÉN T and TEJLER L (a) Proteinuria following nephroangiography II Influence of contrast medium and catheterization in dogs Acta radiol Diagnosis 19 (1978) 33

— — — (b) Proteinuria following nephroangiography III Role of osmolality and concentration of contrast medium in renal arteries in dogs Acta radiol Diagnosis 19 (1978) 401

KONG T MEANEY T DUSTAN H and SONES F Safety of selective renal arteriography Amer J med Sci (1963) 527

KRUMLOVSKY F SIMON N SANTHANAM S DEL G[illegible] F ROXE D and POMARANCE M Acute renal failure Association with administration of radiographic c[illegible] *trast material J Amer med Ass 239 (1978)* [illegible]

MCEVOY J MCGEOWN M G and KUMAR R Renal [illegible]ure after radiological contrast media Brit med J (1970) 717

MEVES M HUTHWOHL B und KRASKA H Die Anw[illegible]dung von Metrizamid bei der peripheren Angiograp[illegible] Eine vergleichende Untersuchung Fortschr Rön[illegible]str 128 (1978) 339

MILMAN N and GOTTLIEB P Renal function after h[illegible] dose urography in patients with chronic renal in[illegible]ciency Clin Nephrol 7 (1977) 250

MORRIS T W KATZBERG R W and FISCHER H W [illegible] comparison of the hemodynamic responses to m[illegible]rizamide and meglumine/sodium diatrizoate in c[illegible] renal angiography Invest Radiol 13 (1978) 74

NYMAN U and ALMÉN T Arterial and venous [illegible] pressure and blood flow following femoral angiog[illegible] with a new non ionic contrast medium An experim[illegible]tal investigation in dogs Acta radiol Diagnosis (1978) 1025

OLDER R MILLER J JACKSON D JOHNSRUDE I THOMPSON W Angiographically induced renal f[illegible] and its radiographic detection Amer J Roentg[illegible] 126 (1976) 1039

PORT F K WAGONER R D and FULTON R E [illegible] renal failure after angiography Amer J Roentg[illegible] 121 (1974) 544

SWARTZ R D RUBIN J E LEEMING B W and SIL[illegible] Renal failure following major angiography Am[illegible] Med 65 (1978) 31

TEJLER L ALMÉN T and HOLTÅS S (a) Protei[illegible] following nephroangiography I Clinical experie[illegible] Acta radiol Diagnosis 18 (1977) 634

— EKBERG M ALMÉN T and HOLTÅS S (b) Protei[illegible] following renal arteriography Report of two c[illegible] Acta med scand 202 (1977) 131

OM THE LABORATOIRE DE RADIOLOGIE EXPÉRIMENTALE HOPITAL CARDIOLOGIQUE F-69394 LYON
FRANCE

EFFECTS OF CONTRAST MEDIA ON CIRCULATING BLOOD VOLUME

A comparative investigation of various sites of injection

R BARBE G KIRKORIAN and M AMIEL

Increased circulating blood volume after injection a contrast medium has been established by ISERI coll (1965) LINDGREN et coll (1968) and AMIEL coll (1977)

This effect has been directly related to the perosmolality of uro angiographic contrast media 1 initiates various corrective mechanisms (wa displacement from extra vascular to vascular ice) It is also possible that the magnitude of such ects could be dependent upon the site of the injec n in particular because of the selective location osmo receptors in the right atrium This theory ght explain the differences in reactions observed er intravenous and intra arterial injectons of con ast media If so it is possible that pretreatment ith atropine could reduce these reactions

Changes in the circulating blood volume as a func on of time have been measured in the dog and the sults are now presented These changes were de rmined in relation to the injection site in relation the specific contrast medium injected and follow g atropine pretreatment

Methods and Materials

Bolus injections (2–3 s) of contrast media (1 ml/kg r injection) were given to mongrel dogs of average eight (10–17 kg) at different sites through indwell g venous or arterial catheters Three injection tes were chosen pulmonary artery ascending oracic aorta and right atrium

The blood volume was measured using $^{99}Tc^{m}$ ibelled serum albumin as tracer The tracer was injected before the contrast medium Serial sampling at 3 6 and 9 min after injection of the tracer was used to plot the disappearance curve of active serum albumin from the vascular bed By extrapolation of this curve back to time 0 initial blood volume can be established Percentage values of changes following contrast medium injection are calculated from initial circulating blood volume by serial sampling up to 10 min

The following protocol was designed for a com parison in 5 dogs for each series of experiments

(1) Changes in blood volume were measured as a function of time after injection of the same amount of iothalamate (1 ml/kg 28 g I/100 ml) at the three sites mentioned

(2) Comparison of blood volume changes with time after injection into right atrium of hypertonic glucose (30 g/100 ml) iothalamate (28 g I/100 ml) ioxaglate (28 g I/100 ml) and metrizamide (28 g I/100 ml)

(3) The effect of atropine (0 04 mg/kg) upon the albumin disappearance curve was analysed after in travenous injection 10 min before the injection of labelled albumin

Then a comparison was made of the influence of atropine pretreatment on iothalamate induced changes

Results

The results are summarized in Tables 1 and 2 When the same contrast medium (iothalamate) was

---

Submitted for publication 10 May 1979

used effects on the blood volume varied according to the site of injection Response to injection into the right atrium was greater than those to injection into the pulmonary artery or thoracic aorta Injections into the two last mentioned sites caused a similar response (Table 1)

Similar changes occurred after the contrast media tested and glucose (30 g/100 g) of the same osmolality (Table 3) Metrizamide and ioxaglate caused changes one third as great as those after iothalamate

The serum albumin disappearance curve was modified after atropine injection the slope being steeper At 10 min 7 per cent of serum albumin had disappeared before and 10 per cent after atropine injection Thus transfer of labelled albumin from the vascular bed seemed to be facilitated after atropine injection This effect could also explain the smaller effect of iothalamate on the circulating blood volume in atropine pretreated animals

Table 1

Changes (in per cent) in circulating blood volume with time injection of the same dose of iothalamate at different s

Injection site	1 min	2 min	3 min	10 m
Pulmonary artery	2±1	5±?	7±?	11
Thoracic aorta	2±2	4±2	6±?	8
Right atrium	4±1	7±?	11±3	13

Table 2

Increase (in per cent) in circulating blood volume with time injection of ioxaglate (1 ml/kg)

Injection site	1 min	2 min	3 min	10 m
Pulmonary artery	NS	NS	NS	?+?
Thoracic aorta	NS	NS	NS	NS
Right atrium	NS	?±1	3±1	5+?

Table 3

Changes (in per cent) in circulating blood volume after inj of 1 ml/kg contrast medium into right atrium

	1 min	? min	3 min	10
Iothalamate	5±1	7±2	10±3	13
Metrizamide	NS	NS	3±1	5
Ioxaglate	NS	2±1	3±1	5+
Glucose 30%	NS	NS	?±1	4

Discussion

These findings which show a difference in blood volume changes after right atrial injection compared with those following injection into the pulmonary artery or the thoracic aorta are consistent with recorded clinical experience that injections of contrast medium before the right atrium are more often associated with complications than are intra arterial injections

The blood volume changes can be directly related to osmolality and also to the way the hyperosmolar bolus reaches the osmo receptors in the right atrium which are partially responsible for regulating the body s water balance

The blood volume changes at steady state 10 min after injection are in agreement with those reported previously (ISERI et coll) The changes in the present experiments are smaller than those previously found (AMIEL et coll) in those experiments larger amounts of contrast medium (3 ml/kg) were used

Facilitation of exchange between the extra vascular and intra vascular compartments may explain the moderation of contrast media induced changes in circulating blood volume as a result of atropine pretreatment

Finally the comparison of ionic and non ionic media shows that changes in circulating blood volume are the same with products of similar osmolality

Fewer unwanted effects in particular cardiovascular responses can be expected from the new products of lower osmolality as their injection is associated with a smaller increase of the circulating blood volume

SUMMARY

Changes in the circulating blood volume following injection of different contrast media and at different sites have been measured in the dog The results confirm that osmoreceptors in the right atrium play a role for changes in blood volume following injection of a contrast medium The differential response to individual agents was mainly a function of their osmolality Atropine appears to moderate the changes

REFERENCES

AMIEL M BARBE R and DUC R Effect of meglucamine salts of iocarmic and iothalamic

on hemodynamics acid base equilibrium and coagulation Acta radiol Diagnosis 18 (1977) 602
IESINGER G C SCHAFFER J CRILEY J M GAERTNER R A and ROSS R S Hemodynamic consequences of the injection of radio opaque material Circulation 31 (1965) 730
RI L T KAPLAN M A EVANS M J and NICKEL E D Effect of concentrated contrast media during angiography on plasma volume and plasma osmolality Amer Heart J 69 (1965) 154
WHOUSE J H Fluid compartment distribution of intravenous iothalamate in the dog Invest Radiol 12 (1977) 364
LINDGREN P SALTZMAN G F and TORNELL G Vascular reaction to water soluble contrast media Acta radiol Diagnosis 7 (1968) 152
NUSYNOWITZ M L STRAW J D BENEDOTTO A R and DIXON R S Blood clearance rates of technetium 99m albumin preparations concise communication J nucl Med 19 (1978) 1142
THOREN P N DONALD D E and SHEPHERD J T Role of heart and lung receptors with nonmedullated vagal afferents in circulatory control Circulat Res 38 (1976) Suppl No 2 p 2

ROM THE DEPARTMENTS OF DIAGNOSTIC RADIOLOGY NEPHROLOGY AND UROLOGY SAHLGRENSKA SJUKHUSET S-41345 GOTHENBURG SWEDEN

DIURETIC UROGRAPHY IN THE ASSESSMENT OF OBSTRUCTION OF THE PELVI-URETERIC JUNCTION

A E NILSON M AURELL C G BRATT and S NILSSON

The presence of an obstruction at the pelvi eteric junction in patients with wide renal pelves is fficult to evaluate particularly in patients with ıly mild symptoms Thus routine urography pro des a static anatomic assessment of a truly func onal condition and isotope nephrography gives un liable information when the tracer is retained in a rge collecting system If the parenchymal function reduced the isotope excretion might be consid ed as an impairment to flow Evaluation of per stent distension following pyeloplasty is also dif ult on the basis of these examinations

Attempts have been made to improve the radio raphic assessment by copious fluid intake after in ction of the contrast medium (HANLEY 1960) or by ie combination of hydration with a large dose of ontrast medium and with diuretics (diuretic uro- raphy KENDALL & KARAFIN 1968 SAXTON 1969) erfusion examinations in order to measure pressure nd flow across the possible obstruction site may be iseful (WHITAKER 1973) but require percutaneous uncture of the pelvis and are not always successful

For several years a modification of the diuretic irography has been used at this hospital to distin uish between wide renal pelves with or without obstruction (BRATT et coll 1978) The methods used and the results obtained are described in detail in he present report

Material and Methods

Twenty adults with urographic evidence of unilat ral moderately wide renal pelves were examined Fifteen patients (mean age 32 years range 20–55) were operated upon because of one or several of the following symptoms upper urinary tract infection (3 patients) hematuria (6) lumbar pain (10) or renal calculi (3 patients) Five patients (mean age 42 years range 25–60) without complications or severe symptoms were not operated upon Repeat exami nations were performed between one and 2 years after operation or after the first examination when not operated upon

Routine urography was performed mainly in ac cordance with the principles described by OLSSON (1973) which includes restriction of fluid intake The examination included a film exposed with the patient in the supine position about 15 min after the injec tion of contrast medium and after release of the ureteral compression

Diuretic urography was performed on the basis of instructions to the patient similar to those in routine urography except that a normal fluid intake was allowed Full size films were exposed with the pa tient in the supine position Ureteral compression was not applied A solution of meglumine metrizoate (Isopaque Cerebral 280 mg I/ml Nyegaard Nor way) was used as contrast medium Two separate doses were given intravenously Immediately after the first contrast dose (0 5 ml/kg b w) the patient was allowed to walk around for one hour Thirty min following the injection oral fluid (water or juice 10 ml/kg b w) was given followed by a second injec tion of contrast medium (1 0 ml/kg b w) 30 min later At the same time an intravenous infusion of 2 5 ml/kg b w of Mannitol solution (150 mg/ml

Submitted for publication 27 September 1979



a



b

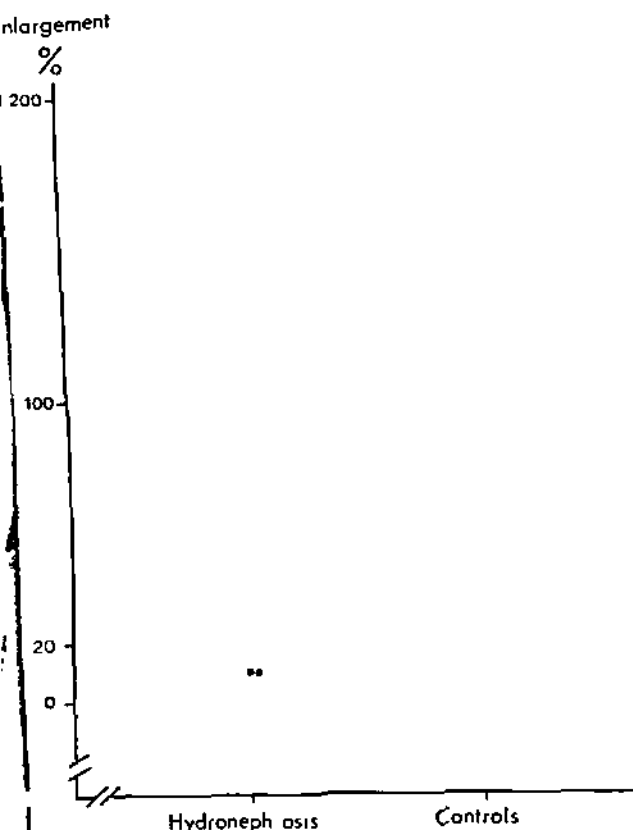


c



d

Fig 1 a) Preoperative routine and b) diuretic urography c) Postoperative routine and d) diuretic urography The funnel-shaped pelvi ureteric junction after surgery and the d[illegible] calyceal distension at diuretic urography are evident



ig Comparison between planimetry values from routine and uretic urography in 20 wide and 10 control pelves The calyceal stension at diuretic urography is given in per cent of the area on utine urography Thus the planimetric value on routine film is 00 per cent

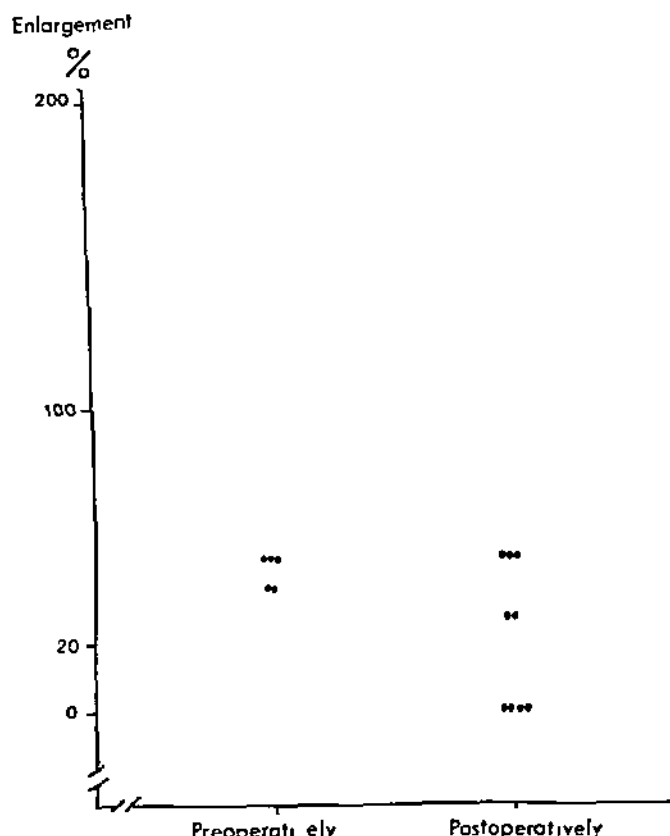


Fig 3 Comparison between pre and postoperative calyceal dis tension at diuretic urography in 15 patients

CO Sweden) was started and completed during the following 15 min A film was then exposed with he patient in the supine position

Planimetry A standard planimetric method hich could be used also after resection of the pel is was applied The planimetry did not include the whole collecting system only one or two upper major calyces completely filled with contrast medium and distinctly outlined on the 15 min film both at the routine and the diuretic urography (Fig 1) The area of the calyces was measured with a compensating planimeter (Ingut No 9529 11) Three measurements were made on each film the average value being used for calculations

In all patients planimetry was carried out on the kidney with the wide pelvis As controls a corre sponding measurement was performed also on the contralateral side in 10 patients

The calyceal enlargement during diuretic uro graphy was given in per cent of the corresponding planimetric area measured from the routine uro- graphy film

Results

On routine urography unilaterally wide renal pelves were present in all patients The shape of the calyces varied but the fornices could always be iden tified On the contralateral side the pelvis was fun nel shaped and the calyces had normal appearances in all patients

On diuretic urography a distension of the pelvi calyceal system occurred in all kidneys measured In 13 kidneys with wide pelves the calyceal area on the film was enlarged by 20 per cent or more (Fig 2) These patients were operated upon The calyces of the remaining 7 kidneys with wide pelves and the calyces of the 10 contralateral control kidneys were distended less than 20 per cent Two of these 7 patients were operated upon because of renal cal culi

The degree of calyceal distension at diuretic uro- graphy before and after pyeloplasty according to ANDERSON & HYNES (1949) appears in Fig 3 After surgery the distension diminished in 9 patients indi cating an improved emptying capacity (Fig 1) In 4

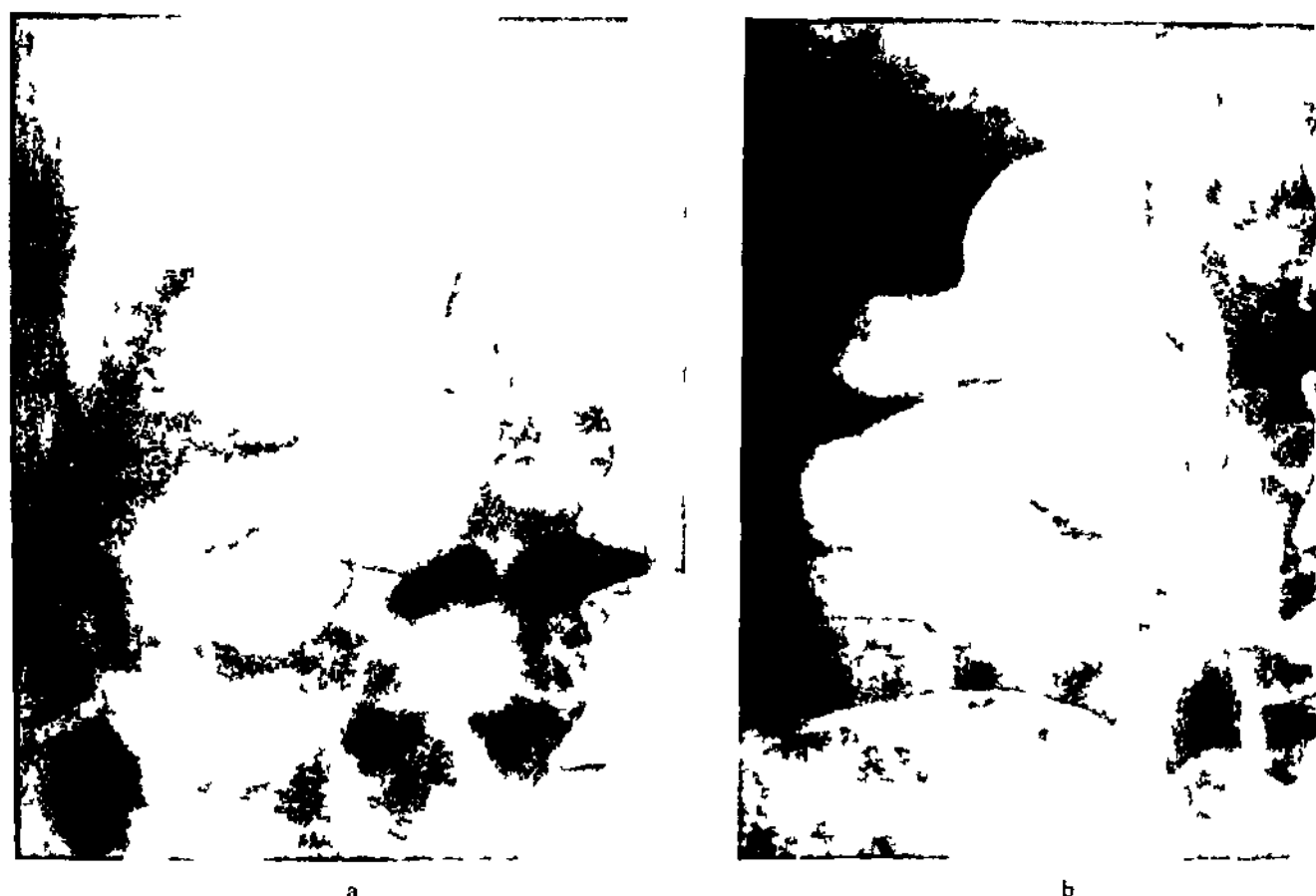


Fig 4 a) Pre and b) postoperative diuretic urography The distension of the calyceal system at forced diuresis increased after surgery

patients the calyces remained unchanged In 2 patients with postoperative complications and local pains the degree of widening increased after the operation which indicated persistent obstruction (Fig 4)

In 2 of 5 kidneys not operated upon the distension remained unchanged and did not reach 20 per cent In 3 patients repeated diuretic urographies showed an increase in the calyceal distension from initially below 20 per cent to 55 80 and 100 per cent respectively They were later operated upon

Diuretic urography provided good information on the postoperative anatomy of the pelvi ureteric region in particular its ability to distend at forced diuresis (Fig 1 d)

The patients in the present series did not complain of pain or discomfort during or after the diuretic urography this applied also to those with lumbar pain

Discussion

While it is quite clear that the response of the renal pelvis to obstruction is dilatation it is equally true that some wide pelves are not due to obstructio these cases no surgery is needed Routine graphy gives information on the anatomy of the vi calyceal system and to some extent on capacity of the urinary tract to receive and disch urine Generally routine urography gives suffic information about the presence of obstruction advanced cases of hydronephrosis However u graphy is in many departments preceded by a m erate restriction of fluid intake and therefore reduced diuresis during urography may not give r able information on the ability of the pelvi urete junction to allow passage of urine during norm episodes of increased diuresis The shape of t renal pelvis varies greatly and thus it may be d ficult on the basis of routine urography to dist guish between a moderate hydronephrosis secon ary to obstruction and kidneys with a wide collec ing system representing a normal anatomic var tion In such cases it might also be difficult to asse accurately the degree of obstruction by means routine urography and hence make a logical deci as to treatment

The density (specific gravity) of the contrast medium excreted during urography is higher than that of urine This may give rise to layer formation (RIBBING 1933 1935 ETTINGER 1943) especially in wide segments of the urinary tract which may result in an underestimation of the size and erroneous evaluation of the shape of the pelvis due to incomplete contrast filling As the patients were examined in the supine position the cranial calyces were most declivous and therefore first and most completely filled by the contrast medium This was the main reason why the cranial calyces were chosen for the planimetric measurements

In the diuretic urography investigation the contrast medium was given in two separate doses The first dose combined with the subsequent up right position was intended to facilitate the escape of urine before the diuretic provocation test This sequence of the procedure seems to be of decisive importance in achieving a high technical quality of the diuretic urography films which qualified for planimetry

In 10 control kidneys the distension at diuretic urography did not exceed 20 per cent In 13 of the 20 cases of moderately wide renal pelves a widening of more than 20 per cent occurred which might reflect an obstruction to flow In the remaining 7 kidneys the distension was of the same magnitude as in the controls indicating a sufficient drainage capacity even during forced diuresis Thus diuretic urography may be useful in differentiating patients with moderately wide renal pelves and obstruction Reduced distension at forced diuresis after surgery indicates improved emptying facilities while unchanged or increased distension may indicate operative failure

Diuretic urography can be used if the parenchymal function is moderately reduced a situation in which determination of isotope excretion by isotope nephrography occasionally incorrectly is considered as suggesting impairment to flow (WHITFIELD et coll 1977 BRATT et coll) Furthermore diuretic urography provided information on the functional pelvi calyceal anatomy which might be difficult to evaluate on the basis of routine urography

In agreement with WHITFIELD et coll diuretic urography was found to be a useful method in the assessment of obstruction at the pelvi ureteric junction Using divided large contrast medium doses the concentration was sufficiently high and the filling complete enough to allow delineation of the collecting system Diuretic urography is not invasive and does not involve a percutaneous puncture of the renal pelvis The examination is convenient to the patient and can be used repeatedly

SUMMARY

Twenty adult patients with urographic evidence of unilateral moderately wide renal pelves were examined by routine and diuretic urography Planimetry of the corresponding calyx system of the two examinations was performed An increase in size by more than 20 per cent following osmotic diuresis indicated an obstruction of the pelvi ureteric junction in kidneys with moderately wide renal pelves Diuretic urography may be useful to diagnose obstruction as a cause of moderately wide renal pelves and to assess operative results

REFERENCES

ANDERSON J C and HYNES W Retrocaval ureter A case diagnosed preoperatively and treated successfully by a plastic operation Brit J Urol 21 (1949) 209

BRATT C G AURELL M NILSON A E and NILSSON S Diuretic urography and renography in the diagnosis of hydronephrosis Contr Nephrol 11 (1978) 142

COVINGTON T Jr and REESER W Hydronephrosis associated with overhydration J Urol (Baltimore) 63 (1950) 430

ETTINGER A Layer formation in pyelography Amer J Roentgenol 49 (1943) 783

HANLEY H G Hydronephrosis Lancet 24 (1960) 664

KENDALL A R and KARAFIN L Intermittent hydronephrosis Hydration pyelography J Urol (Baltimore) 96 (1968) 653

OLSSON O Roentgen diagnosis of the urogenital system *In* Encyclopedia of Medical Radiology vol XIII/1 p 42 Edited by L Diethelm F Heuck O Olsson K Ranniger F Strnad H Vieten and A Zuppinger Springer Verlag Berlin Heidelberg New York 1973

RIBBING S Une source d erreurs negligee dans l interpretation des pyelographies Acta radiol 14 (1933) 545

— La stratification des liquides dans l urographie Acta radiol 16 (1935) 716

SAXTON N G Urography Brit J Radiol 42 (1969) 321

WHITAKER R H Methods of assessing obstruction in dilated ureters Brit J Urol 45 (1973) 15

WHITFIELD H N BRITTON K E KELSEY FRY I HENDRY W F NIMMON C C TRAVERS P and WICKHAM J E A The obstructed kidney Correlation between renal function and urodynamic assessment Brit J Urol 49 (1977) 615

OM THE DEPARTMENTS OF DIAGNOSTIC RADIOLOGY RIKSHOSPITALET UNIVERSITY HOSPITAL AND THE NORWEGIAN RADIUM HOSPITAL OSLO NORWAY

COMPUTER TOMOGRAPHY LYMPHOGRAPHY AND PHLEBOGRAPHY IN METASTASES FROM TESTICULAR TUMORS

H H LIEN A KOLBENSTVEDT F KOLMANNSKOG
K LIVERUD and T AAKHUS

Lymphography from the foot and cavography lowed by urography have been advocated for monstration of retroperitoneal metastases from ticular tumors (BAUM et coll 1963 MAHAFFY 64 HOPF & FUCHS 1970 ENGESET & LIVERUD 71 MASSELOT et coll 1971) The value of retro de phlebography of the renal and left testic r veins was demonstrated by LIEN & KOLBENS EDT (1976) LIEN et coll recommended ante ade phlebography of the testicular vein during chidectomy Funicular lymphography can some nes give valuable information (BUSCH et coll 1965 HAPPA et coll 1966 SAYEGH et coll 1966 ULTÉN et coll 1973) but is more time consuming an antegrade phlebography (LIEN et coll)

Computer tomography is a non invasive tech que that may be used for demonstrating the troperitoneal lymph nodes The absence of dis rbing organ motion provides favourable conditions r the demonstration of the structures in the re operitoneal space (STEPHENS et coll 1977)

The purpose of the present report is to compare e ability of CT lymphography and phlebography r demonstration of retroperitoneal metastases om testicular tumors

Material

The series consisted of 50 patients admitted for alignant testicular tumor usually short after or chidectomy in whom CT of the retroperitoneal space as well as lymphography and phlebography were carried out

Thirty one patients were aged between 20 and 39 years 15 between 40 and 59 and 4 patients were more than 60 years old The primary tumor (23 seminomas 27 other malignant tumors) was located in the right testis in 22 and in the left in 28

Methods

Lymphography from the foot was carried out as described by KOLBENSTVEDT & KNUDSEN (1974) and phlebography of the inferior vena cava left re nal and left testicular veins as described by LIEN & KOLBENSTVEDT Urography was routinely per formed after the phlebography In 2 patients phlebography of the left renal and testicular veins was not performed because of extensive abnormali ty of the vena cava Four patients in whom orchidec tomy had not been performed before admission were also examined by funicular lymphography and an tegrade phlebography of the testicular vein Usually lymphography and phlebography were carried out first CT being performed within 2 weeks

A Delta Scan 50 FS with a scan time of 18 seconds and a 256×256 matrix display was employed for CT Oral contrast medium (400 ml Gastrografin 18 mg

Submitted for publication 28 August 1979

Table

Distribution of metastases in 19 patients at different examinations

Examination	Region				Total No of patients with demonstrated metastases
	Thoraco-lumbar	Upper lumbar	Lower lumbar	Iliac	
Lymphography	1	6	15	–	15
Phlebography	1	10	16	1	17
Lymphography and phlebography	2	11	18	1	18
Computer tomography	7	13	19*	–	19*
All examinations combined	7	13	19	1	19

Metastases detected only after revision in 3 patients

l/ml) was given 45 min before the examination and a spasmolytic drug (Buscopan 40 mg) intravenously immediately before the examination At each scanning sequence 2 adjacent tissue sections were reconstructed each representing a tissue thickness of 13 mm The distance between corresponding parts of 2 double sections was 40 mm thus leaving interspaces of 14 mm between the double sections

The retroperitoneal space was divided into 4 parts (Table) At CT the prevertebral retrocrural region at the level of the laminar portions of the crura i e where their fibers decussate anterior to the aorta was considered as the thoracolumbar junction (CALLEN et coll 1978) The entry of the left renal vein into the inferior vena cava could be identified at both CT and phlebography Therefore a horizontal line through this junction was chosen as a borderline dividing the lumbar region into an upper and a lower compartment Metastases below the promontory were considered to have an iliac localization

Retroperitoneal surgery was performed in only 7 patients thus microscopic confirmation was as a rule not available An assessment of pathologic lymphographic findings was obtained by repeat survey radiography of the abdominal nodes containing contrast medium in all patients Abnormal findings were encountered at CT in 19 patients and repeat CT was performed in 12 of these Regression of a mass following treatment or gradual progression in spite of treatment were both considered suggestive of metastases

Results

Radiologic evidence of retroperitoneal metastases was found in 19 of the 50 patients (Table) All 19 patients had abnormalities visible in one o regions at CT while the combination of l graphy and phlebography supplemented w graphy revealed tumor growth in 18

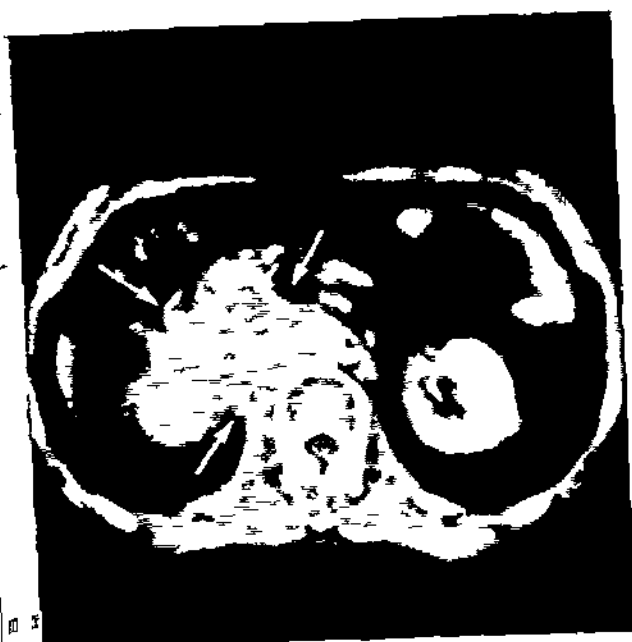
In the iliac region phlebography demonstr clusion of the left external and both veins in one patient (Fig 1) while lymp and CT revealed no abnormalities

In the lower lumbar region metastase demonstrated at CT in all 19 patients (Figs 1 In one of these (Fig 2) CT was the only exa indicating tumor growth while in the rema patients metastases were also demonstrated phography and phlebography Lymphograph showed metastases in 15 patients phlebo 16

In the upper lumbar region CT disclosed tases in 13 patients while the combined use phography and phlebography showed 11 of these Lymphography alone revealed tases in 6 patients phlebography in 10 (Fig 6

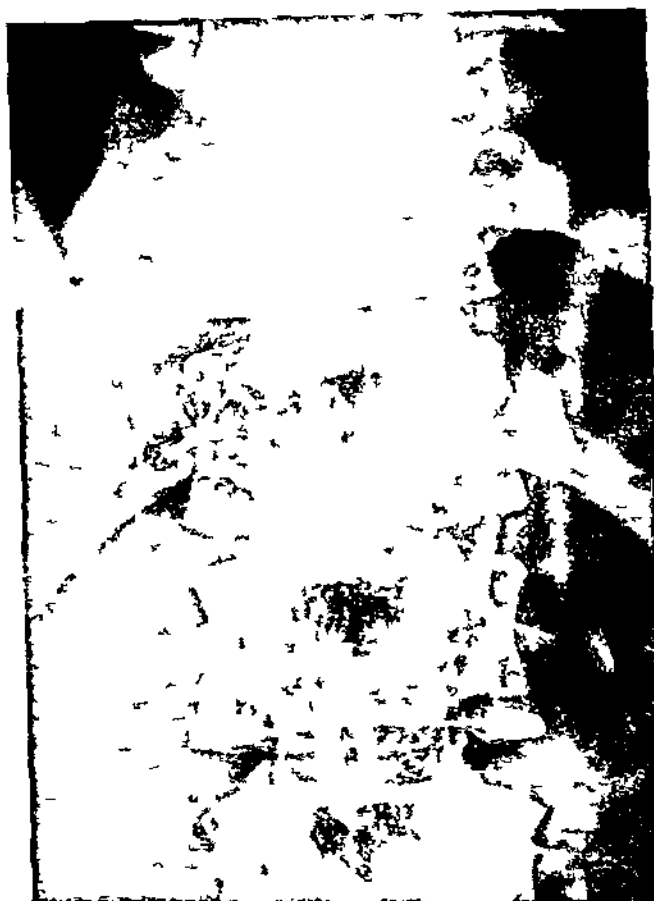
In the thoracolumbar region metastatic were demonstrated at CT in 7 patients (Figs while lymphography and phlebography metastases in 2 of these only Lymphography showed metastases by displacement of the cis chyli in one patient and phlebography reveale clusion of the inferior vena cava in another latter patient also had a bulging of the paraspina tissues most evident on the right side (Fig A widening of the paraspinal soft tissues was observed in a further patient on a survey film o thoracolumbar region

Necrosis within the metastatic mass was de strated by CT in 8 patients (Figs 1a 3 6a)









1 Seminoma of right testis a) CT of lower lumbar region lowing injection of contrast medium Expanding lesion on right e (→) Inferior vena cava right kidney or aorta not distinshable Cavitation in ventral part b) CT at level of diaphragtic crura Lateral bulge of right crus due to cranial extension of tumor (→) c) Phlebography of inferior vena cava Occlusion of vena cava both common iliac and left external iliac veins Collateral filling of ascending lumbar veins (→) and superficial vein on anterior abdominal wall (→) d) Thoracolumbar junction The paraspinal soft tissue thickened most evident on right side



Fig 2

Fig 3



Fig 4a



Fig 4b



Fig 4c

Fig 2 Seminoma of left testis CT slightly below renal hila Metastatic mass on left side (→) confirmed by regression following treatment Contrast filled lymph nodes anterior to the spine Lymphography and phlebography were normal

Fig 3 Embryonal carcinoma of right testis CT of lower lumbar region Retroperitoneal tumor with low attenuation (→) anterior to left psoas muscle

Fig 4 Same case as in Fig 3 a) Lymphangiography Dis[illegible] ment of lymph vessels indicating tumor growth b c) P[illegible] graphy of left testicular vein Slight lateral displacement [illegible] marked anterior displacement (→) in (c)

in 7 of these the attenuation values were below 20 Hounsfield units

Discussion

The results confirm the view that CT is useful in revealing retroperitoneal metastases from testicular tumors (KREEL 1977 MARSHALL et coll 19[illegible] SCHANER et coll 1977 STEPHENS et coll 19[illegible] POUR et coll 1978 MARCHAL et coll 1978 L[illegible] coll 1979)

The assessment of metastases at CT was base[illegible] findings such as lymph node enlargement (Fig[illegible] masses of confluent nodes (Fig 5a) with di[illegible]

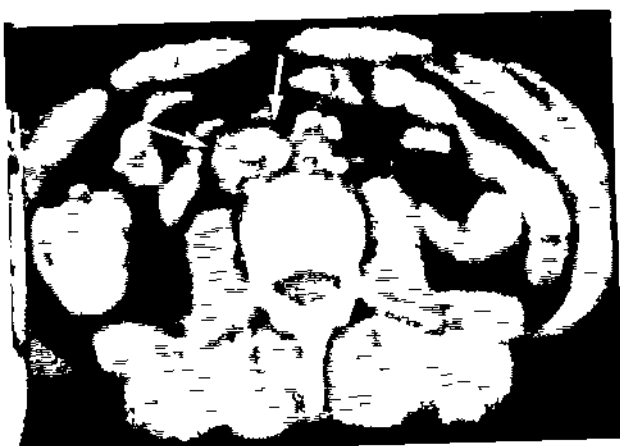


Fig 5a



Fig 5b



Fig 5c

5 Seminoma of right testis a) CT below the kidneys Partial lled lymph nodes in a metastatic mass (→) not distinguishable 1 inferior vena cava b) Lymphography from the foot Right oblique projection Filling defects in enlarged nodes (→) cating metastases c) Phlebography of inferior vena cava ressions in anterior aspect due to metastatic nodes



Fig 6a



Fig 6b

6 Teratoma of left testis a) CT slightly above renal hila rge metastatic mass with varying attenuation on both sides of lline Great vessels not di tinguishable Forward displacement superior mesenteric artery (→) b) Phlebography of inferior na cava Displacement to right and impression of left margin

nt of vessels (Fig 6a) and contrast filled bowel Fig 8) indistinguishable aorta and vena cava due to vasion of surrounding fat (Figs 1a 6a) or the esence of masses at unusual sites e g posterior to e pancreas or in the prevertebral retrocrural region Fig 1b) The nodes considered as metastatic were finitely larger than the limits set by REDMAN et coll (1977) (1 5–2 0 cm) and MARCHAL et coll (1 5 cm)

Occlusion of the left external and both common iliac veins was the only abnormality in the iliac region (Fig 1) It was not possible to decide whether it was due to tumor growth alone or to a clot secondary to a tumor



Fig 7 Embryonal carcinoma of left testis CT of thoracolumbar region Enlarged retroaortic node considered as metastasis (→) and slight bulging of left crus Lymphography and phlebography demonstrated lumbar metastases but the soft tissues at the thoracolumbar junction appeared normal




Fig 8 Teratoma of left testis CT below the kidneys M mass (→) lateral to the aorta with displacement of conti bowel

In the lower lumbar region the advantage of CT compared with lymphography and phlebography was evident in only one patient (Fig 2) In 3 of the 19 patients with metastases demonstrated in this region CT was initially considered as normal The abnormality was not observed until revision was undertaken after other procedures had clearly indicated tumor growth In 2 patients with small metastases the abnormalities were best demonstrated by lymphography (Fig 5) and in one the metastasis was detected by antegrade testicular vein phlebography during orchidectomy (LIEN et coll) Due to its low attenuation it was initially considered as a renal cyst at CT

One of the limitations of lymphography from the foot is that the upper lumbar nodes are insufficiently demonstrated (SCHWARZ et coll 1965 FUCHS & PFAMMATTER 1970 SIEBER & WIEDEMANN 1976 STEPHENS et coll ZAUNBAUER et coll 1977) especially on the right side (FUCHS 1969) Thus in a normal series consisting of 126 patients JACKSON (1974) reported filling of lymph nodes at the level of L1 in 25 per cent on the right side and in 50 per cent on the left Besides in many cases with metastases only the lower extension of the tumor is visible due to obstruction of the lymph flow In order to overcome these limitations BAUM et coll MAHAFFY HOPF & FUCHS ENGESET & LIVERUD MASSELOT et coll *and* DE ROO *(1974) recommended* cavography and urography as supplementary examinations while LIEN & KOLBENSTVEDT reported ad phlebography of the left renal and left te veins to be valuable for demonstration of upp bar metastases from testicular tumors The results indicate that CT is still more useful

In the thoracolumbar region CT was eve superior (Fig 7) though the paraspinal soft as demonstrated on conventional films m valuable information (Fig 1 d)

The main advantage of CT thus was its s ability to demonstrate tumor growth in the part of the retroperitoneal space which is in ment with previous reports (KREEL REDM coll STEPHENS et coll LEE et coll 1978 CHAL et coll)

CT was performed by SCHANER et coll patients with malignant testicular tumor and c cavitation was found in 6 of the 11 patients metastases However no mention was made o croscopy Necrotic areas in a metastatic mass also reported by MARCHAL et coll Good correl was found between CT and serum tumor marke JAVADPOUR et coll in 4 patients with meta from testicular tumors One patient with tera and another with choriocarcinoma had areas of attenuation due to necrosis while in a third pa metastases from a teratoma underwent cystic generation after chemotherapy *Only one p with seminoma and questionable teratomatous* ments had no cavitation visible

Of the present 7 patients with attenuation values below 20 HU 2 had seminoma while 5 had other malignant tumors

Details of veins were best demonstrated by phlebography (Figs 1 4 5 6) STEELE et coll (1978) and KOLBENSTVEDT et coll (1979) reported thrombosis of the inferior vena cava demonstrated at CT the former emphasized the importance of intravenous administration of contrast medium In the present patient with occlusion of the inferior vena cava (Fig 1) neither CT before nor after administration of contrast medium could distinguish the vein from the metastatic mass In this respect CT gave less information than phlebography of the inferior vena cava In addition collateral veins were demonstrated at phlebography (Fig 1c) which were not observed at CT

Although small metastases are best demonstrated by lymphography and phlebography is necessary for demonstrating details of the veins and development of collaterals CT is undoubtedly an important tool for the examination of the retroperitoneal space The ease and quickness with which it is carried out and the minimum discomfort for the patient make this procedure well suited for frequent use CT usually demonstrated the metastatic masses more directly than lymphography and phlebography (Figs 1 3 4 6) and was thereby useful also as a guide in planning the extent of irradiation

CT should be the first procedure to be performed in the examination of the retroperitoneal space in patients who have undergone orchidectomy for malignant tumor Definite directions for the use of lymphography cavography and retrograde phlebography of the left renal and testicular veins cannot be given for the time being However it seems reasonable to suggest that these procedures should be restricted to patients in whom CT is normal or uncertain Phlebography will still be necessary when details concerning the veins are desirable e g in possible occlusion or when CT shows a questionable mass near the inferior vena cava

Conclusion

CT was useful in the examination of retroperitoneal metastases from testicular tumors and should be performed as a first procedure after orchidectomy It demonstrates tumor growth directly and is of particular value in the upper part of the retroperitoneal space Small metastases were best demonstrated by lymphography and phlebography was necessary for demonstrating details of the veins and collateral circulation Therefore CT has not yet completely replaced the other examinations A larger number of patients is needed before definite directions for the use of the other examinations can be given even though it seems probable that they will be restricted to patients in whom CT is normal or uncertain

SUMMARY

Fifty patients with testicular tumor were subjected to computer tomography lymphography cavography and retrograde phlebography of the left renal and testicular veins followed by urography The yield of computer tomography in detecting metastases of the iliac lumbar and thoracolumbar regions was compared with that of the other examinations and was particularly high in the upper part of the retroperitoneal space

REFERENCES

BAUM S BRON K M WEXLER L and ABRAMS H L Lymphangiography cavography and urography Comparative accuracy in the diagnosis of pelvic and abdominal metastases Radiology 81 (1963) 207

BUSCH F M SAYEGH E S and CHENAULT JR O W Some uses of lymphangiography in the management of testicular tumors J Urol (Baltimore) 93 (1965) 490

CALLEN P W FILLY R A and KOROBKIN M Computed tomographic evaluation of the diaphragmatic crura Radiology 126 (1978) 413

CHIAPPA S USLENGHI C BONADONNA G MARANO P and RAVASI G Combined testicular and foot lymphangiography in testicular carcinomas Surg Gynec Obstet 123 (1966) 10

ENGESET A og LIVERUD K Lymfografi (In Norwegian) Med Årb 14 (1971) 55

FUCHS W A Normal anatomy *In* Lymphography in cancer Chapter 5 p 42 Edited by W A Fuchs J W Davidson and H W Fischer Springer Verlag Berlin Heidelberg New York 1969

— und PFAMMATTER T Die topographische Rontgenanatomie der inguinalen und retroperitonealen Lymphknoten Radiologe 10 (1970) 262

HOPF M A und FUCHS W A Die Lymphographie Cavographie und Urographie als Kombinationsuntersuchung Radiologe 10 (1970) 280

HULTEN L KINDBLOM L G LINDHAGEN J ROSENCRANTZ M SEEMAN T and WAHLQVIST L Funicular and pedal lymphography in testicular tumors Acta chir scand 139 (1973) 746

JACKSON B T The lumbar lymphatics A lymphographic study Ann roy Coll Surg Engl 54 (1974) 3

JAVADPOUR N DOPPMAN J L BERGMAN S M and ANDERSON T Correlation of computed tomography and serum tumor markers in metastatic retroperitoneal

testicular tumor J Computer Ass Tomogr 2 (1978) 176

KOLBENSTVEDT A and KNUDSEN O A method for lymphographic and histologic correlation Experience from 300 patients treated by pelvic lymphadenectomy Gynec Oncol 2 (1974) 9

— KOLMANNSKOG F and AAKHUS T Venous structures of the chest and abdomen at computer tomography Acta radiol Diagnosis 20 (1979) 513

KREEL L Computerized tomography using the EMI general purpose scanner Brit J Radiol 50 (1977) 2

LEE J K T STANLEY R J SAGEL S S and LEVITT R G Accuracy of computed tomography in detecting intraabdominal and pelvic adenopathy in lymphoma Amer J Roentgenol 131 (1978) 311

— MCCLENNAN B L STANLEY R J and SAGEL S S Computed tomography in the staging of testicular neoplasms Radiology 130 (1979) 387

LIEN H H and KOLBENSTVEDT A Venography of the left renal and left gonadal veins as a supplement to lymphography Report of four cases Lymphology 9 (1976) 23

— — MILLER A and BAKKE S J Antegrade testicular vein phlebography and funicular lymphography in testicular tumors Acta radiol Diagnosis 21 (1980) 603

MAHAFFY R G A comparison of the diagnostic accuracy of lymphography cavography and pelvic venography Brit J Radiol 37 (1964) 422

MARCHAL G COENEN Y WILMS G and BAERT A L The accuracy of TC scan in the diagnosis of retroperitoneal metastases of malignant testicular tumors Fortschr Rontgenstr 128 (1978) 746

MARSHALL JR W H BREIMAN R S HARELL G S GLATSTEIN E and KAPLAN H S Computed tomography of abdominal paraaortic lymph node disease Preliminary observations with a 6 second scanner Amer J Roentgenol 128 (1977) 759

MASSELOT J BERGIRON C et MARKOVITS P Valeurs comparées de la lymphographie de la cavographie et de l urographie intraveineuse dans l étude de[...] tases ganglionnaires (retropéritoneales) des canc[...] testicule À propos de 60 cas J Radiol Electr[...] (1971) 653

REDMAN H C GLATSTEIN E CASTELLINO R A [...] FEDERAL W A Computed tomography as an a[...] in the staging of Hodgkin s disease and non Hod[...] lymphomas Radiology 124 (1977) 381

DE ROO T Additional examinations in lymphograp[...] radiological surgical pathological correlation [...] phology 7 (1974) 45

SAYEGH E BROOKS T SACHER E and BUSCH F [...] phangiography of the retroperitoneal lymph [...] through the inguinal route J Urol (Baltimo[...] (1966) 102

SCHANER E G HEAD G L KALMAN M A D[...] N R and DOPPMAN J L Whole body compu[...] mography in the diagnosis of abdominal and th[...] malignancy Review of 600 cases Cancer Treat [...] 61 (1977) 1537

SCHWARZ G LEE B J and NELSON J H L[...] graphy cavography and urography in the evalua[...] *malignant lymphomas* A study of 100 con[...] lymphoma cases Acta radiol Diagnosis 3 (1965[...]

SIEBER F und WIEDEMANN F H Rontgenana[...] Fusslymphographie *In* Lymphographie bei m[...] Tumoren Kapitel 7 S 51 Herausgegeben v[...] Luning M Wiljasalo und H Weissleder [...] Thieme Leipzig 1976

STEELE J R SONES P J and HEFFNER JR L T[...] detection of inferior vena caval thrombosis wit[...] puted tomography Radiology 128 (1978) 385

STEPHENS D H WILLIAMSON JR B SHEEDY P F[...] TERY R R and MILLER W E Computed tomog[...] of the retroperitoneal space Radiol Clin N Am[...] (1977) 377

ZAUNBAUER W KUNZ R und LEUTHI R Die diag[...] sche Zuverlassigkeit der Lymphographie bei Pati[...] mit malignen Hodentumoren Fortschr Rontg[...] 126 (1977) 335

FROM THE DEPARTMENT OF DIAGNOSTIC RADIOLOGY (DIRECTOR PROF E BOIJSEN) UNIVERSITY HOSPITAL
S-221 85 LUND SWEDEN

SELECTIVE PHLEBOGRAPHY IN PANCREATIC AND PERIPANCREATIC DISEASE

W REICHARDT

Selective phlebography of the pancreas in vivo was first reported by GOTHLIN et coll (1974) Pancreatic veins were accidentally found available for selective catheterization in cases where portography was performed for examination of the liver Most of these cases were examined using the transumbilical approach to the portal vein Later on when more interest was paid to selective catheterization of portal vein tributaries (LUNDERQUIST & VANG 1974 LUNDERQUIST et coll 1977 1978 HOEVELS et coll 1978 REICHARDT et coll 1979) the percutaneous transhepatic approach was preferred as it facilitated the catheterization procedure Pancreatic phlebography was found to be a useful diagnostic method in carcinoma of the pancreas (REICHARDT et coll 1978) and—combined with blood sampling for hormone assay—in endocrine tumours of the pancreas (INGEMANSSON 1977 LUNDERQUIST et coll 1978)

In recent years several new methods for evaluation of pancreatic morphology such as endoscopic retrograde cholangiopancreaticography (ERCP) ultrasound and computer tomography have been developed and improved These have now with the exception of localization of islet cell tumours replaced angiography as the dominating diagnostic radiologic method in examination of the pancreas

The present report constitutes an analysis of the morphologic abnormalities observed at selective phlebography in patients with pancreatic and peripancreatic disease and a discussion of its clinical value

Anatomy of the pancreatic veins The phlebographic anatomy of the pancreas has been described in detail previously (REICHARDT & CAMERON 1980) and only a short summary is now given

The veins of the pancreas may drain to all the main portal vein tributaries adjacent to the organ The dorsal aspect of the head of the pancreas is mainly drained by one or two posterior superior pancreaticoduodenal veins ending into the portal vein (Fig 1 in REICHARDT & INGEMANSSON 1980) Sometimes also a dorsal pancreatic vein is found emptying into the confluence of the superior mesenteric vein and the splenic vein (in the following text called confluence) The dorsocaudal part is often drained by the posterior inferior pancreaticoduodenal vein to the superior mesenteric vein or to the first jejunal vein

The ventral aspect of the head of the pancreas is drained by the anterior superior pancreaticoduodenal vein which empties into the superior mesenteric vein after having joined the gastrocolic trunk The veins of the ventrocaudal part of the head are collected in the anterior inferior pancreaticoduodenal vein which ends in the superior mesenteric vein or—together with the post inf vein in the first jejunal vein The main veins of the head are connected by collaterals which sometimes run in the ventral and dorsal furrow between the head of the pancreas and the duodenum forming a ventral and a dorsal arcade The body of the pancreas is drained by the transverse pancreatic vein which ends in the inferior mesenteric vein the superior mesenteric vein or the splenic vein Some veins of the body

Submitted for publication 16 August 1979

often run to the left gastric vein The veins of the tail of the pancreas usually drain to the splenic vein

All the mentioned veins of the head of the pancreas and their closest branches towards the duodenum as well as the main part of the transverse pancreatic vein are situated on the surface of the organ The intrapancreatic veins are small and connect the main stems on the surface Veins of the tail and body draining to the splenic vein are mainly intrapancreatic

Material and Methods

Since 6 years selective phlebography of the pancreas was performed in 67 patients (26 women 41 men) with proven disease in the pancreaticoduodenal region The age ranged from 21 to 85 years

In 50 patients the indication for examination was possible malignancy of the pancreas Forty three patients were referred with obstructive jaundice in 2 patients a tumour in the region of the head of the pancreas was found at cholecystectomy and the patients were referred for evaluation of resectability Five patients with chronic pancreatitis were examined because scintigraphy of the pancreas ERCP or ultrasound had suggested malignancy The final diagnoses in this group were carcinoma of the head of the pancreas in 35 patients carcinoma of the extrahepatic bile ducts in 9 chronic pancreatitis in 5 and retropancreatic malignant lymphoma in one patient The diagnoses were confirmed at microscopy in all patients with tumours and by the clinical course during at least 14 months observation in patients with chronic pancreatitis Laparotomy was performed in 2 patients with pancreatitis

In 17 patients the examination was performed for diagnosis and localization of endocrine tumours of the pancreas The final diagnoses in this group were gastrinomas (4 patients) glucagonomas (3) insulinomas (5) islet cell hyperplasia causing hyperglycemia (2) and somatostatinoma (1) In one patient the tumour could not be classified by immunocytochemistry but was classified as D_1 cell tumour at electron microscopy One patient had no islet cell tumour but multiple submucosal lipomas of the duodenum The diagnoses were confirmed at surgery in all patients but one with a Zollinger–Ellison syndrome who refused surgery

The tumour size was defined in situ and in the operative specimen If no resection was performed the size was estimated at laparotomy

Percutaneous transhepatic puncture of the vein was performed with a 25 cm long sheathed with a polyethylene catheter (OD 1 ID 1 0 mm Surgimed Denmark) The pt technique was introduced by WIECHEL (1971) has been described previously (GÖTHLIN e HOEVELS et coll) The pancreatic veins catheterized using a 0 9 mm guide wire with tip and the catheter was pushed over the guide into the vein A detailed description of the te of selective catheterization of the pancreatic given elsewhere (REICHARDT & INGEMANSSO

For examination of the main stems of the vein system and the parenchyma of the liver contrast medium (Isopaque Coronar 370 Nyegaard Norway) was injected at a rate Sixteen films were exposed (5 films/5 s 8 fi films/6 s)

Pancreatic phlebography was performed ual injection of 2 to 10 ml of contrast mediu pending on the size of the vessels—and 8 films/s) were exposed

When the examination was performed onstrate or to rule out a carcinoma of the the pancreas the catheterization was limited area of interest As a rule only one of the m of the head—the ant sup or post sup creaticoduodenal vein—was injected In 5 both the ant sup and post sup veins in 3 post sup vein and the dorsal pancreatic vein one case the ant sup post sup and trans veins were examined

In patients with endocrine tumours cathete tion of the veins of the entire pancreas was aime for blood sampling Only phlebographies of the of the pancreas containing an islet cell tumo hyperplasia will be discussed in the following

Results

Carcinoma of the head of the pancreas In 5 patients with pancreatic carcinoma the phlebographies could not be evaluated due to travasation of contrast medium in 2 patients incomplete filling of pancreatic veins due to adequate position of the catheter in 3 In 4 pa neither the ant sup nor the post sup duodenal veins could be entered with the cath At the expected position of their orifice an irreg



Fig 1a



Fig 1b



Fig 2

Fig 1 Female aged 49 years with a 7 cm non-resectable carcinoma of the head of the pancreas Injection into ant sup pancreaticoduodenal vein a) A p view Occlusion of multiple veins of the head of the pancreas (→) Irregularity of veins in the tumour area (↔) No flow of contrast medium to post sup pancreaticoduodenal vein which probably is occluded b) Lateral view Anterior displacement of sup mesenteric vein near the confluence (↔) Veins posterior to portal vein are occluded (→)

Fig 2 Male aged 50 years with a 5 cm non resectable carcinoma of the head of the pancreas Injection into post sup pancreaticoduodenal vein Occlusion of posterior pancreatic veins (→) No demonstration of main anterior veins




Fig 3 a




Fig 3 b

Fig 3 Male aged 70 years with a non resectable carcinoma of the head of the pancreas a) Injection into sup mesenteric vein Severe stenosis of the confluence with a pressure gradient of 13 cm H O Collateral flow via pancreaticoduodenal veins (→) and veins of the transverse colon (↔) b) Injection into post sup pancreaticoduodenal vein Only filling of the collateral veins on the surface of the pancreas

Fig 4 Male aged 69 years with an islet cell tumour (malignant glucagonoma) of the tail of the pancreas 4 cm in diameter The tail is widened the veins are slightly dilated and displaced The splenic vein is irregular



Fig 4

ty of the vessel wall could be felt when catheteriza tion was tried Laparotomy in these cases revealed irresectable carcinoma 6 to 10 cm in diameter

In 20 patients with carcinoma of the head of the pancreas 4 to 10 cm in diameter stenoses and oc clusion of veins of the head could be demonstrated (Figs 1 2) Widened collateral pancreaticoduodenal veins were found in 6 patients (Fig 3) In all these cases severe encasement of the portal vein system in the region of the confluence was found and the widened pancreaticoduodenal veins were collateral pathways between the superior mesenteric and por tal veins Small pancreatic collaterals were only identified in 2 cases

In one patient small pancreatic veins were prob ably occluded At surgery a tumour 3 cm in diameter was found

Patent pancreatic veins were found in all 5 pa tients with tumours 2 cm (4 cases) and 1 cm (1 c in diameter respectively However abnor veins were demonstrated in 4 of the cases wher tumour was associated with inflammatory lesi or around the head of the pancreas (Table) In patient only pancreatitis with abscess formation found at surgery but at autopsy 4 months later a large carcinoma was found

Islet cell tumours Fourteen patients with islet tumours and 2 patients with islet cell hyperp were examined The tumour size ranged from than 1 to 6 cm A cyst 10 cm in diameter in the ta the pancreas adjacent to an islet cell tumour found in one patient

No phlebographic abnormalities were found in patients with islet cell tumours 2 cm or less in d ter nor in 2 patients with islet cell hypoplasia

Displacement of the veins was observed in f



a



b

5 Male aged 51 years with chronic pancreatitis multiple tic lesions of the pancreatic duct and enlargement of the head the pancreas a) Ectatic parts of the duct and cysts are filled h contrast medium after ERCP b) Injection into post sup pancreaticoduodenal vein Irregular veins partly stretched and displaced by cysts (→) Patent collaterals to ant sup pancreaticoduodenal vein (↔)

nts with islet cell tumours 4 5 and 6 cm in diame respectively and in the patient with the 10 cm cyst In the patient with a 4 cm large malignant ina widened pancreatic veins and an ir ilar splenic vein were demonstrated in addition 4)

Pancreatitis Five patients with chronic pan eatitis in whom the clinical course ERCP ul trasound or pancreatic scintigraphy were sugges tive of a pancreatic carcinoma were examined

The veins were slender and irregular and changed their course abruptly Collaterals between the ant sup and post sup pancreaticoduodenal veins were patent in 4 patients The veins were stretched in regions where ERCP disclosed cysts (Fig 5) In one patient the post sup vein was occluded but small intrapancreatic veins were patent adjacent to the portal vein at the estimated position of this vein (Fig 6) At laparotomy a pseudotumour of the head of the pancreas about 6 cm in diameter was found Multiple fine needle biopsies revealed no carcinoma A shunt between the tail of the pancreas and jejunum was performed and the patient has been well without signs of malignancy 18 months after surgery

Engagement of the confluence was demonstrated in one patient The vessel was irregular and a slight stenosis was present (Fig 7) In one case the splenic vein near the confluence was slightly stenosed In this patient pancreatitis was present in the entire pancreas

Slender veins either stretched or kinked were also demonstrated in 2 patients with carcinoma of the head of the pancreas surrounded by pancreatitis and in one patient with carcinoma of the head of the pancreas and pancreatitis of the body

Peripancreatic disease Nine patients with car


Table

lebographic find ngs in 4 patients with carcinoma of the pan e ? r l cm in diameter associated with inflammatory lesions

ise	Surgery	Phlebography
	Pancreatitis abscess in and around the pancreas A cm tumour found 4 months later	Stretched slender veins No occlusion
	Enlarged head 1 cm tumour Surrounded by pancreatitis	Slender irregular veins abrupt changing their course No occlusion
	Layer of fibrotic tissue on the surface of the pancreas A ? cm tumour	Dilated irregular veins on the surface Normal intrapancreatic branches
	A cm tumour surrounded by fibrosis	Tiny irregular veins in a 3 cm area Otherwise normal and patent veins



Fig 6 Male aged 37 years with chronic pancreatitis At laparotomy an inflammatory pseudotumour (6 cm in diameter) of the head of the pancreas was found The postoperative clinical course revealed no signs of malignancy after 18 months a) Injection into ant sup pancreaticoduodenal vein The veins of the head are slender irregular displaced Small veins near the post sup pancreaticoduodenal vein are patent (→) post sup vein probably occluded Right gastric vein ↔) middle colic vein (↔) b) Injection into the pancreatic duct during operation Severe stenosis of the major duct in the head displacement




cinoma of the extrahepatic bile ducts (proximal to the pancreas) one patient with submucosal lipomas of the duodenum and one patient with retropancreatic malignant lymphoma were examined

In one patient with cholangiocarcinoma no adequate demonstration of the veins of the pan[illegible] was obtained The veins of the pancreas were [illegible] and without morphologic abnormalitites in 7 pa[illegible] with carcinoma of the extrahepatic bile ducts [illegible] of these the choledochal veins were widened [illegible]



a



b



c

Fig 7 Male aged 67 years with chronic pancreatitis confirmed at laparotomy needle biopsy and the postoperative course of 14 months a) Injection into post sup pancreaticoduodenal vein Irregular slender veins but patent collaterals to ant sup pancreaticoduodenal vein (→) b) Injection into ant sup pancreaticoduodenal vein post sup pancreaticoduodenal vein is filled c) Severe wall irregularity and stenosis of the region of the confluence

...rtuous and in another occluded (Fig 8) The post ...up vein was dilated and tortuous choledochal veins ...ere present in one patient Displaced and stretched ...eripheral branches of the pancreaticoduodenal ...eins were found in a patient in whom laparotomy ...isclosed submucosal duodenal lipomas (Figs 9 10) Patent but stretched veins of the head of the pan...reas were demonstrated in a patient in whom prior laparotomy had disclosed a tumour mass in the head of the pancreas No abnormality was found at needle biopsy during operation The phlebographic findings confirmed an expansive lesion in this region but argued against a large pancreatic carcinoma as collaterals between the anterior and posterior veins were patent Percutaneous needle biopsy guided by phlebography revealed malignant lymphoma confirmed at a second laparotomy

Complications Extravasation of contrast medium occurred in 3 patients without causing discomfort to the patients Two examinations were impossible to evaluate

In one patient with chronic relapsing pancreatitis abdominal pain and anaemia occurred after the phlebography probably due to bleeding Serum amylase was normal but liver laboratory data pathologic The patient was treated conservatively

In one patient with islet cell tumour a subcapsular haematoma of the liver 7 cm×12 cm in diameter developed but no specific treatment was required

In one patient with islet cell tumour abdominal pain and fever followed accidental puncture of the



Fig 8 Male aged 44 years with carcinoma of the gallbladder causing obstruction of the extrahepatic bile ducts in the hilum of the liver Injection into post sup pancreaticoduodenal vein Left anterior oblique veiw Normal veins of the head of the pancreas Obstruction of the choledochal veins (→)

gallbladder The condition was normalized after 2 days

Intraabdominal bleeding which required emergency laparotomy occurred in 2 patients Both examinations were performed before 1974 when experience with percutaneous transhepatic puncture was still limited

Discussion

When selective phlebography of the pancreas was introduced (GÖTHLIN et coll) the hope was expressed that this method could be useful in the diagnosis of carcinoma of the pancreas since this tumour is apt to invade the veins early The previously reported minimum size of carcinoma of the pancreas diagnosed by phlebography was 3 to 4 cm (REICHARDT et coll 1978) These primary results



Fig 9 Male aged 21 years with multiple submucosal l the duodenum Hypotonic duodenography

were disappointing but confirmed in the pres creased material

The diagnostic phlebographic criteria foi creatic carcinoma were irregular stenoses ar struction of pancreatic veins with collateral fl the present material venous occlusion was the nating diagnostic finding The interruption of between anterior and posterior branches was evident

Irregular stenosis alone may however al observed in patients with chronic pancreatitis laterals were only demonstrated in 6 of 35 pa and in these cases due to stenosis of the sup mesenteric vein or the confluence and not d obstruction of pancreatic veins Small pancr collateral veins probably due to occlusion of creatic veins were only observed twice

The explanation is probably to find in the p creatic vein anatomy (REICHARDT & CAMER (1) The main veins of the organ are running on surface (2) the intrapancreatic veins are relat small and (3) usually the head of the pancreas drained by 4 main veins in 4 directions and cor tions also exist to the veins of the body If a c cinoma occludes a pancreatic vein its function be taken over by another one since no valves ex


a


b

10 Same case as in Fig 9 Injection into a) ant sup pan ati oduodenal vein and b) post sup pancreaticoduodenal vein demonstrates stretched patent veins indicating an expanding lesion without obstruction of pancreatic veins

ie phlebographic anatomy also explains why tu)urs smaller than 3 to 4 cm probably cannot be monstrated as the phlebographic appearance is minated by the main veins on the surface of the an These veins superimpose on the minor in pancreatic branches and it is improbable that any lusion of these can be observed Only when the nour is growing to the surface of the organ can clusion of the main branches be demonstrated As e contrast medium is injected against the blood)w sometimes a false impression of venous occlu)n is obtained However usually a proper evalu)n of the whole series allows a differentiation be /een occlusion and flow phenomenon

In patients with chronic pancreatitis the veins ere abnormal with irregularity abrupt changes of eir course and slender appearance The veins were retched in cases with pancreatic cysts and abscess ven in patients with severe inflammatory lesions ie veins were generally patent

The post sup pancreaticoduodenal vein was cluded in one case and a thrombotic wall irregu rity in the region of the confluence was observed in nother These findings were in discrepancy to the atent intrapancreatic veins and therefore arguing gainst pancreatic carcinoma as the cause of the norphologic abnormalities

The phlebographic findings thus allow differentia on between pancreatic carcinoma (larger than 3 to cm) and chronic pancreatitis The characteristic abnormalities in cases with carcinoma of the head of the pancreas are occluded veins in the area occupied by the tumour which as a rule result in absent flow between anterior and posterior pancreatic veins In patients with chronic pancreatitis the veins are abnormal in various degrees but generally patent Even if occlusion of veins occur a discrepancy between the localization of an occlusion and the patency of adjacent smaller veins allows a differentiation between chronic pancreatitis and a large carcinoma

In recent years computer tomography and ultrasound have been developed and at present improved to high sensitivity and specificity in evaluation of the morphology of the pancreas Together with ERCP percutaneous transhepatic cholangiography and percutaneous fine needle biopsy these methods will establish the diagnosis in patients with obstructive jaundice and suggestion of pancreatic malignancy and allow the differentiation between pancreatic carcinoma pancreatitis and extrapancreatic lesions in the majority of cases

In rare instances when differentiation between pancreatic carcinoma and pancreatitis cannot be obtained by these methods pancreatic angiography and phlebography may give valuable information If a specific tumour marker in pancreatic carcinoma could be found detection and localization of the tumour by pancreatic venous blood sampling and determination of the tumour marker might be possible

When the diagnosis of a pancreatic carcinoma is established angiography and portography are useful for evaluation of resectability of the tumour (REICHARDT & IHSE 1980) Selective phlebography is in these cases irrelevant

As expected the value of selective phlebography in endocrine tumours for detection of morphologic abnormalities was limited Most of the endocrine tumours are too small to be detected with this method The value of phlebography in endocrine tumours is almost exclusively to document the venous anatomy in order to allow a correct interpretation of blood sample analyses An interesting finding was dilated slightly irregular pancreatic veins in one patient with a malignant glucagonoma Theoretically this finding could be due to a pharmaco angiographic effect of glucagon but in 2 other patients with glucagonoma pancreatic phlebography appeared normal

Pancreatic phlebography was useful in the differentiation between pancreatic and extrapancreatic disease In patients with cholangiocarcinoma the veins of the pancreas usually were patent and normal arguing against a large pancreatic carcinoma In one case occlusion and in 2 cases stasis of the choledochal veins could be demonstrated

In a patient with malignant lymphoma in the region of the pancreas phlebography was of value to rule out a pancreatic carcinoma suggested from a mass lesion found at laparotomy Furthermore the percutaneous aspiration biopsy was successfully guided by phlebography However angiography in this case offered similar information and the biopsy could have been performed in combination with any other diagnostic method able to localize the lesion

Conclusions

1) Selective phlebography gave indication of carcinoma in 21 of 35 cases

2) The minimum size of demonstrable tumours was 3 to 4 cm

3) Differentiation between carcinoma and chronic pancreatitis is possible although of minor clinical value

4) Evaluation of venous morphology is without value in patients with islet cell tumours

5) Differentiation between pancreatic and peri pancreatic disease is possible but of no clinica portance

SUMMARY

Pancreatic phlebography was performed in 67 pa with proven inflammatory or tumour disease in the r of the pancreas The findings are described and the nostic value of the method is discussed

REFERENCES

GÖTHLIN J LUNDERQUIST A and TYLÉN U Se phlebography of the pancreas Acta radiol Dia 15 (1974) 474

HOEVELS J LUNDERQUIST A and TYLÉN U Perc ous transhepatic portography Acta radiol Dia 19 (1978) 643

INGEMANSSON S Pancreatic and intestinal catheterization with hormone assay Bulletin No the Department of Surgery University of Lund

LUNDERQUIST A and VANG J Sclerosing inject esophageal varices through transhepatic se catheterization of the gastric coronary vein A p nary report Acta radiol Diagnosis 15 (1974) 5

— BÖRJESSON B OWMAN T and BENGMA Isobutyl 2 cyanoacrylate (Bucrylate) in obliter gastric coronary vein and esophageal varices A Roentgenol 130 (1978) 1

— SIMERT G TYLÉN U and VANG J Follow up tients with portal hypertension and esophageal treated with percutaneous obliteration of gastri nary vein Radiology 122 (1977) 59

— ERIKSSON M INGEMANSSON S LARSSON L REICHARDT W *Selective pancreatic vein cathe tion for hormone assay in endocrine tumours* pancreas Cardiovasc Radiol 1 (1978) 117

REICHARDT W and CAMERON R Anatomy of the creatic veins A post mortem and clinical ph graphic investigation Acta radiol Diagnosis 21 (1 33

— IHSE I Percutaneous transhepatic portograph pancreatic carcinoma Diagnosis and evaluation sectability Acta radiol Diagnosis 21 (1980) 587

— INGEMANSSON S Selective catheterization for mone assay in endocrine tumours of the pan Acta radiol Diagnosis 21 (1980) 177

— LUNDERQUIST A and TYLÉN U Selective ph graphy in carcinoma of the pancreas Acta ra Diagnosis 19 (1978) 305

— INGEMANSSON S LUNDERQUIST A and NOR Selective mesenteric phlebography in patients carcinoid tumors Gastrointest Radiol 4 (1979) 1

WIECHEL K L Tekniken vid perkutan transhepati tapunktion (PTP) (In Swedish) Nord Med 86 (1 912

OM THE DEPARTMENTS OF DIAGNOSTIC RADIOLOGY UNIVERSITY HOSPITAL S 22185 LUND SWEDEN AND HAUKELAND SYKEHUS N 5016 BERGEN NORWAY

ABDOMINAL ANGIOGRAPHY AFTER INTRA-ARTERIAL INJECTION OF VASOPRESSIN

E BOIJSEN and J GOTHLIN

Various drugs have been tested in order to en nce the information about pathologic conditions visceral angiography Vasodilating drugs (KAHN CALLOW 1965 BOIJSEN & REDMAN 1966 REUTER REDMAN 1972 UDÉN 1972 GOLDSTEIN et coll 76) and vasoconstricting drugs (BOIJSEN & REDMAN 1967 KAHN et coll 1967 KAPLAN & BOOK IN 1972 EKELUND & LUNDERQUIST 1974 WKINS et coll 1975 and others) have been tested vasoconstrictors epinephrine norepinephrine d angiotensin have been most widely used and ve proved to be of some value in diagnosing liver tastases and pancreatic tumors Vasopressin is other vasoconstrictor which has been extensively ed for control of bleeding from the gastrointestinal ict (BAUM & NUSBAUM 1971 and others) but also r diagnostic purposes (BOIJSEN & GOTHLIN 1969) systematic analysis of the diagnostic usefulness this drug in visceral angiography has appeared nce vasopressin has been used as a diagnostic ol for several years at the department in Lund was found of interest to analyse a series of patients determine the value of the drug when adminis red intra arterially immediately before angio aphy

Material and Methods

A series of 123 patients was examined with celiac superior mesenteric angiography comprising one itial series and another series within 2 min after itra arterial bolus injection of 0 5 to 1 0 IU of nthetic lysine vasopressin (Postacton Ferring weden) The interval between the 2 series was 5 to 10 min with the patient supine in the same or almost the same projection The amount of contrast medium rate of injection (8–10 ml/s) and the series used were the same Each angiographic series covered a period of 16 seconds 2 frames per s for 4 s one frame per s for 4 s and one frame every other second for 8 s (8/4 4/4 4/8) Injection and exposures were recorded on a Mingograf making possible assessment of the transit time of contrast medium through the arteries and of the appearance time of the veins The analysis of the results in cluded comparison of the attenuation capacity of the contrast medium (i e the radiographic contrast of the medium as observed on the films) and the de tailed information on the arteries and veins in the 2 series The accumulation of contrast medium in normal organs as well as those with lesions was recorded


Results

On 3 occasions the arterial blood pressure was continuously recorded during the examination A slight elevation (10–20 mmHg) was observed imme diately following injection of the drug returning to control level in 10 to 15 min

Arterial emptying time i e the time lapse from the end of the injection of contrast medium to the last frame in which it could be observed within the arteries was recorded Individual variations were observed but generally a delayed transit of the medium after injection of vasopressin was recorded

Submitted for publication 27 December 1978





a b

Fig 1 Angiography of the celiac axis a) Before and b) 30 s after intra arterial injection of 1 IU of vasopressin in a patient with slight stenosis of the celiac axis with consequent widening of the pancreatico-duodenal arteries After vasopressin the flow in the splenic and hepatic arteries is slower indicated by the ei reflux into the aorta Arteries in the pancreatic head are le affected by the drug thus more vessels and a higher com effect are observed

Table 1

Mean emptying time of arteries before and after injection of 0 5 to 1 0 IU of vasopressin


Artery	No of cases	Control series	Emptying time in s after vasopressin	Diff
Common hepatic	22	0 8	2 5	1 7
Intrahepatic	29	2 1	5 8	3 7
Splenic	24	1 5	>6 3	>4 8
Intrasplenic	24	2 1	>8 9	>6 8
Pancreatic head	27	1 5	5 1	3 6
Pancreatic tail	26	1 8	5 8	4 0
Left gastric	21	2 3	6 9	4 6
Gastroduodenal	22	0 9	3 5	2 6
Right gastro-epiploic	21	3 0	>10 6	>7 6*
Superior mesenteric	10	0 8	1 9	1 1
Jejunal	16	3 9	6 2	2 3
Ileal	12	3 9	>8 2	>4 3*
Middle colic	16	5 3	6 7	1 4

Contrast medium often remaining in the arteries on the last film of the series (i e more than 12 s after end of injection)

(Table I) The arterial emptying time was inc by more than 4 s in the splenic and intrasp arteries in the left gastric right gastroepiploic ileal arteries The smallest changes were note the common hepatic the main stem of the sup mesenteric and in the middle colic arteries

The right gastroepiploic artery reacted m strongly to vasopressin than did the left ga artery The reaction in peripheral hepatic art and arteries of the head of the pancreas was sim with an increase in arterial emptying time of ab 3 5 s On the other hand in cases of stenosis of celiac artery the peripheral arteries of the h of the pancreas reacted less to vasopressin tha the hepatic arteries (Fig 1)

The arteries of the tail of the pancreas rema filled with contrast medium slightly longer t those of the head approaching the splenic a in that respect The width of the larger arteries common hepatic splenic superior mese usually did not change appreciably after va pressin The smaller arteries on the other hand a rule appeared thinner (Figs 1 2)



g. 1 Angiography of the celiac axis performed a b) before and d) 30 s after intra arterial injection of 1 IU of vasopressin in a patient with no observed abnormalities Exposures at the same time after start of injection After vasopressin marked reflux the aorta reduced flow in all splanchnic arteries particularly the gastric and splenic arteries The attenuation of medium is higher in hepatic pancreatic and phrenic arteries Intrahepatic and pancreatic arteries are thinner after vasopressin slight reduction in diameter of splenic artery Normal portal vein is observed 10 s after start of injection in the control series (b) After vasopressin splenic and main portal veins not observed but peripheral portal branches indicating intrahepatic shunting (→) The wall of the duodenal bulb is better visible

The morphology and hemodynamics of the veins were often impossible to define because the transit of the contrast medium was often too slow for the film series used The attenuation capacity of the medium was frequently too low to allow assessment of transit time The appearance time of the veins (measured from the start of injection to that moment when contrast medium was first observed in the veins) was increased by 2 to 3 s in the portal sple nic and coronary veins while it was approximately unchanged in the superior mesenteric jejunal ileal and colic veins (Table 2) In the celiac vascular system the change in arterial emptying time after vasopressin was more marked than the change in venous appearance time

In some cases intrahepatic arterioportal shunting was evident after celiac injection of vasopressin (Figs 2 3) The splenic and superior mesenteric veins were often invisible after vasopressin but veins from the large and small bowels often ap peared in normal time and with the same contrasting effect as in the control series

Reflux of contrast medium into the aorta was regu larly observed after the drug injection indicating increased peripheral resistance The contrasting effect of the arteries increased after vasopressin A detailed analysis of the film (Table 3) revealed en hanced contrast mainly in the hepatic and splenic arterial system and in arteries supplying the head of the pancreas and duodenum Less information was obtained on the gastric arteries Information on the arteries within the pancreatic tail and in the bowel varied markedly from case to case

The degree of accumulation of contrast medium (Table 4) was in most patients lowered after vaso pressin Increased accumulation seldom occurred in the liver and duodenum and only exceptionally in the remaining organs As could be expected decreased accumulation was most often observed in the spleen and the gastrointestinal tract with the exception of the duodenum

An analysis of the diagnostic value of vasopressin in patients with lesions in the upper abdominal organs was made with the following result

Liver Metastases hepatomas and hemangiomas were found in 20 patients In 13 of these the informa tion regarding vascular abnormalities and extent of the lesions increased (Fig 3) in 3 cases it was un changed and in 4 decreased After vasopressin the information increased especially in patients with hypervascularity of the liver causing dilution of the

Table 2

Mean appearance time (in seconds) of contrast medium in ... before and after injection of 0 5 to 1 0 IU of vasopressin

Vein	No of cases	Control series	Vasopressin series	Di[illegible]
Portal	11	8 2	10 4	
Splenic	14	7 4	9 8	
Coronary	3	6 4	7 5	1
Superior mesenteric	5	7 6	6 8	
Jejunal	14	9 2	9 2	
Ileal	11	8 6	8 6	
Colic	15	8 6	9 2	

Table 3

Changes in information of arteries supplying abdomin... tures after injection of 0.5 to 1 0 IU of vasopressin with control series (+ gain 0 no change − decrease ... mation)

Arteries to	No of cases	Percentage change			
		+++	+	0	−
Liver	65	22	40	23	6
Spleen	56	7	38	23	12
Pancreatic head	65	[illegible]3	43	17	15
Pancreatic tail	64	14	30	25	[illegible]7
Gallbladder	40	7	33	38	1[illegible]
Stomach	57	3	11	14	39
Duodenum	63	6	48	25	18
Small bowel	27	4	33	33	[illegible]6
Colon	26	0	35	46	15
Right diaphragm	65	5	1[illegible]	7[illegible]	11
Left diaphragm	65	12	6	71	5

Table 4

Changes in accumulation of contrast medium after int... injection of 0 5 to 1 0 IU of vasopressin

Organ	No of cases	Percentage change		
		+	0	
Liver	5[illegible]	14	38	48
Spleen	51	8	14	[illegible]8
Pancreas	66	6	55	39
Gallbladder	39	0	59	41
Doudenum	64	11	48	41
Small bowel	2[illegible]	5	13	8
Large bowel	24	8	38	54
Stomach	60	0	8	9[illegible]



a



b




c

Fig 3 Hepatoma Angiography of the hepatic artery a) before and b c) 30 s after intra arterial injection of 0 5 IU of vasopressin In the arterial phase the pathologic vessels as well as demarcation of the tumour appear more evident after vasopressin due to less dilution of medium which is diverted toward the tumour In the parenchymatous phase after vasopressin (c) intrahepatic portal veins are visible (→) Delineation of the tumour more evident in this phase

ntrast medium (Fig 4) The induced reduction flow caused increased attenuation of contrast dium and decreased parenchymatous accumulation Improvement in information was therefore ost marked in cases with reversed blood flow in e gastroduodenal artery irrespective of whether not this was combined with stenosis of the celiac is

Pancreas Sixteen patients with pancreatic disease (pancreatitis 8 carcinoma 8) were examined before and after vasopressin injection In 10 cases the information on the lesion was improved in 3 cases it was unchanged and in 3 patients with pancreatitis it was decreased As in liver disease increased information was obtained after vasopressin when stenosis of the celiac artery was observed or



a



b



c

Fig 4 Diffuse hepatoma of right lobe of liver and stenosis of celiac axis a) Celiac angiography gastroduodenal artery not filled b) Superior mesenteric angiography reversal of flow due to stenosis of celiac axis and hypervascularity of liver Displaced intrahepatic arteries and abnormal vascularity of upper part of the right liver lobe indicate a large liver tumour c) After intra arterial administration of 1 IU of vasopressin 30 s before repeat angiography of the superior mesenteric artery the tumour vessels are better filled and the tumour more evident The medium is diverted from the superior mesenteric and splenic arteries to the liver through wide collaterals which are only slightly affected by the vasopressin

when collateral circulation due to e g increased hepatic blood flow was present (Figs 1 4)

Intestines In 2 patients with carcinoid tumours fewer vessels were observed after vasopressin but the abnormalities were better demonstrated (Fig 5) In 4 patients with regional enterocolitis or enteritis vasopressin induced a marked decrease in the vascularity of the diseased area (Fig 6)

Discussion

No systematic investigation appears to made of the effects of vasopressin when a... tered as a bolus intra arterially at visceral ... graphy in man The benefits of using vasoc... tors at visceral angiography are debatable ... use of epinephrine has been advocated (B...



a



b

5 Carcinoid tumour in distal ileum a) Superior mesenteric ography b) After 0 5 IU of vasopressin repeat angiography ructed and occluded ileal and ileocolic arteries (→) The abnormal arteries better visible mainly because of less contrast accumulation in the bowel wall and tumour Marked reflux to the aorta

REDMAN 1966 KAHN et coll CEN & ROSEN SCH 1969 MILLER et coll 1969 HAWKINS et coll d others) as has the use of angiotensin (KAPLAN BOOKSTEIN EKELUND & LUNDERQUIST KIESER 1975 NOVAK & WEBER 1976 and others) The series used (8/4 4/4 4/8) did not fully cover prolonged venous phase In calculations of circula on times an error of about one second may exist ne dose of vasopressin chosen (0 5–1 0 IU) was ised on initial test angiographies using 0 1 to 2 0) The best result seemed to be obtained with 1 0 J


The most marked slowing of the flow after vaso essin administration occurred in the splenic left astric right gastroepiploic and ileal arteries with a orresponding delay of appearance time in the ortal splenic and coronary veins This is in ac ordance with findings in animals (BARR et coll 975) The relatively small effect on the left gastric rtery as compared with other gastric arteries may e explained by the position of the catheter tip Its exact position related to the origin of the left gastric artery could not be defined with certainty with the projection used but it seemed reasonable to assume that the tip was beyond the origin in most cases

Arterial emptying time After vasopressin it varied between different vascular regions The smallest changes following the drug were in the larger arteries which may be due to the fact that they are closer to the flushing effect of non contrast filled blood from the aorta However this is not in line with the relatively small change in emptying time of the colon arteries and the almost changed appearance time of the colon veins It is well known that vasopressin has a marked effect on smooth muscles especially in the colon but why the in creased peripheral resistance should be less in the vessels of the large bowel is not clear

An estimation of arterial emptying time similar to the present series has been presented for epine phrine (BOIJSEN & REDMAN 1967) Certain similari ties exist (dose response variations not considered)



a



b



c



d

Fig 6 Active granulomatous enteritis with marked abnorma[illegible] in the ileum a b) Superior mesenteric angiography H[illegible] cularity of ileum and jejunum Early filling of veins c d[illegible] peat angiography after intra arterial injection of 1 IU of va[illegible] sin Marked constriction of all arteries of the small [illegible] marked reduction of flow especially where the infla[illegible] process is most intense (c) Contrast medium passes in[illegible] colon veins (d →)

drug induced slowing of the circulation in the [he]patic splenic and pancreatic regions and in the [su]perior mesenteric artery the reflux to the aorta [a] definite difference in the response of the jejunal [an]d ileal vascular regions existed decreased arterial [em]ptying time after epinephrine increased after [va]sopressin

No obvious differences in the venous appearance [tim]e after the administration of epinephrine and [va]sopressin were found

Liver The increase in emptying time of the proper [he]patic artery after the administration of vaso[pr]essin was 3 7 s (mean value) with no evident [ch]ange in the calibre of the artery As contrast [me]dium remained longer in the intrahepatic arteries [an]d the attenuation capacity of the contrast medium [wa]s increased the information on the arteries was [inc]reased in two thirds of the patients (Table 3) [Th]e accumulation of contrast medium in the liver [wa]s decreased in half of the cases This finding [def]initely speaks in favour of a markedly decreased [flo]w which is also in agreement with the experi[me]ntal results of vasopressin infusion (HANSON [19]70 BARR et coll ERWALD & WIECHEL 1978) [Th]ere an initial drop in hepatic blood flow was [foll]owed by an increase in flow above control level [Th]e vasopressin angiographic series was performed [wit]hin a period compatible with this initial phase

[...]A hepatic arterial escape from vasopressin [ind]uced vasoconstriction after infusion of vaso[pre]ssin has been described The hepatic blood flow [ca]lculated from the increased width of the hepatic [ar]tery was a mean of 134 per cent after probably (the [do]se is not clearly stated) 0 2 IU of vasopressin [in]fused for 20 min in man (CONN et coll 1973) The [pr]esent authors support the view that the biphasic [re]sponse is due to decreasing portal blood flow and [p]ortal venous pressure with a consequent auto[re]gulation of hepatic arterial flow This is supported [b]y experimental work by COHEN et coll (1970) [T]he early appearance of peripheral portal vein bran[ch]es indicating an arterial portal shunting as ob[se]rved in some of the present cases speaks in [fa]vour of an autoregulation which does not exclude [th]e possibility of arterial vasoconstriction

[...] Increased information regarding neoplastic ves[se]ls and the extent of lesions was obtained in 65 [p]er cent of the cases This does not differ much from [re]sults obtained by previous authors who advocated [t]he use of epinephrine and angiotensin At stenosis [o]f the celiac artery or hepatic hypervascularization vasopressin caused a diversion of blood from the superior mesenteric artery via collaterals to the hepatic artery (Figs 1 4) Since the accumulation of contrast medium in the liver after vasopressin is low the use of the drug in the detection of less vascularized metastases is probably of little value

Pancreas The arterial emptying time in the head of the pancreas was somewhat less increased than in the tail The gain in information was greater in the head than in the tail while the accumulation of contrast medium was decreased throughout In animals vasopressin when infused reduced the pancreatic blood flow while one experiment demonstrated unchanged pancreatic venous outflow after a single injection of 20 mU/kg body weight of vasopressin (SCHAPIRO & BRITT 1972) The increased information obtained on lesions in two thirds of the present patients was the result of the large amount of contrast medium diverted to the pancreas the improved demonstration of abnormal vessels probably collaterals and the almost total absence of disturbing gastric vessels Compared with angiotensin and epinephrine vasopressin seemed to give some increase in information as to the arteries but probably the same amount of information regarding lesions The combination of secretin and epinephrine may give further vascular details (UDÉN 1976)

Spleen Lesions others than ruptures or aneurysms are rare (EKELUND et coll 1975) The effect of vasopressin in tumours of the spleen has not been tested The very slow flow of contrast medium through the splenic arteries increased the information because of better arterial detail particularly since the accumulation of contrast medium was markedly decreased in most patients

Intestines The arterial emptying time of ileal arteries was much longer than that of jejunal arteries Several patients with regional enterocolitis and enteritis included in the material may have markedly influenced the results The appearance time of the corresponding veins was unchanged however which may perhaps be attributed to the opening up of submucous shunts by vasopressin It should be noted that in the gastric and splenic systems with a high peripheral arterial resistance the appearance time of veins was delayed but not to an extent which would correspond with the delay in arterial emptying

Superior mesenteric blood flow measured by a dye dilution technique fell far below the level of

200 ml/min in humans for several min after bolus injection of 0 125 to 1 0 IU of vasopressin (NORRYD et coll 1975) which has also been reported by ERWALD et coll (1976 determined by calculation of changes in the total splanchnic oxygen uptake after intravenous vasopressin infusion) This marked depression of the flow also explains the decrease of the portal flow found in dogs (NYLANDER 1967 SCHAPIRO & BRITT)

It is interesting that abnormal vessels in carcinoid tumours were more clearly demonstrated as well as the extent of the lesion The vessels in inflammatory disease seem to be more sensitive to vasopressin than normal or neoplastic vessels thereby administration of the drug can add to the differential diagnostic potential of angiography

Complications

One patient referred for examination because of bleeding after gastric resection followed by wound infection began to bleed severely upon injection of vasopressin In the control series an aneurysm was found at the site of ligation of the gastroduodenal artery The increased arterial pressure caused by injection of contrast medium combined with the peripheral vasoconstriction probably caused high perfusion pressure in the gastroduodenal artery with ensuing rupture of the aneurysm The patient shocked but the bleeding was controlled by blood infusion and immediate operation No other complications occurred

It may be stated generally that intra arterial administration of vasopressin increases the amount of information obtained about lesions in the pancreas and liver with the exception of pancreatitis and avascular liver processes It may also contribute to a differentiation between malignant and inflammatory disease in the intestines It may be of special value in celiac stenosis by diverting blood from the superior mesenteric artery to the hepatic artery

An advantage of vasopressin compared with other vasoconstrictors is that its activity after bolus injection lasts longer giving the examiner reasonable time for the angiographic procedure

SUMMARY

Vasopressin administered as a bolus immediately before selective visceral angiography increased the information obtained in hepatic and pancreatic dise[...] drug may be helpful in differentiating between [...]matory and malignant lesions in the intestines

REFERENCES

BARR J W LAKIN R C and RÖSCH J Effect of [...] celiac infusion of vasopressin on the hepat[...] flow Invest Radiol 10 (1975) 200

BAUM S and NUSBAUM M The control of gas[...]tinal hemorrhage by selective mesenteric ar[...]fusion of vasopressin Radiology 98 (1971) 49[...]

BOIJSEN E och GÖTHLIN J Visceral angiografi ef[...] arteriell injektion av vasopressin (In Swedis[...] Med 82 (1969) 936

— and REDMAN H C Effect of bradykinin [...] and superior mesenteric angiography Invest [...] 1 (1966) 422

— — Effect of epinephrine on celiac and supe[...]senteric angiography Invest Radiol 2 (1967)[...]

CEN M und ROSENBUSCH G Zöliakographie [...]nalin Möglichkeiten der Pharmacoangiograp[...] Pankreasdiagnostik Fortschr Röntgenstr 1[...] 82

COHEN M N SITAR D S MCNEILL J R an[...]WAY C N The effect of vasopressin and ar[...] on resistance vessels of spleen intestine a[...] Amer J Physiol 10 (1970) 200

CONN H O RAMSBY G R and STORER E H [...] arterial escape from vasopressin induced vaso[...]tion An angiographic investigation Amer [...]genol 119 (1973) 102

EKELUND L and LUNDERQUIST A Pharmaco[...]phy with angiotensin Radiology 110 (1974) 5[...]

— GÖTHLIN J and PETTERSSON A Angiograp[...]pansive lesions of the spleen Amer J Ro[...] 125 (1975) 81

ERWALD R and WIECHEL K L Effect of vas[...] on splanchnic and central hemodynamics i[...]man Acta chir scand 144 (1978) 347

— — and STRANDELL T Effect of vasopressi[...]gional splanchnic blood flows in conscious m[...] chir scand 142 (1976) 36

GOLDSTEIN H M THAGGARD A WALLACE [...] NEIMAN H L Priscoline augmented hepati[...]graphy Radiology 119 (1976) 275

HANSON K M Vascular response of intestine a[...] to intravenous infusion of vasopressin Amer [...]siol 219 (1970) 779

— and JOHNSON P C Local control of hepatic [...] and portal venous flow in dog Amer J Phys[...] (1966) 712

HAWKINS J F KAUDE J V and MACGREGOR A [...] line and epinephrine in selective pancreatic [...]graphy Radiology 116 (1975) 311

KAHN P C and CALLOW A D Selective vasodil[...] as an aid to angiography Amer J Roentge[...] (1965) 213

— FRATES W J and PAUL R E JR Epinephrine [...] in angiography of gastrointestinal tract tumors [...]logy 88 (1967) 686

PLAN J J and BOOKSTEIN J J Abdominal visceral pharmacoangiography with angiotensin Radiology 103 (1972) 79

LLER W J REUTER S R and REDMAN H C Epinephrine effect in angiography of colonic carcinoma An inconsistent aid in diagnosis Invest Radiol 4 (1969) 246

RRYD C DENCKER H LUNDERQUIST A and OLIN T Superior mesenteric blood flow in man following injection of bradykinin and vasopressin into the superior mesenteric artery Acta chir scand 141 (1975) 119

VAK D und WEBER J Pharmakoangiographie mit Angiotensin Fortschr Rontgenstr 124 (1976) 301

LANDER G Vascular response to vasopressin as reflected in angiography An experimental study in the dog Acta radiol (1967) Suppl No 266

POKIESER H Pharmacoangiography *In* Efficiency and limits of radiologic examination of the pancreas p 167 Edited by H Anacker Georg Thieme Stuttgart 1975

REUTER S R and REDMAN H C Gastrointestinal angiography W B Saunders Philadelphia 1972

SCHAPIRO H and BRITT L G The action of vasopressin on the gastrointestinal tract Dig Dis 17 (1972) 649

UDÉN R Cholecystokinin pancreozymin in celiac and superior mesenteric angiography Acta radiol Diagnosis 12 (1972) 363

— Secretin and epinephrine combined in celiac angiography Acta radiol Diagnosis 17 (1976) 17

OM THE DEPARTMENTS OF INTERNAL MEDICINE RADIATION THERAPY AND CLINICAL CHEMISTRY UNI VERSITY OF OULU SF 90220 OULU FINLAND

COMPARISON OF THREE METHODS OF MEASURING LIVER BLOOD FLOW

H PIRTTIAHO U PITKANEN M RAJASALMI and A AHONEN

An accurate method of measuring liver blood flow of importance both for practical and theoretical isons hepatic flow estimations may for instance useful for considering a porta caval shunt opera n and for the relationship between drug disposi n and liver blood flow A technique of measuring r blood flow with dynamic $^{99}Tc^{m}$ sulfur colloid ns described previously (PIRTTIAHO & PITKA N 1977) has been compared with two independent thods of examining liver blood flow by in yanine green (Cardiogreen) disappearance and Xe wash-out

Material

In 5 patients (4 men one woman mean age 36 ars) undergoing standard cardiac catheterization correlation between $^{99}Tc^{m}$ sulfur colloid and in icyanine green flow values was evaluated Seven fferent patients (4 women 3 men mean age 53 ars) admitted to the hospital for diagnostic liver sts were examined to ascertain the relationship tween flow values obtained by ^{133}Xe clearance id $^{99}Tc^{m}$ sulfur colloid methods All cardiac pa nts had normal liver function tests (amino insferases alkaline phosphatase bilirubin 45 min omsulphatalein retention test) and none of them id incompensated heart failure All liver patients id disturbances in liver function and pathologic ver parenchyma in needle biopsy specimens All ibjects were hospital in patients the flow examina ons were undertaken on the basis of an informed onsent

Methods

Indocyanine green disappearance method After cardiac catheterization the venous catheter was placed in one hepatic vein and the arterial catheter left in the ascending aorta After withdrawal of blood for plasma blank indocyanine green (0 5 mg/ kg body weight) was given as a fast intravenous injection in the left arm Arterial and hepatic vein blood specimens were drawn simultaneously at 1 2 3 4 6 9 12 15 and in some cases 18 and 21 min after the injection Heparinized blood samples were centrifuged at 3 000 rpm for 20 min and assessed immediately by a Hitachi 101 spectrophotometer at a wavelength of 800 nm against each patient s plasma blank Indocyanine green concentrations were plot ted against time on a semilogarithmic graph and the half time of indocyanine green (T/2) was read from the linear part of the curve The disappearance rate constant (k) was calculated from the equation $k=\ln 2/T/2$ Estimated liver blood flow was calculated according to CAESAR et coll (1961) from the formula $ELBF=k \times BV/E$ where BV is the esti mated blood volume and E the hepatic extraction efficiency of indocyanine green calculated as the difference between estimated arterial and hepatic venous plasma zero time concentrations and expres sed as a percentage of arterial plasma zero time concentrations Because of technical difficulties the determination of E was not possible in all cases It was therefore not taken into account in calculations

Submitted for publication 8 June 1979

Table 1

Liver blood flow estimated with indocyanine green and $^{99}Tc^m$ sulfur colloid in cardiac patients

Case No	Age and sex	Diagnosis	Blood volume (ml)	Indocyanine green		$^{99}Tc^m$ sulfur colloid		Relative difference per cent (min)
				T/2 (min)	Flow (ml/min)	T/2 (min)	Flow (ml/min)	
1	24 M	AS + AI	5 300	2 80	1 314 4	2 70	1 338 3	0 9
						2 90	1 266 7	1 8
2	35 M	AS + AI	4 550	2 55	1 237 6	2 67	1 183 0	2 3
3	37 M	AI	5 250	2 80	1 302 0	2 75	1 323 0	0 8
						2 66	1 370 3	2 6
4	54 F	ASD	4 450	2 90	1 063 5	2 83*	1 090 3	1 2
5	30 M	CMP	4 950	2 50	1 371 2	2 25	1 524 6	5 3

AS=aortic valve stenosis AI=aortic valve incompetence ASD=atrial septal defect CMP=congestive cardiomyopathy

* Half times obtained from measurements with gamma camera Other half times measured with external scintillation counter

Table 2

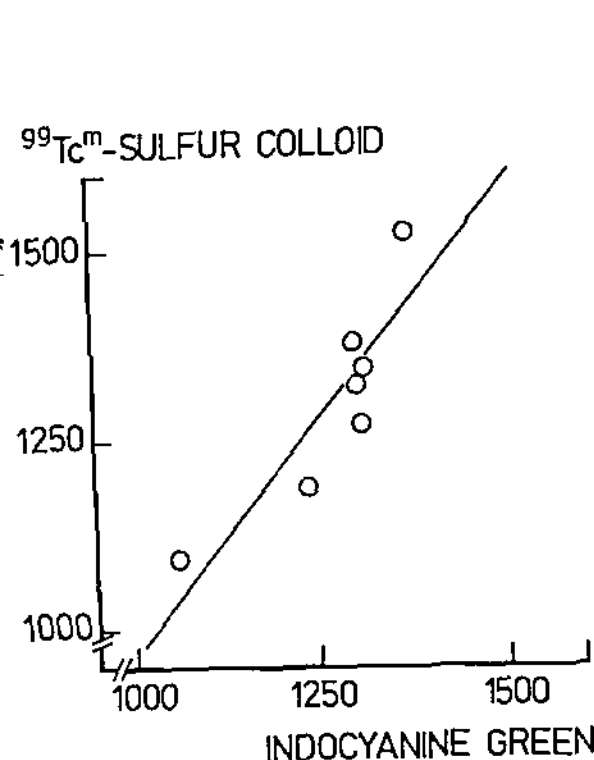
Liver blood flow estimated with $^{99}Tc^m$ sulfur colloid accumulation and ^{133}Xe clearance in liver patients

Case No	Age and sex	Diagnosis	Blood volume (ml)	$^{99}Tc^m$ sulfur colloid		^{133}Xe		Rel. diff. (per
				T/2 (min)	Flow (ml/100 g/ min)	T/2 (min)	Flow (ml/100 g/ min)	
6	59 F	Chronic active hepatitis	3 600	2 30	68 8	1 35	37 0	30 1
7	66 F	Chronic active hepatitis	3 950	2 00	79 0	1 04	48 0	24 4
8	36 F	Primary biliary cirrhosis	4 050	2 10	77 5	0 89	54 0	17 9
9	58 M	Primary biliary cirrhosis	4 850	2 37	81 4	0 73	68 0	9 0
10	34 M	Fatty degeneration of liver	6 300	2 00	59 4	2 08	24 0	42 4
11	56 F	*Fatty degeneration of liver*	3 780	1 93	95 2	0 92	56 0	25 9
12	63 M	Fatty degeneration of liver	5 470	2 23	86 7	0 45	110 0	11 8

of liver blood flow resulting in somewhat overestimated flow values Blood volume was estimated from the nomograms of Amersham Radiochemical Centre (1967) based on the weight and length of the subjects

$^{99}Tc^m$ sulfur colloid method Estimation of liver blood flow by dynamic Tc sulfur colloid scans was performed as described previously (PIRTTIAHO & PITKANEN) In brief a dose of 72 MBq was injected rapidly into a cubital vein and the accumulation of the isotope into the liver was recorded in 20 seconds increments by the memory of the computer connected to the gamma camera (Radicamera Selektronik Denmark) When calculating the flow a square of 2 cm × 2 cm within the liver image on the computer display was defined by a light pen and the accumulation of isotope to this area was determined as a function of time The plateau of the time-[activi]ty curve was calculated and the activity of e[ach 20] seconds sequence subtracted from it Plotting [the differ]ences on a semilog graph gave a two phased [curve] with a steep initial part and a more gently s[loping] later one The latter part of the curve was ex[trapo]lated to zero and half time of isotope accumu[lation] to the liver was assessed The estimated liver [blood] flow was then calculated according to DOBS[ON &] JONES (1952) with the formula given previ[ously] Measurements with the gamma camera were [per]formed on the day of other flow measuremen[ts or] the following day

In some of the cardiac patients liver blood [flow] was estimated also by injecting $^{99}Tc^m$ sulfur c[olloid] immediately after indocyanine green in ca[rdiac] catheterization and measuring its accumulat[ion]



1 Relationship between estimated liver blood flow (ml/min) ed on the indocyanine green disappearance method and the m sulfur colloid accumulation technique $y = 1.24x - 270$ 88 $p < 0.01$ $n = 7$

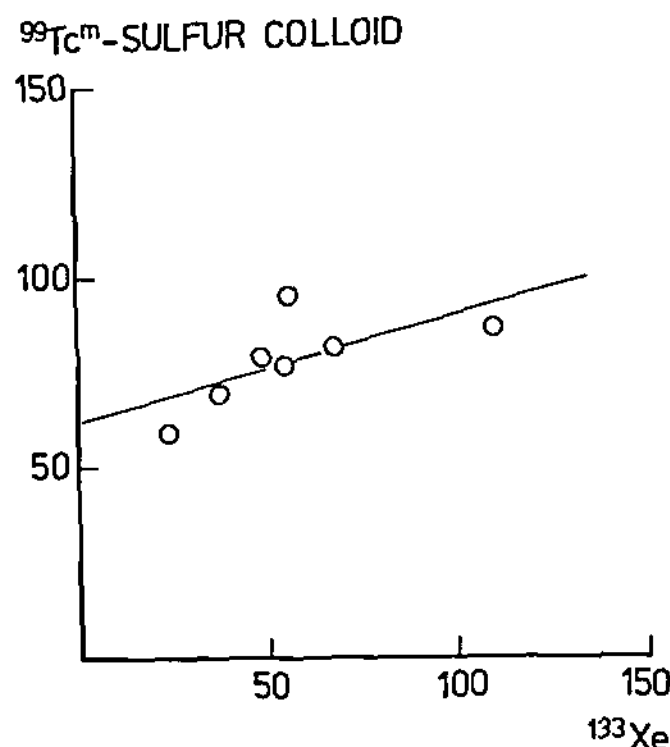


Fig 2 Correlation between relative liver blood flow values (ml/min/100 g) obtained by the ^{133}Xe wash-out method and the dynamic ^{99}Tc^{m} sulfur colloid accumulation technique $y = 0.8x + 62.3$ $r = 0.67$ $p > 0.05$ $n = 7$

o liver by a single channel pulseheight analyzer 5 11B Wallac Turku Finland) connected to a ital ratemeter (SC 25 Wallac Turku Finland) e detector was placed against the right lateral est wall at the site of maximum dullness in liver rcussion The calculations for liver blood flow re carried out as previously described

In some cases the activity of ^{99}Tc^{m} sulfur colloid blood specimens drawn for indocyanine green easurements was measured with a gamma counter KB 1280 Ultrogamma) The blood specimens ere hemolyzed with Zap Oglobin before the measurements The hepatic extraction efficiency of Tc^{m} sulfur colloid was calculated as described

Liver size was measured from the liver scans according to the method of ROLLO & DELAND (1968) described by PIRTTIAHO & PITKANEN Relative LBF was calculatd by dividing absolute ELBF with estimated liver weight and expressed as ml/100 liver

^{133}Xe clearance method About 370 MBq of ^{133}Xe socommerz Berlin DDR) in physiologic saline was injected rapidly intravenously followed by ushing with 10 ml of saline The removal of the racer over a region of the liver selected with a light pen in the antero posterior position was measured with a gamma camera (Radicamera Selektronik Denmark) interfaced with a small digital computer (Nova 1220) The channel width used was 10 seconds and the whole measuring time 10 min The fast component of the two exponential liver clearance curve was used for the calculations of liver blood flow the slow component originating from extrahepatic tissues (DARLE 1970 MACKENZIE et coll 1976) The estimated liver blood flow was calculated according to the formula ELBF=$\lambda \times k$ where λ is the partition coefficient between blood and the liver tissue and k the disappearance rate constant of the fast component The value of the partition coefficient is dependent on the fat content of the liver tissue (ANDERSEN & LADEFOGED 1967) The coefficient value of 0.72 was used corresponding to a liver fat content of 4 per cent (DARLE)

Results

Tables 1 and 2 give the relevant data for the cardiac and liver patients respectively The correlation of liver blood flow values obtained with dynamic ^{99}Tc^{m} sulfur colloid scans to those measured with

indocyanine green and ^{133}Xe is shown in Figs. 1 and 2. The mean ELBF in cardiac patients was 1258±119 ml/min with indocyanine green and 1299±53 ml/min with ^{99}Tc^{m} sulfur colloid. The mean relative difference between these flow values was only 2.1 per cent. The flow estimations with ^{133}Xe and ^{99}Tc^{m} sulfur colloid differed more, the mean relative FLBF being 57±27 ml/100 g/min with the former and 78±11 ml/100 g/min with the latter technique. The relative difference between the results of these methods was 23.1 per cent.

The extraction efficiency of indocyanine green was measured in cases 1 and 4 to 70.7 per cent and 72.8 per cent, respectively. The extraction efficiency of ^{99}Tc^{m} sulfur colloid was 78 per cent (case 2) and 79 per cent (case 4) in the two measured cases.

Discussion

In the present investigation, liver blood flow was estimated with three different techniques, each independent from the others. Indocyanine green is removed from the blood flow only by the liver and excreted into the bile mostly in unchanged form. The first liver blood flow measurements using this substance employed the constant infusion method and a modification of Fick's principle, but CAESAR et coll. have shown that analysis of the plasma disappearance curve after a single injection gives nearly identical results. ^{99}Tc^{m} sulfur colloid is phagocytosed by hepatic reticuloendothelial cells, only minor amounts appearing in the spleen and bone marrow. The clearance rate of particulate matter by Kupffer cells has been shown to measure liver blood flow (DOBSON & JONES), and the results have been closely comparable to those obtained by direct flow measurements (RAZZAK & WAGNER 1961, CARTER & ANKENEY 1964). Moreover, the results of external measurement of isotope accumulation in the liver have been closely comparable with those obtained by repeated blood sampling (TORRANCE & GOWENLOCK 1962). Radioactive rare gases, such as ^{133}Xe, have been used in the measurement of blood flow in various organs, including the liver. After entering the blood stream, ^{133}Xe is distributed between blood and liver tissue and washed out by the venous blood. The specific blood flow (per unit weight of tissue) can be determined from the rate of wash-out. Most animal experiments have been performed by injecting ^{133}Xe into the portal vein or hepatic artery (REES et coll. 1964, DANIELSON & KARLMARK 1970, MACKENZIE et coll.), though intravenous injection has been shown to give cl comparable results (LARSON et coll. 1973). A d back in the ^{133}Xe method is the fact that the par coefficient is dependent on the lipid content o organ, which is often abnormal in liver disea e the methods mentioned, the one using indocy green has been vastly used, and it can therefo considered as a standard or reference meth measuring liver blood flow.

The present investigation revealed a good co tion between flow values estimated with ^{99}Tc fur colloid and those obtained by the indocy green clearance method, indicating that dy liver scanning with ^{99}Tc sulfur colloid is a tool in examining liver blood flow. It has al advantage of being easy to perform and offerin discomfort to the patient. According to pre experience the reproducibility of the method fairly good (PIRTTIAHO & PITKÄNEN).

The extraction efficiency of indocyanine was not taken into account in the present ca tions of estimated liver blood flow. The two ca which it was measured gave the mean result o per cent, which is closely comparable to the reported by CAESAR et coll. The extraction ef cy of ^{99}Tc^{m} sulfur colloid was of the same or magnitude. Thus, although not taking extr efficiency into account may lead to underestim the liver blood flow, the effect on the mutua tionship between flow measurements wit docyanine green and ^{99}Tc^{n} sulfur colloid is sm

Comparison of the flow measurements wi two isotope methods yielded an unsatisfactor relation. This may be caused by the dependen lipid concentration of the partition coeffici ^{133}Xe, which has been shown to be positivel related to the fat content in the tissues (ANDERS LADEFOGED). Three of the patients had fatty de eration of the liver, and the partition coefficie 0.72 might have been too small. On the other h finding a more valid partition coefficient is not p sible without the analysis of the actual fatty c of the liver. This fact is maybe the most sen disadvantage associated with the use of ^{133}X routine estimations of liver blood flow.

In conclusion, results of liver blood flow a s ment with ^{99}Tc^{m} sulfur colloid are closely parable to those measured by the establish docyanine green method, while ^{133}Xe flow m urement appeared to be less satisfactory.

SUMMARY

Liver blood flow was measured by dynamic $^{99}Tc^m$ sulfur colloid accumulation and indocyanine green disappearance in 5 subjects and by $^{99}Tc^m$ sulfur colloid accumulation and ^{133}Xe wash-out in 7 subjects Results obtained by $^{99}Tc^m$ sulfur colloid and indocyanine green methods were closely comparable whereas the flow values estimated by the two isotope methods did not correlate well

REFERENCES

ANDERSEN A M and LADEFOGED J Partition coefficient of ^{133}Xenon between various tissues and blood in vivo Scand J clin Lab Invest 19 (1967) 72

CAESAR J SHALDON S CHIANDUSSI L GUEVARA L and SHERLOCK S The use of indocyanine green in the measurement of hepatic blood flow and as a test of hepatic function Clin Sci 21 (1961) 43

CARTER T L and ANKENEY J L Hepatic blood flow determined by colloidal gold clearance compared with direct flow measurement J nucl Med 5 (1964) 901

DANIELSON B G and KARLMARK B Hepatic blood flow in dogs measured by Xe^{133} clearance technique Acta Soc Med upsalien 75 (1970) 171

HOLE N Xenon ^{133} clearance and liver blood flow An experimental study in the cat Acta chir scand (1970) Suppl No 407

JOHNSON E L and JONES H B The behaviour of intravenously injected particulate material its disappearance from blood stream as a measure of liver blood flow Acta med scand 144 (1952) Suppl No 273

LARSON S M MILLER R C CHALMERS T C GELRUD L G RAMER R J BAILEY J J and JOHNSTON G S Quantitation of liver blood flow by xenon 133 clearance *In* The liver quantitative aspects of structure and function p 96 Edited by G Paumgartner and R Preisig Karger Basel 1973

MACKENZIE R J LEIBERMAN D P MATHIE R T RICE G C HARPER A M and BLUMGART L H Liver blood flow measurement The interpretation of xenon ^{133} clearance curves Acta chir scand 142 (1976) 519

PIRTTIAHO H I and PITKANEN U Size and blood flow of the liver estimated by $^{99}Tc^m$ scanning Acta radiol Ther Phys Biol 16 (1977) 497

RAZZAK M A and WAGNER H N JR Measurement of the hepatic blood flow by colloidal gold clearance J appl Physiol 16 (1961) 1133

REES J R REDDING W J and ASHFIELD R Hepatic blood flow measurement with xenon 133 Evidence for separate hepatic arterial and portal venous pathways Lancet II (1964) 562

ROLLO F D and DELAND F H The determination of liver mass from radionuclide images Radiology 91 (1968) 1191

TORRANCE H B and GOWENLOCK A H Radioactive colloidal clearance techniques to measure liver blood flow in man Clin Sci 22 (1962) 413

OM THE DEPARTMENTS OF DIAGNOSTIC RADIOLOGY AND MEDICINE AARHUS KOMMUNEHOSPITAL DK
8000 AARHUS DENMARK

RENAL OSTEODYSTROPHY

Effect of hemodialysis and 1α hydroxy vitamin D_3 on bone lesions and metacarpal bone mass

J ANDRESEN H E NIELSEN and A JOHANNSEN

The radiologic bone abnormalities in patients with onic renal failure are highly complex consisting osteomalacia osteosclerosis metastatic calcifica n and osteitis fibrosa cystica with subperiosteal orption (RESNICK & NIWAYAMA 1976) Vitamin D istance in uremia may be explained by a defect ydroxylation of vitamin D in severely diseased neys (MAWER et coll 1973 BRICKMAN et coll 4) With the chemical synthesis of 1α hydroxy olecalciferol (1α OH vitamin D_3 HOLIC et coll 3) a new possibility for the treatment of renal eodystrophy was introduced The treatment with OH vitamin D_3 is of clinical value in children d adolescents with severe renal bone lesions IELSEN et coll 1976 HENDERSON et coll 1975 HANNSEN et coll 1979) but its effect on bone in ult patients with renal osteodystrophy are less ident (PIERIDES et coll 1976 JUNOR et coll 1976 ELSEN et coll 1977)

The present report describes radiologic bone le ons and metacarpal bone mass during chronic modialysis and during treatment of hemodialyzed ults with 1α OH vitamin D_3 and phosphate binder

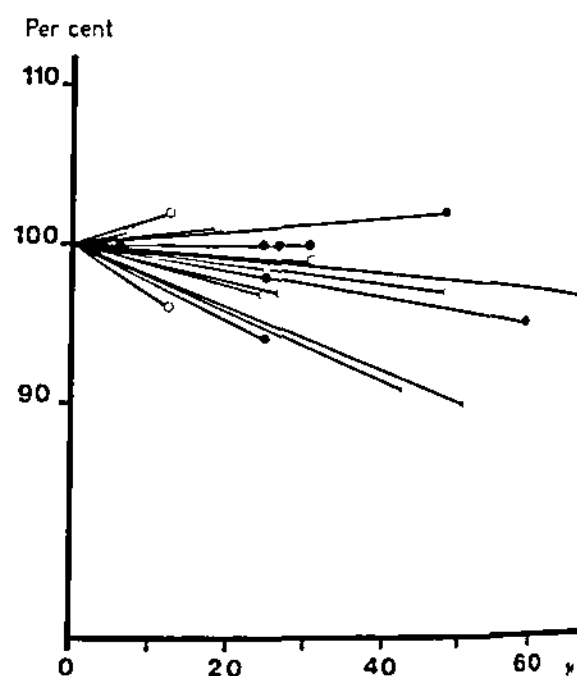
Material and Methods

Twenty patients (8 males and 12 females) aged 18 54 years with chronic renal failure (due to con nital renal disease polycystic kidney disease ialgetic nephropathy chronic glomerulonephritis ironic pyelonephritis or nephrosclerosis) treated ith hemodialysis for more than 6 months (mean 28 months range 6–72) were evaluated radiographical ly at the beginning of dialysis and during the follow up period The patient s diets contained 60 to 70 g protein 20 to 30 mEq sodium and 500 to 600 mg calcium per day They were dialyzed for 8 to 10 hours twice weekly using a one m 13 5 μm thick cuprophane membrane (Rhone Poulenc RP5) The dialysis unit was supplied with distilled water and the dialysate contained 3 0 mEq/l of calcium and 1 2 mEq/l of magnesium No phosphate or fluoride was added to the dialysate Eight of the 20 patients were treated with 1α hydroxy vitamin D_3 for 6 months The time interval from the beginning of dialysis to the beginning of treatment ranged from 8 to 57 months with a mean of 30 months

1αOH vitamin D_3 (dissolved in propylen glycol) was given initially in an oral daily dose of 1 μg It was adjusted monthly according to the serum con centration of calcium in order to maintain calcium within the upper normal range If hypercalcemia developed the dose was reduced but the treatment was never discontinued In order to control hyper phosphatemia aluminium aminoacetate was given for 2 to 3 months before the start of 1α HCC treat ment and was continued during 1α HCC treat ment with changes in dosage according to variations in serum phosphate None of the patients received oral calcium supplements or anticonvulsants but one patient received 5 mg prednisone daily for rheumatoid arthritis

Submitted for publication 11 May 1979

Radiography of the skeleton except the ribs and the shaft of the long bones of the extremities was performed and evaluated blindly with regard to rarefaction of the spine subperiosteal erosions intracortical cyst formations and acro osteolysis The presence and extent of calcifications in soft tissues and vessels were also evaluated The cortical area of the second left metacarpal bone $(D^2 - d^2)/D^2$ was used as an index of bone mass measuring the outer diameter of the bone width (D) and the diameter of the medullary space (d) at the midpoint of the shaft at right angles to the long axis of the bone as described by DEQUEKER (1976) The results were expressed both in absolute values and as per cent of reference values from cases of similar age and sex given by GARN et coll (1971) The intraobserver variation coefficient on $(D^2 - d^2)/D$ was 1 6 per cent and the interobserver variation coefficient 2 4 per cent



Metacarpal bone mass $(D^2 - d^2)/D^2$ corrected for normaliza-tion in per cent of initial value in 20 chronic hemod- patients during dialysis ● males O females

Results

At the beginning of the dialysis 11 of the 20 patients were considered to have a slight degree of osteoporosis of the spine Only one patient had subperiosteal erosions and one acro osteolysis No cyst formation was found Calcifications in the soft tissues appeared in 10 patients The metacarpal bone mass was subnormal compared to the reference values given by GARN et coll

During the period of dialysis the incidence and degree of osteoporosis of the spine increased A significant increase in the frequency and the degree of subperiosteal erosions occurred Soft tissue calcifications were unchanged in 3 patients but increased in 11 One patient developed intracortical cyst and acro osteolysis developed in one patient and decreased in one In all patients the metacarpal bone mass was reduced during the whole period of dialysis (Figure $p<0\,01$ Wilcoxon test) and yearly ($p<0\,05$ Wilcoxon test)

The most common site of subperiosteal erosions was at the medial end of the clavicles and the terminal tufts of the hands Vascular calcifications occurred most often in the abdominal aorta (12 patients) the iliac arteries (13 cases) periarticular calcifications most frequently at the humero scapular joint (7 patients) In a few cases the calcifications were localized to the interphalangeal joints in the hands and feet

All 8 patients treated with 1α OH vitamin D_3 had osteoporosis of the spine at the beginning treatment and in 5 osteoporosis developed the dialysis 1α OH D_3 treatment did not ch incidence and degree of osteoporosis S erosions appeared in 6 patients at the beg the treatment and were unchanged at complet the treatment in 4 cases improved in 2 C cyst developed during dialysis and disappear ing 1α OH D_3 treatment None of the patien acro osteolysis at any time During treatment tissue calcifications increased in 2 patients a creased in one (Table) Metacarpal bone ma creased significantly (0 12% per month p Wilcoxon test) before 1α OH vitamin D_3 was whereas no significant change occurred during treatment period

Discussion

At the beginning of the dialysis only a mild de of renal osteodystrophy was found In the foll period an increase in the incidence and subperiosteal erosions in soft tissue calcifi and in osteoporosis of the spine occurred as we significant decrease in the metacarpal bone m

The radiologic features of renal osteody are well documented in patients with severe failure (JOHNSON et coll 1967 WELLER et coll 1

Table

al data radiologic evaluation and metacarpal bone mass in 8 hemodialysed patients at the beginning of dialysis (1) before (2) and after (3) 1α OH vitamin D_3 treatment

	Age at start of treatment	Duration of dialysis before treatment (months)	Osteoporosis of the spine			Subperiosteal erosions			Soft tissue calcifications			(D−d)/D		
			1	2	3	1	2	3	1	2	3	1	2	3
	_7	23	+	+	+	−	++	+	−	−	−	0 76	0 76	0 73
	39	11	+	+	+	−	+	+	−	+	+++	0 80	0 80	0 80
	34	57	−	+	+	+	+++	+++	+	−	−	0 81	0 79	0 77
	53	24	−	+	+	−	+	+	+	+++	+++	0 85	0 82	0 78
	40	76	+	+	+	−	+	−	+	++	+++	0 82	0 79	0 80
	51	8	−	+	+	−	−	−	+	+++	+++	0 91	0 91	0 90
	23	51	−	++	++	−	++	++	−	++	+	0 72	0 65	0 69
	2?	43	−	+	+	−	−	−	−	−	−	0 79	0 72	0 73
n	36											0 81	0 78	0 78

EMA et coll 1972) The subperiosteal resorption ne of the most common skeletal abnormalities EMA et coll 1978) and can be divided into sub osteal intracortical and endosteal resorption Of se subperiosteal resorption is a nearly patho nomic sign of hyperparathyroidism (GENANT et coll 1975) In the present series 8 of 20 patients %) developed subperiosteal erosions during dia This is in accordance with the findings of IEN et coll (1970) who observed a relation be en the duration of dialysis and the development ubperiosteal bone resorption

ittle information is available about the effects of OH vitamin D_3 on the radiologic bone lesions in ients with severe renal failure Previously re ssion of rachitic lesions was observed in chil n and adolescents (NIELSEN et coll 1976 NDERSON et coll JOHANNSEN et coll) and of periosteal erosions in some adults (DAVIE et coll 76 JUNOR et coll PIERIDES et coll) following OH vitamin D_3 treatment An improvement of becular bone remodelling and biochemical anges has been found most evident in patients th marked histologic and biochemical abnormali s (NIELSEN et coll 1977) In the present series the diologic signs of renal osteodystrophy progress during dialysis became stationary or showed a ndency to regression during treatment with 1α droxy vitamin D_3 However in 4 of 6 patients the pearance of the subperiosteal erosions was un anged at completion of treatment

The present results indicate that uremic bone lesions increase or are unchanged during chronic hemodialysis whereas both the present and previous results (HENDERSON et coll NIELSEN et coll 1977) seem to indicate that treatment with 1α OH D_3 and phosphate binder may prevent the progression of radiologic biochemical and morphometric bone lesions or even improve them in patients on chronic hemodialysis

SUMMARY

Radiologic bone lesions in 20 long term hemodialyzed patients with chronic renal failure are described During chronic dialysis the bone lesions increased Treatment of 8 patients with 1α OH D_3 for 6 months prevented progression of the bone lesions or improved them

ACKNOWLEDGEMENT

1α hydroxy vitamin D_3 was kindly supplied by Leo Pharmaceutical Products Copenhagen Denmark

REFERENCES

BRICKMAN A S SHERRARD D J JOWSEY J SINGER F R BAYLINK D J MALONEY N MASSRY S G NORMAN A W and COBURN J W 1 25 dihydroxy cholecalciferol Effect on skeletal lesions and plasma parathyroid hormone levels in uremic osteodystrophy Arch intern Med 134 (1974) 883

COHEN M E L COHEN G F AHAD V and KAYE M Renal osteodystrophy in patients on chronic haemodialysis A radiological study Clin Radiol 21 (1970) 124

DAVIE M J W CHALMERS T M HUNTER J O PELC B

and KODICEK E 1 alpha hydroxycholecalciferol in chronic renal failure Studies of the effect of oral doses Ann intern Med 84 (1976) 281

DEQUEKER J Quantitative radiology radiogrammetry of cortical bone Brit J Radiol 49 (1976) 912

GARN S M POZNANSKI A K and NAGY J M Bone measurement in the differential diagnosis of osteopenia and osteoporosis Radiology 100 (1971) 509

GENANT H K KOZIN F and BEBERMAN G The reflex sympathetic dystrophy syndrome Radiology 117 (1975) 21

HENDERSON R G KANIS J A LEDINGHAM J G G OLIVER D O RUSSELL R G G SMITH R and WALTON R J Comparative effect of 1α hydroxy cholecalciferol in children and adults with renal glomerular osteodystrophy *In* Proceedings of the XIth *European Symposium on Calcified Tissues p 221* F A D L Publishing Company Copenhagen 1975

HOLIC M F SEMMLER E J SCHNOES H K and DE LUCA H F 1α hydroxy derivative of vitamin D_3 a highly potent analog of 1α 25 dihydroxy vitamin D_3 Science 180 (1973) 190

JOHANNSEN A NIELSEN H E and HANSEN H E Bone maturation in children with chronic renal failure Effect of 1α hydroxy vitamin D_3 and renal transplantation Acta radiol Diagnosis 20 (1979) 193

JOHNSON C GRAHAM C B and CURTIS F K Roentgenographic manifestations of chronic renal disease treated by periodic hemodialysis Amer J Roentgenol 101 (1967) 915

JUNOR B J R CATTO G R D MACLEOD M PAPAOULOS S E O RIORDAN J L H and FRASER R A 1 alpha hydroxycholecalciferol in the treatment of renal osteodystrophy *In* Proceedings of the Thirteenth Congress of the European Dialysis and ... plant Association p 424 Edited by B H B Rob... Pitman Publishing Company England 1976

MAWER E B BACKHOUSE J TAYLOR C M LU... and STANBURY S W Failure of formation of ... hydroxycholecalciferol in chronic renal insuff... Lancet I (1973) 626

MEEMA H E OREOPOULOS D G and MEEM... roentgenologic study of cortical bone resorp... chronic renal failure Radiology 126 (1978) 67

— RABINOVICH S MEEMA S LLOYD G ... OREOPOULOS D G Improved radiological diag... azotemic osteodystrophy Radiology 10? (197?)

NIELSEN H E MELSEN F CHRISTENSEN ... HANSEN H E RODBRO P and JOHANNSEN ... hydroxycholecalciferol treatment of long term dialyzed patients Effects on mineral met... bone mineral content and bone morphometr... Nephrol 8 (1977) 429

NIELSEN S P BINDERUP E GODTFREDSEN ... JENSEN H and LADEFOGED J 1α hydro... calciferol Long term treatment of patients w... mic osteodystrophy Nephron 16 (1976) 359

PIERIDES A M ELLIS H A SIMPSON W DEW... WARD M K and KERR D N S Variable res... long term 1α hydroxycholecalciferol in haem... osteodystrophy Lancet I (1976) 1092

RESNICK D and NIWAYAMA G Subchondral reso... bone in renal osteodystrophy Radiology 11... 315

WELLER M EDEIKEN J and HODES P J Ren... dystrophy Amer J Roentgenol 104 (1968) ...

)M THE DEPARTMENT OF DIAGNOSTIC RADIOLOGY MUNICIPAL HOSPITAL OF AARHUS THE DEPART
NTS OF RHEUMATOLOGY AND THEORETICAL STATISTICS INSTITUTE OF MATHEMATICS UNIVERSITY OF
AARHUS DK 8000 AARHUS DENMARK

EVALUATION OF THE PROGRESSION OF RHEUMATOID ARTHRITIS

Significance of age at onset and sex

A DE CARVALHO H GRAUDAL and B JØRGENSEN

present report is part of an investigation of ognosis and progression of rheumatoid joint e based on radiography of all limb joints the iliac joints and the cervical spine of each indi in a group of patients with rheumatoid ar

Previous reports on the prognosis of iatoid arthritis have been based on clinical ation and radiography of selected joints How for many joints the extent of joint involvement rheumatoid process is not known

e radiologic appearance of rheumatoid joint in :ment is complex In order to provide a stand lescription a scoring system has been used in :miologic investigations (University of Man ter) Further a more elaborate grading system linical use has been evolved by LARSEN (1973) modified by LARSEN et coll (1977) The prog s of each joint in terms of the percentage of s presenting the grades 0 1 2 3 4 or 5 respec y at a given time after the onset of the disease ɔeen described elsewhere (DE CARVALHO et coll ı) In order to compare various clinical and lab ory parameters with the radiologic progression latter should preferably be expressed numerical The aim of the present report is to evaluate the gression of rheumatoid arthritis and to relate the ologic progression to the age of the patients at onset of the disease and the sex

Material and Methods

The series consisted of 188 patients with definite or classical rheumatoid arthritis (ROPES et coll 1958) who had been treated in an arthritis clinic and followed for 3 to 12 years No seronegative patient had psoriasis only two men and one woman both seropositive had psoriasis The clinical examination of the patients was performed by the same physician (H G)

During the period of observation radiography of all limb joints the cervical spine and the sacro-iliac joints was carried out on at least two occasions giving a total of 429 examinations In another 232 examinations some but not all joint regions were examined and in some cases films were not available at the time of the analysis The average interval between the two examinations was 3½ years

At least two projections of the joints were used with the exception of the tarsus which was examined only in the lateral projection All films were evaluated by the same radiologist (A C) with out knowledge of the clinical findings According to the system used (LARSEN et coll) the joints were graded by a comparison with standard films Six grades were defined denoted by the figure 0 to 5 as follows

Submitted for publication 21 June 1979




Fig 1 Development from grade 2 to grade 5 in the same knee

Grade 0 normal findings

Grade 1 slight abnormality including periarticular soft tissue swelling juxta articular osteo pororsis possibly with slight narrowing of the joint space

Grade 2 early bone erosion and distinct narrowing of the joint space In weight bearing joints a distinct narrowing of the joint space without evident bone erosion was also classified as grade 2

Grade 3 medium destruction marked narrowing of joint space and bone erosion also of weight bearing joints

Grade 4 severe destruction only minor pa the articular surfaces left

Grade 5 mutilating changes with complet struction of the articular surfaces

The appearances of grades 2 to 5 in the same at different occasions are illustrated in Fig 1

Special problems occurred in the evaluation sacro iliac joints and the cervical spine ther these regions will be discussed separately The joints were divided into 20 groups (Table I) comprising joints with uniform progression of disease (DE CARVALHO et coll)

Only distinct joint abnormalities corresp

Table 1

Relationship between age and sex and involvement in different joint groups

	Age at onset ≥41 years		Women	
	Degree of divergence	p<	Degree of divergence	p<
Shoulder	0	0.3	0	0.9
Elbow	−2	0.02	0	0.6
Wrist	0	0.1	0	0.4
CMC 1	0	0.15	+2	0.04
CMC 2–5	0	0.3	+1	0.3
MCP 1	0	0.25	+1	0.1
MCP 2–5	−1	0.025	+2	0.025
Fingers PIP 2–5	0	0.2	+1	0.2
Fingers DIP 2–5	+3	0.0005	+1	0.03
Thumb IP joint	0	0.5	+3	0.0005
Hip	0	0.9	E	0.06
Knee	E	0.05	0	0.7
Ankle	+1	0.09	0	0.3
Tarsus	0	0.975	0	0.08
Midtarsal joints	0	0.6	0	0.4
MTP 1	0	0.25	+1	0.15
MTP 2–5	0	0.9	0	0.2
Toes PIP 2–5	0	0.5	0	0.5
Toes DIP 2–5	+2	0.005	0	0.15
Hallux IP joint	0	0.3	−1	0.2

CMC Carpometacarpal joint MCP Metacarpophalangeal joint PIP Proximal interphalangeal joint DIP Distal interphalangeal joint IP Interphalangeal joint MTP Metatarsophalangeal joint

least grade 2 were taken into account because grade 1 by definition corresponds to questionable abnormalities For statistical purposes the weight of 0 was attached to grades 0 and 1 while the weights 1 to 4 were used for grades 2 to 5 respectively For each individual group of joints the mean weight of all joints was calculated for each examination This mean was termed the degree of involvement of the groups of joints concerned As regards the groups of patients a mean degree of involvement was calculated for each group of joints examined at the same time after the onset of the disease For this purpose the duration of the disease was divided into periods each of one year when the duration was 1 to 13 years With longer durations the periods were 14 to 15 16 to 17 18 to 20 and 21 to 25 years A general view of the progression of the disease in a group of joints/group of patients was obtained by plotting the degree of involvement against the duration of the disease

When the patients had been divided into an interest group and a control group the differences in the progression of the disease in the two groups could be evaluated If the degree of involvement was plotted against the duration of the disease a curve was obtained which flattened with increasing time The degree of involvement was found to be an approximately linear function of the square root of the duration of the disease (Fig 2) As regards a given group of joints differences between two groups of patients may be evaluated statistically by means of linear regression analysis In each group of joints/group of patients the variance of the degree of involvement depends on the duration of the disease and may be described as a linear function of the latter A typical example is given in Fig 3 This linear relationship was estimated by means of the program GLIM (NELDER 1975) The two regression lines which denote the progression of the disease in two groups of patients were assessed by using the estimates of the variances as if they were known In Figs 4 and 5 the regression lines are drawn The

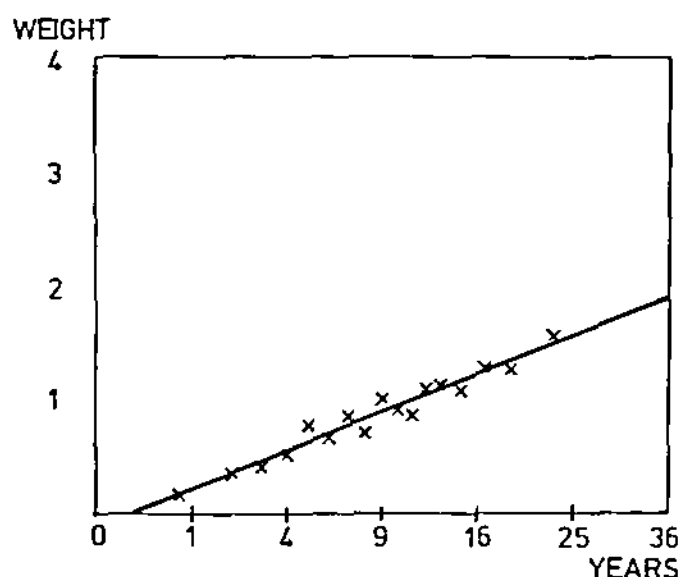


Fig 2 Average degree of involvement of all joints in the series of patients as a function of the square root of the duration of the disease Linear relationship

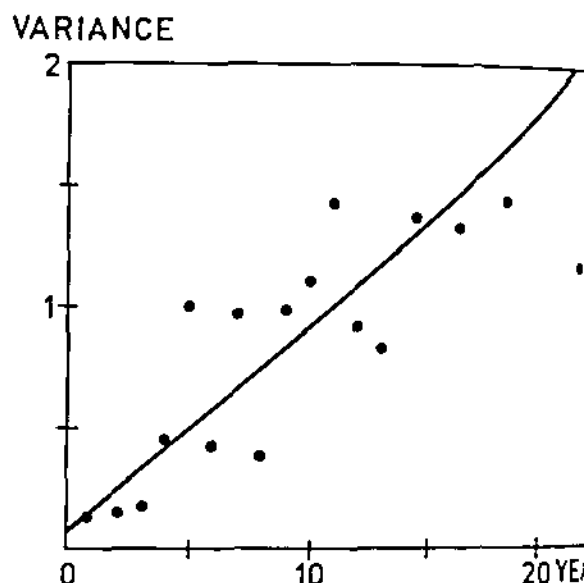


Fig 3 Change of the variance as a function of the duration disease for a typical group of joints/group of patients The ance may be described by a linear function of the duration disease

usual statistical test for identity of two regression lines with known variances has a χ^2 distribution with two degrees of freedom This test allows for the fact that the number of examinations in each period varied Certain conditions for the use of regression analysis were not fulfilled Thus the same patient appeared several times during the period of observation and rheumatoid arthritis can only become worse or go into remission but on the whole radiologic abnormalities do not disappear Moreover the degree of involvement is described by means of a discreet variable Although the method applied seems to be reasonably safe it was felt that the progression in each group of joints in two groups of patients had to be compard also by viewing the graph directly This was expressed on a scale ranging from 0 to 4 0 signifying no difference and 4 two completely separate courses An equivocal result was also denoted In each case this was done by comparing the graphic distributions (Fig 4) with the degree of divergence in order to avoid p-values created by extremely marginal issues that were obvious when viewing the graphic representation of the distribution Such results were denoted equivocal The degrees of divergence 2 and 3 appear in Fig 4 The sign + means that the relevant factor was related to distinctly more severe involvement of the joint in question as compared with the controls (Table 1) whereas the opposite is denoted by the sign − (Fig 5)

Results

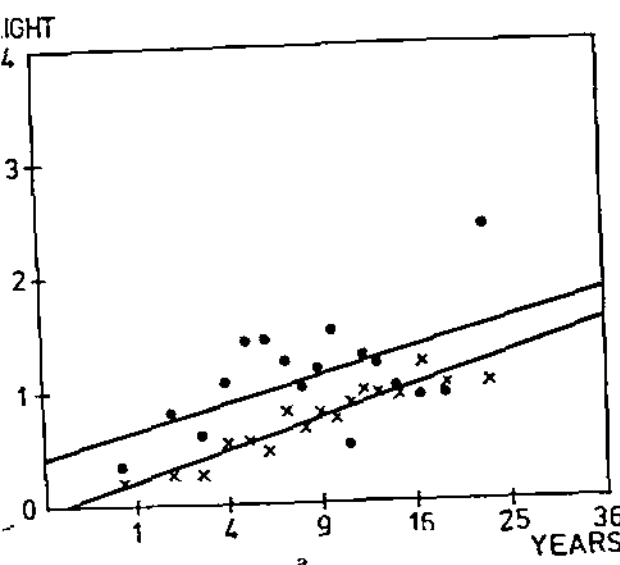
The relation between age and sex and the d of involvement was not the same for different g of joints If a patient was more than 40 years the onset of the disease a relation was evide tween the higher age and more severe involve of the following joints the distal interphal joints 2–5 of the fingers and toes and the ankle j A distinct relation existed to less severe inv *ment of the elbow joints and of the met* pophalangeal joints 2–5 In the other groups of j no relation to the age of the patient was found I knee joints the finding was equivocal since the gression lines intersected each other

The involvement was higher in women in the lowing groups of joints metacarpophalangeal j 2–5 the distal interphalangeal joints 2–5 of the gers the interphalangeal joint of the thumb and joint between the trapezium bone and the base of first metacarpal bone In the other joints no dist difference in the progression was found In the l joint the finding was equivocal with intersecting gression lines

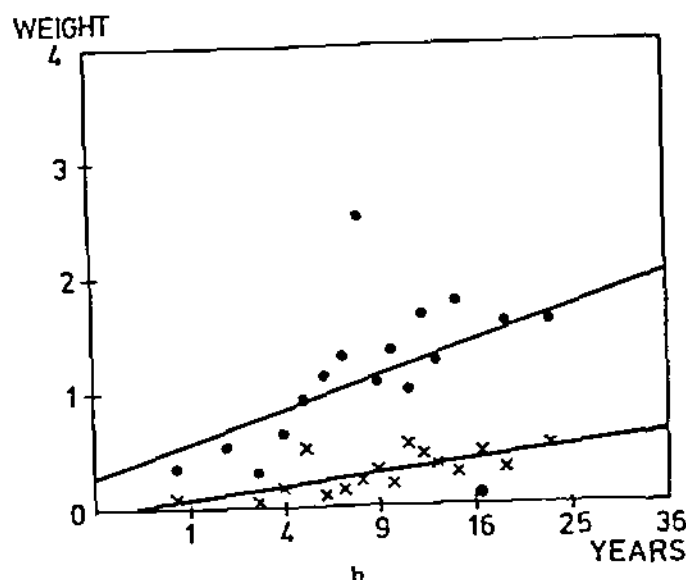
The size and composition of the groups appea Table 2

Discussion

The method applied gives results which ca reproduced and used as the basis for a compar

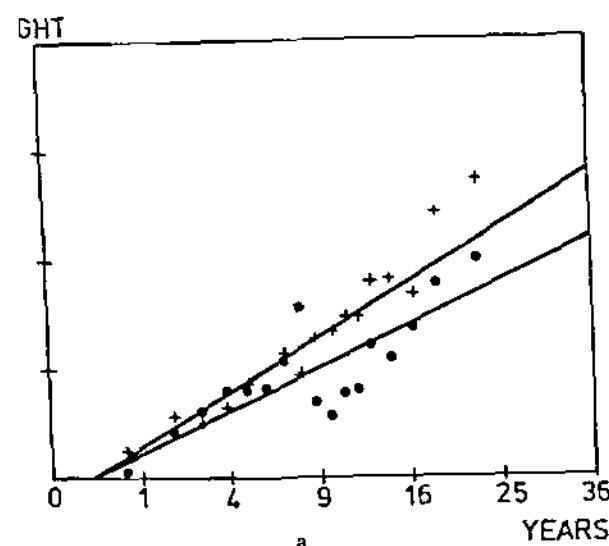


a

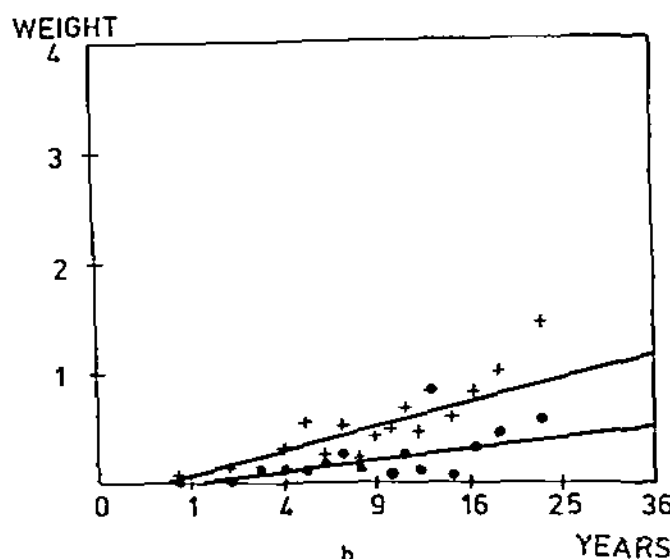


b

Degree of divergence a) 2 and b) 3 between ? groups of its



a



b

g 5 Relation between sex and degree of involvement Women gree of divergence a) + 2 in the metacarpophalangeal joints 2–5 ($p<0.025$) and b) + 3 in the interphalangeal joint of the thumb ($p<0.0005$) + Women ● Men

f results from different centres as it is founded on well-defined classification criteria and a relatively imple statistical method An analysis shows that he importance of the factors tested differs in each roup of joints

The age at the onset of the disease is of less nportance for the long range prognosis if the latter estimated on the basis of the radiologic progres ion in most limb joints The more favourable prog osis found for elbow joints and metacar ophalangeal joints at a late onset of the disease might be due to a smaller stress on these joints in old people As regards the distal interphalangeal joints a definitely less favourable prognosis was found to be associated with a late onset of the disease In elderly patients the distal interphalangeal joints of the fin gers are most frequently also affected by osteoar throsis In the present series erosive lesions alone were recorded and it is noteworthy that lesions in the distal joints of the toes were also found The joints of the hand and fingers in women seem to have a less favourable prognosis than in men No other difference was found as regards the prognosis The results cannot be directly compared with those of

Table 2

Size and composition of the groups (cf Table 1)

	Age at onset ≥41 years	Women
Percentage of examinations	49 3	80 3
Percentage of patients	52 1	79 3
Number of radiologic examinations	661	661
Number of examinations determining each point of the regression lines		
Larger group		
Minimum	10	15
Maximum	28	40
Smaller group		
Minimum	3	4
Maximum	30	12

other reports which have based the prognosis on the clinical findings estimated functional state or examinations of selected groups of joints

It has been reported that the prognosis is better for patients who are under the age of 40 at the onset of the disease (SHORT & BAUER 1948 DUTHIE et coll 1964 SHORT 1968 FLEMING et coll 1975 1976 KEITEL & UHLE 1976) but the opposite view has also been advanced (RAGAN & FARRINGTON 1962)

It has also been stated that the prognosis is better for men than for women (SOILA 1958 BYWATERS et coll 1960 DUTHIE et coll SHORT) which however has not been confirmed by RAGAN & FARRINGTON or SHARP et coll (1971)

It is possible that an evaluation of the prognosis may differ in short and long observation periods The prognosis for the functional state depends on several factors and not only on the anatomic state of the joints

SUMMARY

The limb joints of 188 patients with rheumatoid arthritis were classified according to the LARSEN scoring system The mean degree of involvement was approximately a linear function of the square root of the duration of the disease A mild course in the elbows and metacarpophalangeal joints and a severe course in the distal interphalangeal joints of the fingers and toes were related to age over 40 years at onset of the disease A severe course in most joints of the hands occurred in women

ACKNOWLEDGEMENT

The authors wish to express their gratitude to A ... Holst Andersen advisory statistician for invaluable ... tance This investigation has been supported by a g... from the Danish Medical Research Council

REFERENCES

BYWATERS E G L CURWEN M DRESNER E and D... A St J Ten years follow up of rheumatoid arth... Lancet II (1960) 1381

CARVALHO A DE GRAUDAL H and JORGENSEN ... Radiologic evaluation of the progression of rheu... arthritis Acta radiol Diagnosis 21 (1980) 115

DUTHIE J J R BROWN P E TRUELOVE L... BARAGAR F D and LAWRIE A J Course and p... nosis in rheumatoid arthritis A further report ... rheum Dis 23 (1964) 193

FLEMING A CORBETT M and CROWN J The rela... of early features to prognosis in rheumatoid d... Scand J Rheumatol (1975) Suppl No 8

— CROWN J M and CORBETT M Early rheumato... ease Ann rheum Dis 35 (1976) 357

KEITEL W und UHLE R Zur Progredie... Rheumatoid Arthritis Z ges inn Med 31 (197...

LARSEN A *Radiological grading of rheumatoid a...* Scand J Rheumatol 2 (1973) 136

— DALE K and EEK M Radiographic evalua... rheumatoid arthritis and related conditions by st... reference films Acta radiol Diagnosis 18 (197...

NELDER J A GLIM manual Second edition Th... merical Algorithms Group Oxford 1975

RAGAN C and FARRINGTON E The clinical fea... rheumatoid arthritis Prognostic indices J Am... Ass 181 (1962) 663

ROPES M W BENNETT G S COBBS S JACOX... JESSAR R A 1958 revision of diagnostic crit... rheumatoid arthritis Bull rheum Dis 9 (1958)

SHARP J T LIDSKY M D COLLINS L C and LAND J Methods of scoring the progress... radiologic changes in rheumatoid arthritis Art... Rheum 14 (1971) 706

SHORT C L Rheumatoid arthritis Types of cour... prognosis Med Clin N Amer 52 (1968) 549

— and BAUER W The course of rheumatoid arth... patients receiving simple medical and orthopedic... ures New Engl J Med 230 (1948) 14...

SOILA P Roentgen manifestations of adult rhe... arthritis Acta rheum scand (1958) Suppl No 1

The epidemiology of chronic rheumatism First e... Vol II p 24 The Department of Rheumat... Medical Illustration University of Manches... Manchester Royal Infirmary and the E... Rheumatism Council s Field Unit Blackwell Sci... Publications Oxford 1963

Acta Radiologica Diagnosis 21 (1980) Fasc 4

OM THE DEPARTMENT OF DIAGNOSTIC RADIOLOGY MUNICIPAL HOSPITAL OF AARHUS AND THE DEPART
MENT OF RHEUMATOLOGY UNIVERSITY OF AARHUS DK-8000 AARHUS DENMARK

RADIOGRAPHIC PROGRESSION OF RHEUMATOID ARTHRITIS RELATED TO SOME CLINICAL AND LABORATORY PARAMETERS

A DE CARVALHO and H GRAUDAL

Whether a relation exists between some clinical d laboratory parameters and the progression of umatoid arthritis as evaluated radiologically has n investigated The basic method of evaluation s described previously (DE CARVALHO et coll 30 b)

The literature contains reports on the possible ation between clinical and laboratory parameters d the functional state or the course of the disease individual joints and groups of joints However similar report taking into account all limb joints luated by uniform criteria seems to have been plished

Material and Methods

The material consisted of 188 patients with defi e or classical rheumatoid arthritis (ROPES et coll 58) who had been treated and followed in an ar ritis clinic for 3 to 12 years The patients were amined clinically by the same physician (H G) uring this period radiography of all limb joints was rformed at least twice giving a total of 429 exami ations and of some but not all joints in 232 exami ations The average interval between two examina ons was 3 5 years In connection with the radio aphic examination several laboratory parameters ere determined The radiologic evaluation was rformed by means of uniform criteria by the same diologist (A C) who was without knowledge of e clinical and laboratory parameters A classifica on into 6 grades according to the scoring system of ARSEN (LARSEN et coll 1977 DE CARVALHO et oll 1980 a) was used for all limb joints Previously e basis of the formation of the groups of joints and the statistics applied have been explained (DE CARVALHO et coll 1980 a b) The factors with possible relation to the progression of rheumatoid arthritis in the individual groups of joints appear in Table 1 The latex fixation test the Rose Waaler reaction and reactions for organ non specific (ON) and granulocyte specific (GS) anti nuclear antibodies (ANA) were performed at Statens Seruminstitut Copenhagen Positive latex test corresponds to about 5 IU/ml of the international reference preparation of rheumatoid arthritis serum (ANDERSON et coll 1970) The Rose Waaler reaction was performed as a sensitized sheep cell agglutination test modified as described by BICHEL et coll (1957) and changed in 1973 into a micro titration giving concordant results Test for ANA were performed as described by FABER & ELLING (1965) and ELLING et coll (1967) Human thyroid tissue as the antigen was replaced in 1975 by rat liver for the determination of ON ANA

Results

Subcutaneous nodules at least on one occasion were associated with a slightly more severe progression in the metacarpo phalangeal and metatarso phalangeal joints 2–5 and in the interphalangeal joint of the big toe A relation existed to less severe involvement in the carpo metacarpal joints 1–5 but not the progression in any other joint (Fig 1)

A high (≥41 mm/h) or a very high (≥91 mm/h) ESR (Fig 2) on at least one occasion was related to more severe degrees of involvement in all joints

Submitted for publication 21 June 1979

Table 1

Factors investigated in relation to course of rheumatoid arthritis in each joint group

Group with positive findings	*Controls*
Presence of subcutaneous nodules at least once	No nodules
ESR ≥41 mm/h at least once	ESR <41 mm/h
ESR ≥91 mm/h at least once	ESR <91 mm/h
Rheumatoid factor present Latex test or Rose Waaler test positive at least once	Rheumatoid factor absent
Latex test and Rose Waaler test both positive at least once	Both tests negative or only one test positive
Titre of the Rose Waaler test >160 at least once	Titre ≤160
Titre of the Rose Waaler test ≥640 at least once	Titre <640
ON ANA present (+ ++ +++) at least once	ON ANA absent
ON ANA +++ at least once	ON ANA absent + or ++
GS-ANA present (+ ++ +++) at least once	GS ANA absent
GS ANA +++ at least once	GS ANA absent + or ++

The positivity of the rheumatoid factor defined by either a positive latex test or a positive Rose Waaler reaction on at least one occasion was clearly related to a severe progression (Fig 3) However the distal interphalangeal joints of the fingers and toes and the interphalangeal joint of the thumb were exceptions No relation seemed to exist between the progression in those joints and posivity of both the latex fixation test and the Rose Waaler reaction and this was also the case with the metacarpo phalangeal joint 1 and the carpo metacarpal joint 1

The high titres of the Rose Waaler reaction were clearly related only to the more severe type of progression in the ankles and in all metatarso phalangeal joints 1–5 but not to the progression in the other joints (Fig 4)

Positive ON ANA was not evidently related to the progression in the groups of joints (Fig 5) except the metacarpo phalangeal joints 2–5 and the metatarso phalangeal joints 2–5

Strong positivity of GS ANA (Fig 6) on one occasion was clearly related to severe degrees of involvement in most groups of joints except the distal interphalangeal joints of the fingers and toes the metacarpo phalangeal joint 1 and the metatarso phalangeal joint 1 Positivity of GS ANA wa related to the degree of involvement in the hi carpo metacarpal joint 1 and the wrist

The composition of the groups of patients and controls and the number of examinations perfor appear from Table 2

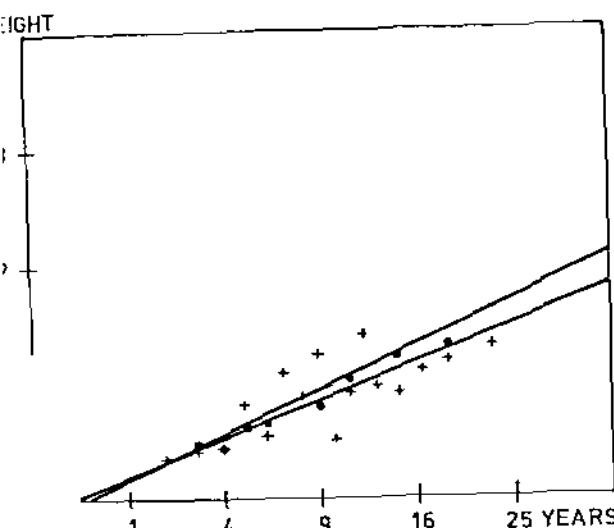
Discussion

To the more severe prognosis of rheumatoid tor positive rheumatoid arthritis compared wi seronegative is well known The present data cate that this statement is valid for any limb with the exception of the distal interphala joints of the fingers and toes and the interphal joint of the thumb

The general absence of a positive relatio tween the nodules and more rapidly progr joint involvement might be surprising (DUTH coll 1964 SHORT 1968 KEITEL & UHLE 19 may be explained by the fact that as a rule no are associated with high titres of the rheum factor In the present series more progressi thritic disease was related to the characterist rheumatoid factor positivity and not to high This means that there may be a dissociation be progressive joint disorder and the extra a nodules The slight relation of nodules to the rapidly progressive involvement of the meta phalangeal and metatarso phalangeal joints gests that such a dissociation is not complete

High or very high values of ESR on at lea occasion was evidently related to more seve grees of radiologic progression which does agree with previous reports (BROWN & D 1958 JACOBY et coll 1973)

The slight or absent positive relation of ANA to rapidly progressing joint involv seems to be in accordance with the fact that ANA typically occurs in systemic l erythematosus and often in the pauci articul of juvenile chronic arthritis in which diseases gressive erosive joint disorder is unusual nodules ON ANA is more clearly related to volvement in metacarpo phalangeal and meta phalangeal joints than in other joints ANA ha related to extra articular features of rheuma thritis (WARD et coll 1964) but no previous inf tion about the relation of ANA to the progre joint involvement seems to be available



elation between the progression in the proximal inter al joints 2–5 of the fingers and the presence on at least sion of subcutaneous nodules (+) Controls (●) Degree ence 0 (p<0 4)

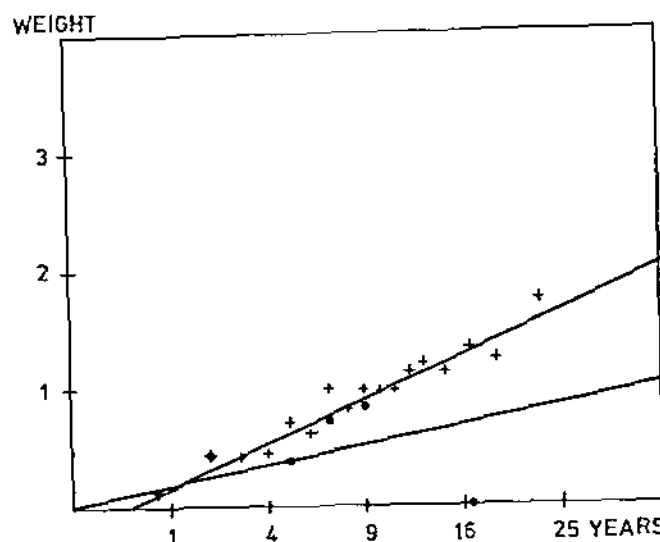
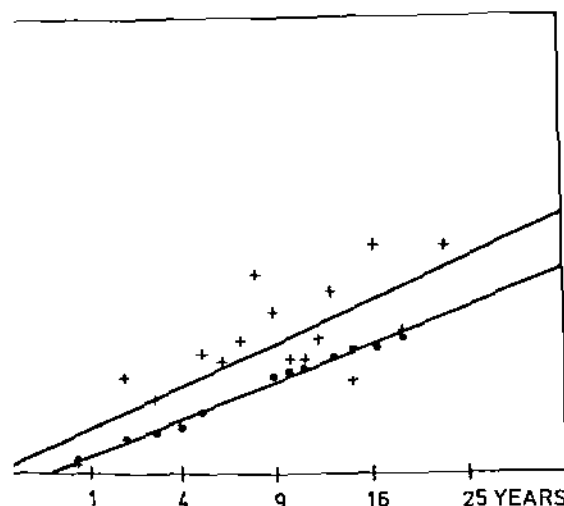


Fig 3 Relation between the progression in the proximal inter phalangeal joints 2–5 of the fingers and positivity of the rheumatoid factor (+) Controls (●) Degree of divergence +2 (p<0 001)



Relation between the progression in the proximal inter ngeal joints 2–5 of the fingers and high ESR ≥91 mm/h (+) least one occasion Controls (●) Degree of divergence + 01)

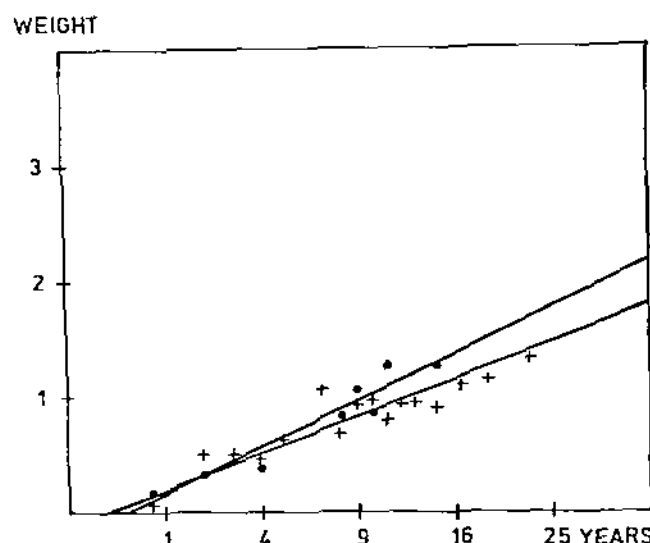


Fig 4 Relation between the progression in the proximal inter phalangeal joints 2–5 of the fingers and a high titre of the Rose Waaler test (+) on at least one occasion Controls (●) Degree of divergence −1 (p<0 2)

S ANA behaved quite differently It occurs nly in rheumatoid sera (67% ELLING et coll) present data suggest that a strong reaction for ANA may be related to a serious prognosis as rds joint erosions

oncerning individual groups of joints some of n are related to the factors analysed in a way that ers from other joints Thus the distal inter langeal joints seem to constitute a particular up in which the course of the disease is related neither to the rheumatoid factor nor to GS ANA A more severe progression of their involvement is in stead related to a late onset of the disease (DE CARVALHO et coll 1980 b) These joints are rarely se verely involved grade 3–5 after 11 to 12 years of disease occurring in the fingers in 8 per cent and in the toes in only one per cent (DE CARVALHO et coll 1980 a) This involvement is not associated with psoriasis and represents probably not erosive os teoarthritis since it is related to a very high ESR

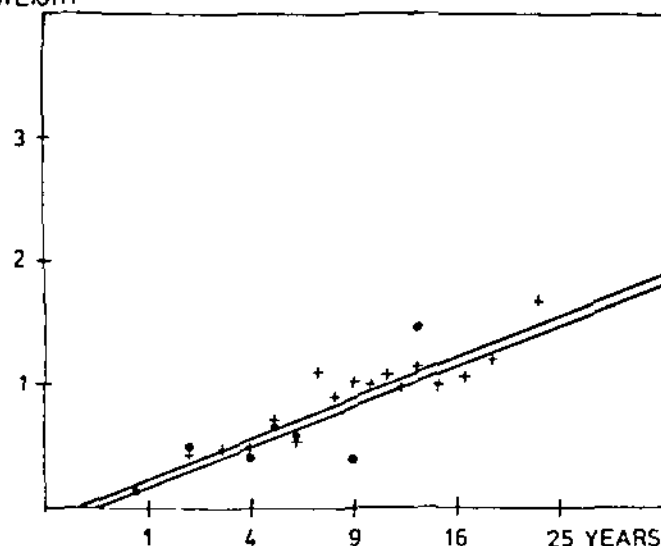


Fig 5 Relation between the progression in the proximal inter phalangeal joints 2–5 of the fingers and positivity of ON ANA (+) on at least one occasion Controls (●) Degree of divergence 0 (p <0 7)

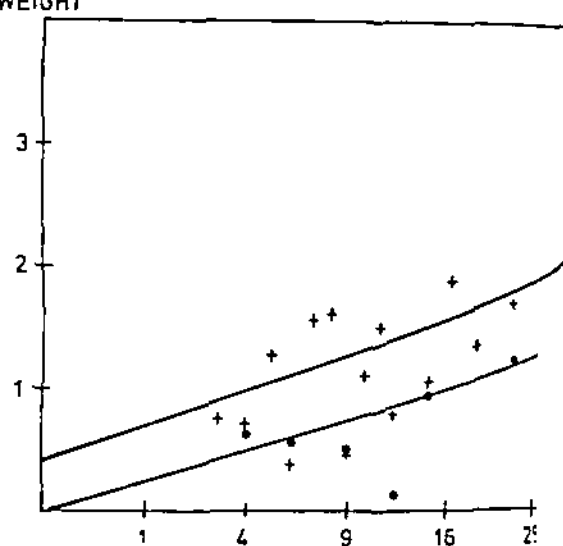


Fig 6 Relation between the progression in the proxi phalangeal joints 2–5 of the fingers and strong positivity GS ANA (+) Controls (●) Degree of divergence +? (p

The interphalangeal joint of the thumb behaves simi larly to the distal interphalangeal joints and is also rarely severely involved after 11 to 12 years grade 3–5 in 12 per cent (DE CARVALHO et coll 1980 a)

Regarding the metacarpo phalangeal joint of the thumb and the joints of the big toe the course is related to the rheumatoid factor and not to GS ANA but their degree of involvement follows the common development (DE CARVALHO et coll 1980 a)

In spite of a relation to both the rheumatoi and GS ANA some joints are seldom seve fected In the hips the ankles and the p interphalangeal joints of the toes lesions of to 5 occur in 17 16 and 6 per cent respective 11 to 12 years (DE CARVALHO et coll 1980 markable relation exists between a severe p sion in the hip joints and positivity or strong ty of GS ANA and between a severe progre the ankle joints and very high Rose Waaler t

Table 2

Composition of groups of patients and number of examinations

Factor	Percentage of examinations	Percentage of patients in relation to controls	No of radiologic examinations of the skeleton	No of examinations determining each point of the regression lines			
				Larger group		*Smaller group*	
				Min	Max	Min	Max
Nodules	43	43 1	661	11	34	10	4
ESR ≥41 mm/h	72	68 6	661	15	38	[illegible]	17
ESR ≥91 mm/h	18 5	16	661	20	44	[illegible]	10
Rheumatoid factor present	90 4	91 4	661	23	48	1	7
Rose Waaler and latex test positive	83 8	8[illegible] 4	661	[illegible]	43	[illegible]	1
Rose Waaler titre >160	56 6	53 [illegible]	661	1[illegible]	31	9	[illegible]
Rose Waaler titre ≥640	39 9	37 8	661	13	35	8	0
ON ANA present	21 3	25 2	555	14	35	3	0
ON ANA +++	[illegible]6 3	[illegible] 5	354	8	2[illegible]	[illegible]	10
GS ANA present	93 5	88 9	417	14	28	1	4
GS ANA +++	54 4	46 0	149	1	9	[illegible]	10

SUMMARY

n 188 patients followed for 3 to 12 years the radiologic irse of rheumatoid arthritis was assessed in 20 joint ups A severe course in most joints was related to the sence of rheumatoid factor and to high values of the R Granulocyte specific antinuclear antibodies were re d to a severe course in most joints The presence of lules the Rose Waaler titre and the presence of organ i specific antinuclear antibodies were generally unre d to the course of the disease

ACKNOWLEDGEMENT

The authors wish to express their gratitude to Anders Andersen and Bent Jorgensen advisory statisti for invaluable assistance This investigation has supported by a grant from the Danish Medical Re h Council

REFERENCES

ERSON S G BENTZON M W HOLBA V and KRAG International reference preparation of rheumatoid rthritis serum Bull Wld Hlth Org 42 (1970) 311

IEL J HOLTEN C JENSEN K B and CHRISTENSEN S The Rose Waaler test with special reference to ancer Acta med scand 158 (1957) 351

WN P E and DUTHIE J J R Variations in the course of rheumatoid arthritis Ann rheum Dis 17 (1958) 159

VALHO A DE GRAUDAL H and JORGENSEN B (a) Radiologic evaluation of the progression of rheumatoid arthritis Acta radiol Diagnosis 21 (1980) 115

— — — (b) Evaluation of the progression of rheumatoid arthritis Significance of age at onset and sex Acta radiol Diagnosis 21 (1980) 545

DUTHIE J J R BROWN P E TRUELOVE L H BARAGAR F D and LAWRIE A J Course and prognosis in rheumatoid arthritis A further report Ann rheum Dis 23 (1964) 193

ELLING P GRAUDAL H and FABER V Organ specific and organ non specific auto-antibodies in rheumatoid arthritis Acta med scand 182 (1967) 707

FABER V and ELLING P Anti nuclear factors (ANF) as determined by the immuno fluorescent antibody technique Acta med scand 177 (1965) 309

JACOBY R K JAYSON M I V and COSH J A Onset early stages and prognosis of rheumatoid arthritis a clinical study of 100 patients with 11 year follow up Brit med J 2 (1973) 96

KEITEL W and UHLE R Zur Progredienz der Rheumatoid Arthritis Z gesamte inn Med 31 (1976) 490

LARSEN A DALE K and FEK M Radiographic evaluation of rheumatoid arthritis and related conditions by standard reference films Acta radiol Diagnosis 18 (1977) 481

ROPES M W BENNET G A COBB S JACOX R and JESSAR R A 1958 revision of diagnostic criteria for rheumatoid arthritis Bull rheum Dis 9 (1958) 175

SHORT C L Rheumatoid arthritis types of course and prognosis Med Clin Amer 52 (1968) 549

WARD D J JOHNSON G D and HOLBOROW E J Antinuclear factor in rheumatoid arthritis Its incidence and clinical significance Ann rheum Dis 23 (1964) 306

FROM THE DEPARTMENT OF ORAL RADIOGRAPHY UNIVERSITY OF UMEÅ S 90185 UMEÅ SWEDEN

REPRODUCIBLE POSITIONING OF THE SKULL AT TOMOGRAPHY

O ECKERDAL and P NELVIG

'hen a radiographic examination has to be re
ted identical projection and exposure variables
desirable for comparison with previous examina
is At radiography of the skull cephalostats of
erent kinds are in current use especially in
ntology where repeat examinations are fre
nt A thorough and standardized positioning on
ordinary skull table also results in a reproduci
'y sufficient for many clinical purposes The
ility of the reproducibility of the temporoman
ular joint at transcranial oblique examinations
been discussed by FROHLICH (1967) WEINBERG
70) BERGSTEDT & WICTORIN (1971) ECKERDAL
LUNDBERG (1975) and PETERSSON (1975) For
-aoral reproduction several kinds of utilities
st which on different ambition levels guarantee
roducible radiographic images

In clinical tomography of the skull a simple com
-table and preferably reproducible positioning and
ation method is needed The difficulties in ob
ning proper positioning and fixation increase
ien the examinations are time-consuming as for
ample in association with petrous bone radio
aphy (ROVSING 1970) Another problem is the
tricted area in relation to the examination table
thin which the tomographic plane may be local
-d At the polytome this plane may have a distance
23 cm from the table Such facts interfere with
ease in positioning of the patients The vibra
ns which are generated even in the best of tomo
aphs must also be considered when designing a
ad fixation system Every change of movement
rection will provoke vibrations

Fixation of the skull Three different positioning and fixation methods have been tested in clinical practice A conventional head fixation device with ear rods in the external auditory canal (cephalostat) a vacuum adhered device with head pads (Fig 1) and a pillow and fixation with ribbon The methods will be briefly commented upon and a description will be given of a simple orientation system in association with the third method

The cephalostat with ear rods has been used for patients in sitting position The experiences have not been wholly satisfactory The patients have felt discomfort from the rods due to the vibrations especially when the tube makes rapid changes of direction as in ellipsoid and hypocycloid movements If the fixation has been of long duration the patients may have changed position despite the fixation The clinical result and hence the reproducibility did not correspond to the sophisticated design of the fixation and the scales of the cephalostat The same reservation could be made for the vacuum adhered device which has been tested on patients in supine or prone position This utility also may be reset at identical scale values at repeated examinations However no means exist for deciding and preserving the relation between the skull and the cephalostat as when ear rods are used The precision of the scales does not correspond to the desired reproducibility It may also be noted that the metal constructions of both types of cephalostats may be disturbing in several respects also when estimating

Submitted for publication 2 May 1979

the positioning of desired tomographic layers The comfort of the patient may also be questioned In this respect the latter cephalostat is to be preferred

The third method for positioning and fixation was used with the intention of preserving the comfort of the patient and to obtain a reproducibility sufficient for most clinical situations A vacuum pillow (ORTAP Scandinavian AB Helsingborg) was used It proved to be valuable for choosing a suitable thickness of the pillow in order to individualize the head positioning The pillow was formed with a raised periphery in order to sustain and fix the skull However a reliable decision of the reference planes of a skull partly hidden by the pillow was difficult to make more so if the patient s hair was thick In order to facilitate the determination of the sagittal reference plane the patient was provided with a thin latex cap (Fig 2) on which the sagittal midline of the head was marked When the patient was placed on the pillow it was easy to determine the head orientation despite the fact that the skull was partially hidden With the aid of a perspex scale (Fig 2) it was possible to choose the desired angle of the head Other orientation planes were used to assure a three dimensionally reproducible positioning

The *reproducibility* of the positioning was tested with a head and neck phantom prepared with metal indicators placed in front of the auditory canal on each side of the skull The phantom was examined 10 times Between these it was withdrawn and the pillow air filled The orientation followed the clinical procedure The exposure was made with arrested tube and the central ray at 0 The resulting difference between the 10 examinations of the phantom is given in the diagram (Fig 3) The largest angle deviation between these repeated examinations was 4 9 The mean deviation was ±1 65

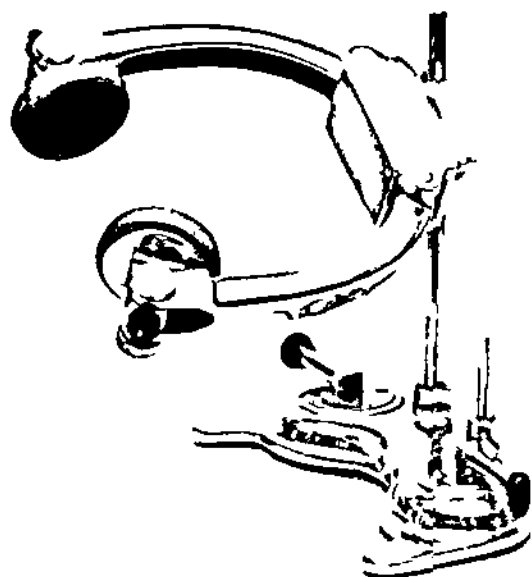


Fig 1 Head fixation device intended for patients in pr... tion

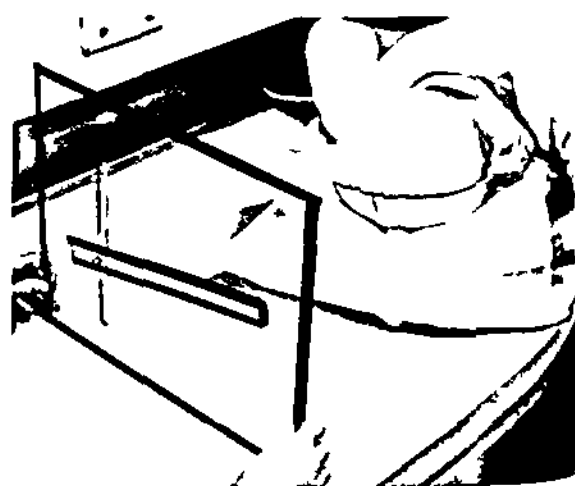


Fig 2 A patient s head with a thin latex cap with ... marked and fixed by the vacuum pillow The o... checked with the aid of a perspex scale

Discussion

An exact reproducibility is not obtained even if a cephalostat with ear rods is used (ELIASSON 1974) He obtained better results when light-cross orientation of the head was used SKAGIUS evaluated the relation of morphologic well-defined points in the skull to the image of the ear rods of the cephalostat He found a mean deviation between repeated examinations of 4 8 mm which was considered to be caused by elasticity in the lateral part of the external auditory canal and the fact that the rods often have a smaller diameter than the canal

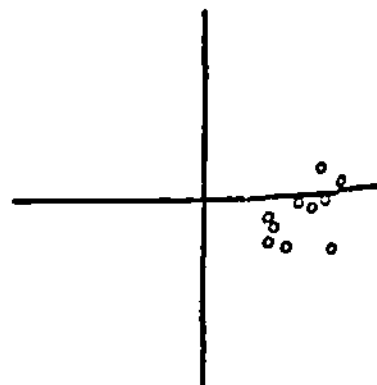


Fig 3 Difference between 10 examinations of the ph...

The vacuum pillow method has proved con nient in clinical use The precision may be com ired with that on an ordinary skull table The llow increases the attenuation as well as the sec dary radiation slightly but the quality of the ages is not appreciably impaired The small duction in quality is well compensated by fewer satisfactory examinations caused by small move nts by the patient because of uncomfortable posi ning and fixation

SUMMARY

Description of a method for obtaining sufficient repro ibility in odontologic examinations using a vacuum ow

Request for reprints Docent Olof Eckerdal The Insti e of Postgraduate Dental Education S 552 56 Jon ping Sweden

REFERENCES

RGSTEDT H and WICTORIN L The influence of the angle of projection on the linear error in cranio lateral radiography of the temporomandibular joint A method study Acta odont scand 29 (1971) 3

ECKERDAL O and LUNDBERG M Periodic roentgeno graphy of the temporomandibular joint Dento Maxillo Fac Radiol 4 (1975) 4

ELIASSON S Postural position of the mandible with special reference to instruction head fixation and relaxation Academic Thesis Stockholm 1974

FRÖHLICH F Zur Reproduzierbarkeit von Kiefergelenk rontgenbildern Schweiz Mschr Zahnheilk 77 (1967) 611

PETERSSON A Reproducibility of temporomandibular joint radiographs utilizing transmaxillary projection and oblique lateral transcranial projection with indi vidualized technique Dento Maxillo Fac Radiol 4 (1975) 85

ROVSING H Otosclerosis A tomographic—clinical study Acta radiol (1970) Suppl No 296

SKAGIUS S Personal communication

TVEITO L Beurteilung der Gelenkspaltbreite Dtsch zahnarztl Z 29 (1974) 550

WEINBERG L A An evaluation of duplicibility of tem poromandibular joint radiographs J prosth Dent 24 (1970) 512

A C T A R A D I O L O G I C A

21 5 DIAGNOSIS 1980

SPLENOMEGALY HYPERKINETIC SPLENIC FLOW AND PORTAL HYPERTENSION IN COLITIS

LEIF FRIMAN

Portal hypertension is most often caused by liver rhosis which gives rise to intrahepatic obstruction venous flow leading to the development of ve us collaterals which may cause life threatening morrhage In liver cirrhosis with obstruction of venous flow the portal flow is decreased the ceral venous blood flow is to some degree di ted from the liver through portocaval shunts In se cases with decreased portal flow the hepatic erial flow is usually increased (REUTER et coll 75 FRIMAN 1979) This fact can be explained by capacity of the liver for autoregulation of the erial hepatic flow (HANSON & JOHNSON 1966 OCK et coll 1972)

It is not so well known that increased visceral ood flow can be a cause of portal hypertension HIMPEI et coll (1972) described a man 38 years of e with capillary hemangiomatosis of the spleen id portal hypertension They considered the in eased splenic flow to be the cause of portal hyper nsion No collaterals were evident at angiography id no cirrhosis only fibrosis of portal tracts was und at repeated liver biopsy

A similar case was reported by PITLIK et coll 977) It was a 64-year-old woman with heman omatosis of the spleen and portal hypertension but ith large portocaval shunts A splenectomy was erformed and only a slight reduction in the portal ressure was recorded At autopsy a portal sclerosis as found probably caused by the hyperkinetic plenic flow leading to portal hypertension The ab sence of the expected decrease in portal pressure after the splenectomy could be explained by the portal sclerosis which may complicate all forms of portal hypertension (PITLIK et coll)

WILLIAMS et coll (1968) analysed the splenic blood flow in cirrhosis and portal hypertension by tissue clearance of radioactive xenon from the spleen They found the splenic flow to be increased which they considered to contribute to the elevation of the portal pressure However they were of the opinion that the level of pressure increase was main ly determined by the rise in the hepatic resistance

The splenic blood flow in 19 patients with en larged spleens mostly caused by hematologic dis eases as myelofibrosis polycytemia etc was anal ysed by GARNETT et coll (1969) using xenon tech nique They found increased flow in all cases and they postulated that the spleen acts as an arterio-venous fistula causing an abnormally high blood volume in these patients The total splenic blood flow accounted for 8 5 to 55 per cent (mean 22) of the cardiac output The portal pressure was not measured

VIAMONTE et coll (1970) performed balloon oc clusion of the splenic artery in one patient with portal hypertension and found a significant decrease in the wedge hepatic venous pressure (WHVP) However they found that after 30 hours the portal

From the Department of Diagnostic Radiology (Director G Westberg) Serafimerlasarettet S-11283 Stockholm Sweden
Submitted for publication 18 December 1979

pressure rose to the value before the occlusion They supposed that the cause was an arteriovenous shunting which may occur at the interruption of the arterial splenic blood flow

In cases with ulcerative colitis the incidence of liver cirrhosis is in most series about 2 per cent (MISTILIS 1975) The cause of this cirrhosis is not quite clear and could be classified as cryptogenic These patients may develop gastric and oesophageal varices but also varices at an ileostomy stoma (MISTILIS)

The vascularity and the blood flow of the liver and spleen were preoperatively evaluated in patients with extremely large spleens hypersplenism and haemorrhage during 1975 to 1978 and the results are now reported

Material

The material consisted of 4 men aged between 32 and 47 years (mean 41) all with extraordinary splenomegaly Three patients (47 44 and 42 years of age) had a long history (19–30 years) of ulcerative colitis a colectomy had been performed 9 to 14 years before the angiography

The fourth patient 32 years of age had symptoms suggesting colitis between 6 and 16 years of age He was also treated for colitis during this period Since the age of 17 he had no symptoms indicating colitis

All patients had hypersplenism with thrombocytopenia They had all great varicosity at various locations mainly oesophageal but also umbilical haemorrhoidal and splenorenal Two patients had episodes of bleeding from the varices

Splenectomy was performed in all the cases and the syndrome of hypersplenism disappeared as well as the bleedings The splenic weights varied between 740 and 1 130 g (mean 933) and microscopy of the spleens showed mainly congestion and hyperplasia of the pulp and reticulum

The 32 year old man was first operated upon with ligation of the splenic artery and the left gastric vein The bleedings ceased for more than one year However new bleedings appeared due to varicose collaterals and splenectomy was performed

None of the patients were alcoholics Liver function tests were normal but sometimes ASAT and ALAT were slightly elevated Liver biopsies were performed in 3 cases and at microscopy unspecific inflammation and early or slight cirrhosis were revealed

Methods

The recordings were performed before sple[illegible]tomy

Portal vein pressure was measured at umb[illegible] portography in 2 cases In one case the 3? yea[illegible] man the pressure was measured at operation at the ligation of the splenic artery and later a[illegible] splenectomy

The wedge hepatic venous pressure (WHV[illegible] measured in 2 cases according to KROOK (19[illegible]

Celiac angiography was performed with Isopaque Coronar which was injected at a [illegible] of 9 9 ml/s (8 3–11 4) Superior mesenteric [illegible]graphy was performed with 60 ml at a me[illegible] 10 4 ml/s (9 4–11 1)

The film series were programmed as fol[illegible] celiac angiography 2 films/s for 4 s 1 film/s f[illegible] and 1 film every third s for 15 s superior mese[illegible] angiography 1 film/s for 8 and 1 film every thir[illegible] 24 s The injections and exposures were regi[illegible] with a Mingograf

After the angiography with contrast medi[illegible] isotope angiography was performed Throu[illegible] catheters either in the celiac or superior mese[illegible] artery or in both separately 110 to 125 MBq [illegible] sulphur colloid was injected The activity [illegible]istered with a gamma camera and images [illegible] taken with a formatter The registrations [illegible] formed during 20 to 40 s and one or two [illegible] second were taken Finally an ordinary liver scan was obtained

Dimensions of vessels were estimated by [illegible]ing the diameters The proper hepatic the righ[illegible] left hepatic the splenic and the superior me[illegible] arteries were measured one cm from the [illegible] The splenic the superior mesenteric and portal veins were measured one cm from the co[illegible]ence

Arterial flow As a parameter for the arterial [illegible] velocity in the liver spleen and intestine the e[illegible]tying time of the arteries was determined The [illegible]terial emptying time for a region was defined as time elapsing from the end of the injection t[illegible] arteries had emptied

Venous flow As a parameter for the venous f[illegible] velocity the time from the start of the injection [illegible] maximum filling (maximum contrasting effect of [illegible] splenic superior mesenteric and portal veins [illegible] recorded

Splenic size was calculated according to BEV[illegible]



a



b



c



d

ig 1 47 year old man Extreme splenomegaly hyperkinetic splenic flow and portal hypertension Ulcerative colitis since 1949 colectomy 1963 Celiac angiography a) arterial phase 4 0 s and c) late venous phase 20 1 s after start of injection of contrast medium Superior mesenteric angiography b) arterial phase 4 ? s and d) venous phase 15 4 s after start of injection A wide splenic artery early filling phase (a b) and steal from the superior mesenteric circulation indicate hyperkinetic flow in the large spleen At celiac injection the venous return was diverted from the liver and directed to large collaterals as marginal veins of the remaining left mesocolon (→) At superior mesenteric injection venous return mainly through the portal vein to the liver (→) Hepatic arteries are not widened (a b)

t coll (1969) as the radiographic area of the spleen measured as the product of the length and width *Liver size* was estimated and classified as normal or enlarged

Results

All recordings were performed before the splenectomy or the ligation of the splenic artery In the 32 year old man first operated upon with a ligation

b



c

Fig 2 Same patient as in Fig 1 Isotope angiography followed for 21 s a) celiac b) superior mesenteric injection c) Liver spleen scintigraphy 15 min after isotope angiography anterior registration After the celiac injection very little activity in portal vein and liver After superior mesenteric injection activity in portal vein (→) and liver Homogeneous isotope uptake in both the normal sized liver and the enlarged spleen No recorded activity in the skeleton (c)

the splenic artery and later with splenectomy the bservations after the ligation are reported sepa ately

Portal pressure

The portal pressure was in 2 cases measured at cal portography and the values were 2 9 and 7 kPa respectively

In the 32 year old man the portal pressure was rst measured (1976) at the ligation of the splenic rtery The pressure was 4 1 kPa and at the moment f ligation of the splenic artery an instant decrease to 7 kPa occurred Two years later the splenectomy as performed At this operation the pressure was bout the same as immediately after the ligation (2 6 Pa) When the splenectomy was completed it de reased to 1 9 kPa In the remaining case the portal ressure was not measured

The wedge hepatic venous pressure measured in patients was 0 8 and 1 8 kPa respectively and the ortal pressure recorded at umbilical portography nd at operation was 3 7 and 4 1 kPa

Splenic size

All spleens were extraordinary large (Figs 1 a 2 c c) the splenic area being 298 to 448 cm (mean 387) nd the splenic weight 740 to 1 130 g (mean 933) he splenic area and weight was highly corre ated (r = 0 95) in 3 cases However if the 32 year ld man was included the correlation was weaker =0 67) He had after the ligation of the splenic rtery many arterial collaterals which were ligated irst and thus the spleen was relatively empty of blood when it was extirpated In the other cases the plenic artery and vein were ligated at about the ame time

Splenic circulation

Mean circulation time The arterial emptying time f the spleen varied between 1 8 and 2 2 s (mean 2 1) The maximum filling of the portal vein oc ed between 12 4 and 18 4 s (mean 15 0)

In all cases except one an ordinary contrasting t of the portal vein occurred at celiac angio y In that case a 47 year old man (Fig 1) very large shunts existed in the hilum of the spleen to eins in the left side of the abdomen These veins were probably marginal veins of the colon left at colectomy (Fig 1 c) Most probably there were also shunts to the left renal vein In this case the portal vein was only faintly filled at celiac angiography

In this patient isotope angiography of the celiac and superior mesenteric arteries obviously showed the difference between the 2 circulation systems At the celiac isotope angiography a great loss of flow was recorded from the splenic vein and no flow appeared in the portal vein (Fig 2 a)

At superior mesenteric injection on the other hand no visible diversion of flow from the liver was recorded but a markedly increased flow in the portal vein (Fig 2 b) These isotope angiographic findings are completely in accordance with the flow direc tions found at the angiography performed with con trast medium (Fig 1)

The 32 year old man was re examined 2 years after ligation of the splenic artery Very large arterial collaterals from gastric pancreatic and duodenal ar teries had developed to the spleen (Fig 3 a c) The emptying time of the splenic arteries was before ligation 1 8 s and after 7 1 s The maximum filling of the portal vein occurred at 12 4 s before and 16 9 s after the ligation (Fig 3 b d) and the contrasting effect was also decreased

Dimensions of vessels The diameter of the splenic artery varied between 11 and 16 mm (mean 13 3) and the diameter of the splenic vein between 14 and 25 mm (mean 19 8) In all cases except one the 47 year old man with large shunts in the hilum of the spleen the vein was wider than the artery In this case the vein and the artery had the same diameter (14 mm) indicating early loss of flow from the splenic vein (FRIMAN)

Superior mesenteric circulation

Mean circulation time The emptying time of the mesenteric arteries varied between 6 0 and 9 8 s

In all cases a high contrasting effect of the portal vein occurred at superior mesenteric angiography The maximum filling of the portal vein occurred at 15 4 to 25 4 s (mean 19 8)


Dimensions of vessels The diameter of the superior mesenteric artery varied between 10 and 13 mm (mean 10 8) and superior mesenteric vein be tween 14 and 19 mm (mean 16 3)

Liver size

The liver size was estimated as normal in all cases However in one case the 44-year old man computed tomography performed one hour after the angiography demonstrated a rather small liver and revealed large areas consisting of venous structures




a



b



c



d

Fig 3 32 year-old man Extreme splenomegaly hyperkinetic splenic flow and portal hypertension Splenic artery ligation 1976 Treated for colitis between 6 and 16 years of age Celiac angiography a) before ligation of the splenic artery arterial filling phase 1 ? s after start of injection b) venous phase after 12 4 s c) after ligation arterial filling phase after 3 5 s d) venous phase after 16 9 s The splenic artery widened early filling phase (a) and almost all contrast medium passes to spleen hyperki[...] flow After double ligation (→) of the splenic artery still a [...] kinetic flow through dilated arterial collaterals over [...] duodenum and pancreas to the spleen (c) Arterial filling [...] obtained 2 3 s later The portal vein (→) is narrower and contrasting effect is less after ligation (d) than before (b)

(Fig 4) These findings explained the incorrect estimation of the liver size with other methods

Hepatic circulation

Mean circulation time The emptying time of the hepatic arteries was 3 2 to 6 6 s (mean 5 1)

In the 32 year-old man the emptying time of the hepatic arteries changed from 5 8 s before to 4 [...] after the ligation of the splenic artery

Dimensions of vessels The diameter of the r[...] hepatic arteries varied from 5 mm to 7 mm (m[...] 5 8) and the left hepatic arteries varied from 3 m[...] 5 mm (mean 4 0)

The transverse area of the right and left hep[...]



a



b



c



d

Fig 4 44-year-old man Extreme splenomegaly hyperkinetic splenic flow and portal hypertension Ulcerative colitis since 1950 colectomy 1967 Superior mesenteric angiography a) arterial phase 4 3 s after start of injection b) venous phase after 22 ? s Steal to a widened splenic artery (→) from the superior mesenteric circulation (a) indicating hyperkinetic splenic flow Hepatic arteries are not widened In (b) a portal vein aneurysm (→) and a dilated portal vein (→) c d) Computed tomography The portal vein aneurysm (→) The left kidney is compressed by the enlarged spleen


arteries varied between 26 7 mm and 47 4 mm (mean 34 6)

The diameter of the portal vein varied between 24 and 28 mm (mean 25 5) and the transverse area between 452 mm and 615 mm (mean 512)


In the 32 year old man the transverse area of the hepatic arteries was 26 7 mm before and 44 7 mm after the ligation of the splenic artery corresponding values of the portal vein area were 615 mm and 380 mm² (Fig 3b d)

Liver spleen scintigraphy

A high splenic uptake corresponding to the splenomegaly was encountered in all cases (Fig 2c) The isotope accumulation in the liver was homogeneous in 3 cases In the 43 year-old man a defect was observed caused by a wide umbilical vein This vein was seen in the venous phase of the angiography both with contrast medium and with isotope (Fig 5)



a



b

Fig 5 4? year-old man Extreme splenomegaly hyperkinetic splenic flow and portal hypertension Ulcerative colitis since 1962 colectomy 1968 a) Liver spleen scintigraphy Defect in the liver uptake The defect was caused by a wide and tortuous umbilical vein (→) demonstrated at celiac angiography with contrast medium (b) and with isotope angiography (Fig 6)

No increased skeleton uptake occurred in any of the patients (Figs 2c 5a)

Discussion

Spleen An interesting observation was made by ITZCHAK & GLICKMAN (1977) who found several cases with splenic vein thrombosis without enlargement of the spleen This means that obstruction of the splenic venous blood flow does not necessarily lead to spenomegaly This is in accordance with the everyday radiologic observation that splenic venous constriction or obstruction caused by pancreatitis or carcinoma seldom is associated with an enlarged spleen Splenomegaly in Laennec cirrhosis probably depends on other factors than venous stasis exclusively As reticuloendothelial (RE) cells are destroyed in Laennec cirrhosis RE cells will appear in other organs e g the spleen and the skeleton Thus the splenomegaly can be explained by a compensation of the RE cells destroyed in the cirrhotic liver An increased accumulation of isotope is normally recorded in the spleen and the skeleton in Laennec cirrhosis if the scan is performed with $^{99}Tc^{m}$ sculphur colloid which is handled by the RE cells

The recorded activity of the skeleton was not increased in these 4 cases However the isotope uptake in the large spleens was markedly increased

The scintigraphic findings thus differ from the [findi]ngs in ordinary Laennec cirrhosis The splenom[ega]ly in these cases could be caused by the long [dura]tion of the inflammatory process of the colon

The spleens were very large in mean 9[…] (740–1 130) the area of the spleen was in mea[n …] cm² (298–467) In portal hypertension depe[nding] mainly on Laennec cirrhosis the area was in [mean] 210 cm² and in 7 cases with normal portal pres[sure] the area was in mean 101 cm² (FRIMAN)

The volumetric splenic flow was increased in [the] present 4 patients compared with patients [with] Laennec cirrhosis and normal cases The param[eter] for splenic flow velocity the emptying time of [the] splenic arteries was in mean 2 1 s which is sho[rter] than previously reported (in mean 2 6 s BOIJSE[N &] REDMAN 1966 FRIMAN) The splenic artery dia[me]ter was in the present investigation in mean 1[…] mm In Laennec cirrhosis it was in mean 9 ? […] and as the parameter for flow velocity was shor[ter] the volumetric splenic flow in these extremely b[ig] spleens has to be more than twice that in ordin[ary] Laennec cirrhosis

The transverse area of the portal vein in this gr[oup] (in mean 512 mm²) was more than twice the tra[ns]verse area of the patients with Laennec cirrhosis [(in] mean 220 mm²)

The maximum filling of the portal vein at cel[iac] angiography in these 4 cases occurred at in me[an]




Fig 6 Same case as in Fig 5 The isotope angiography was followed for 47 s *In the first frames isotope in the catheter* (→) which is washed out and later the umbilical vein (→) is filled with isotope and clearly distinguishable due to its superficial location

is 5 0 s and in cases with Laennec cirrhosis (FRIMAN) it was in mean 14 7 s Corresponding values for maximum filling of the portal vein at superior mesenteric angiography were 19 1 s and 17 5 s Consequently the portal flow in this group with extraordinary splenomegaly is more than twice the flow in the group with portal hypertension due to Laennec cirrhosis SHIMPEI et coll and PITLIK et coll have described *portal hypertension due to increased* splenic flow in patients with splenic hemangiomatosis These patients with extraordinary splenomegaly and hyperkinetic splenic flow also have increased portal flow which seems to be at least partly responsible for the portal hypertension In what respect the increased portal flow per se can cause obstructive changes as portal fibrosis in the liver or in what respect the colitis itself is responsible for the abnormalities in the liver seems difficult to decide

Liver The observations of the liver regarding the correlation between (1) portal pressure and wedge hepatic venous pressure (WHVP) (2) arterial and portal venous flow and (3) scintigraphic findings differed from ordinary Laennec cirrhosis

Ad 1 In 2 cases both the WHVP and the portal pressure were determined WHVP was normal (0 8 and 1 8 kPa) and the portal pressure was markedly increased (3 7 and 4 1 kPa) In normal livers and in Laennec cirrhosis the portal pressure and WHVP usually are of the same value These findings are in accordance with MISTILIS who claims that in most cases of colitis with cirrhosis there are obstructions at a presinusoidal level leading to high portal pressure and normal WHVP

Ad 2 In Laennec liver cirrhosis usually the portal venous flow is decreased and the arterial hepatic flow increased which is explained by the capacity of the liver for arterial autoregulation In the present cases the portal flow was not decreased nor the arterial flow increased

The arterial emptying time of the hepatic arteries was in mean 5 1 s and in cases with portal hypertension due to Laennec cirrhosis it was in mean 3 2 s (FRIMAN) The transverse area of the hepatic arteries (mean 35 mm²) was about the same as in cases with normal portal pressure (mean 37 mm²) and these values should be compared with the cases with portal hypertension due to Laennec cirrhosis (mean 82 mm² FRIMAN) Consequently the arterial hepatic flow was not increased due to the fact that the portal flow was not decreased

The autoregulation of hepatic arterial blood flow can be illustrated by one of the cases the 32 year old man He was first operated upon with ligation of the splenic artery resulting in instant decrease in portal pressure (from 4 1 to 2 7 kPa) At the same operation the left gastric vein was ligated The bleedings ceased for more than one year Two years later a repeat angiography was performed The transverse area of the portal vein had changed from 650 to 380 mm² and the maximum filling of the portal *vein from 12 4 to 16 9 s* both findings indicating a decreased portal flow This decrease was compensated by *an increase of the hepatic arterial blood* flow The transverse area of the hepatic arteries changed from 27 to 45 mm² and the *emptying time* from 5 8 to 4 2 s indicating increased arterial hepatic flow (Fig 3)

Ad 3 The isotope uptake in the liver *was normal* without defects except in one case (Fig 6) In this case a defect was caused by an angiographically demonstrated wide and tortuous umbilical vein

The present results as well as those previously reported (NEBESAR & POLLARD 1966 FRIMAN) demonstrate that superior mesenteric angiography gives the highest contrasting effect of the portal vein particularly in portal hypertension The celiac system sometimes has such a great loss of flow through shunts that the portal vein does not fill at all or is only faintly filled at celiac angiography

Conclusions

Patients with a long history of colitis may develop extreme splenomegaly with hypersplenism and portal hypertension (1) At angiography hyperkinetic splenic blood flow was demonstrated (2) The hyperkinetic splenic blood flow increases the portal blood flow (3) The portal pressure is increased and portocaval shunting develops probably primarily depending on increased splenic blood flow and secondarily depending on increased hepatic resistance (4) The increase in hepatic resistance is caused by abnormalities considered as slight cirrhosis probably due to the long duration of the increase in portal flow (5) The scintigraphic findings differ from those in Laennec cirrhosis the uptake in the liver is homogeneous and no uptake in the skeleton is recorded (6) Splenectomy cures both the hypersplenism and the portal hypertension

SUMMARY

Four patients with a long history of colitis splenomegaly hypersplenism and portal hypertension were examined with angiography both with contrast medium and isotopes liver spleen scintigraphy and recording of portal pressure At angiography hyperkinetic splenic and portal blood flow was demonstrated The increased flow causes increased portal pressure which probably gives rise to changes in the liver often considered as slight cirrhosis at microscopy The scintigraphic findings differed from Laennec cirrhosis The liver uptake was homogeneous and no activity in the skeleton was recorded Splenectomy cures both the hypersplenism and portal hypertension

Request for reprints Dr Leif Friman Department of Radiology St Gorans Sjukhus Box 12500 S-11281 Stockholm Sweden

REFERENCES

BLENDIS L M WILLIAMS R and KREEL L Radio[illegible] determination of spleen Gut 10 (1969) 433

BOIJSEN E and REDMAN H C Effect of bradyki[illegible] celiac and superior mesenteric angiography [illegible] Radiol 1 (1966) 422

FRIMAN L Portal pressure correlated to visceral cir[illegible] tion times Acta radiol Diagnosis 20 (1979) [illegible]

GARNETT E S MARKBY D GODDARD B A and WE[illegible] C E The spleen as an arteriovenous shunt Lancet [illegible] (1969) 386

HANSON K M and JOHNSON P C Local control of he[illegible] patic arterial portal venous flow in the dog Amer J Physiol 211 (1966) 712

ITZCHAK Y and GLICKMAN M Splenic vein throm[illegible] in patients with a normal size spleen Invest Rad[illegible] (1977) 158

KOCK N G HAHNLOSER P RODING B and SCHENK W G Interaction between portal venous and he[illegible] arterial blood flow An experimental study in the d[illegible] Surgery 72 (1972) 414

KROOK H Circulatory studies in liver cirrhosis [illegible] med scand (1956) Suppl No 318

MISTILIS S P Liver disease in bowel disorders In D[illegible] eases of the liver Fourth edition p 1379 Ed [illegible] Leon Schiff J B Lippincott Company Philad[illegible] Toronto 1975

NEBESAR R A and POLLARD J J Portal venogra[illegible] selective arterial catheterization Amer J Roen[illegible] 97 (1966) 477

PITLIK S COHEN L HADAR H SRULIJES C and R[illegible] FELD J B Portal hypertension and esophageal [illegible] in hemangiomatosis of the spleen Gastroenterol[illegible] (1977) 937

REUTER S R BERK R N and ORLOFF M J An[illegible] giographic study of the pre and postoper[illegible] hemodynamics in patients with side to side portoca[illegible] shunts Radiology 116 (1975) 33

SHIMPEI T MASAHIRO S TSUTOMU T MASAKI[illegible] ISAO N ATSUKO M and FUJITSUGU M Diffuse c[illegible] lary hemangiomatosis of the spleen as a cause of p[illegible] hypertension Radiology 104 (1972) [illegible]3

VIAMONTE M DANNER P WARREN W D and FOM[illegible] A new technique for the assessment of hyper[illegible] portal hypertension Radiology 96 (1970) 539

WILLIAMS R CONDON R E WILLIAMS H S BLE[illegible] L M and KREEL L Splenic blood flow in cir[illegible] and portal hypertension Clin Sci 34 (1968) [illegible]1

ROM THE DEPARTMENTS OF DIAGNOSTIC RADIOLOGY (DIRECTOR PROF T OLIN) AND OBSTETRICS AND GYNECOLOGY (DIRECTOR PROF S KULLANDER) MALMÖ ALLMANNA SJUKHUS S-21401 MALMO AND THE DEPARTMENT OF CLINICAL PHARMACOLOGY (DIRECTOR K E ANDERSSON) UNIVERSITY HOSPITAL S-22185 LUND SWEDEN

PHARMACOANGIOGRAPHY OF GYNECOLOGIC TUMORS

S KARLSSON P H PERSSON and K E ANDERSSON

In order to improve the angiographic diagnosis of benign and malignant lesions both vasoconstrictors ABRAMS 1964 BOIJSEN & REDMAN 1967 KAHN et coll 1967 KAPLAN & BOOKSTEIN 1972 EKELUND & LUNDERQUIST 1974) and vasodilators KHAN & CALLOW 1965 BOIJSEN & REDMAN 1966 FREED et coll 1968 REDMAN et coll 1969 DANFORD 1970 UDÉN 1972) have been used successfully in various vascular regions

Selective angiography of the internal iliac arteries is a well established method for diagnosing gynecologic tumours (ALTEMUS 1968 1969) Whether the use of vasoactive drugs can increase the information obtained by angiography of such tumors has not been established EKELUND & LUNDERQUIST used angiotensin for vasoconstriction during angiography of the internal iliac artery in 6 patients In 3 of these the drug was found to have significant vascular effects but increased diagnostic information was questionable

Some vasoconstrictor drugs probably with different modes of activating the vascular smooth muscle cells and the vasodilator bradykinin were given during selective angiography of the internal iliac arteries in a series of women with various kinds of pelvic tumor and the results are now reported

Material and Methods

The series consisted of 62 women without previous history of gynecologic tumor or with a non symptomatic but palpable pelvic tumor Preoperatively they were examined by ultrasound and by selective angiography of the internal iliac arteries The angiographic method and the results of these examinations have been presented previously (KARLSSON & PERSSON 1979)

The systemic blood pressure and pulse rate were continuously recorded during the angiography using a polythene catheter OD/ID 1 57/1 14 mm inserted into the left femoral artery with the tip placed at the aortic bifurcation The catheter was connected to an Elema Schonander FMI 34 pressure recorder and a Mingograf 800 Blood pressure injection time and exposures were recorded In all cases the exposure rate was 2 films per second for 2 s one film per s for 4 s and one film every other second for 8 s The amount of injected contrast medium and the injection time were also the same

Approximately 10 min after the first injection of contrast medium into both the internal iliac arteries the drug to be tested was injected into the right one After 30 to 40 seconds another bilateral internal iliac angiography was performed The branches of the left iliac artery served as a control to those of the right artery in which the drug had been injected

The transit time was measured as the time interval between the end of the injection of the contrast medium and the last film on which the medium was observable in the most peripheral branches of the internal iliac arteries

The diameter of the pelvic arteries was measured on the films using a scale lupe with 10 times magnification

The drugs tested doses and number of patients are given in Table 1

Statistical significance was calculated by means of

Submitted for publication 20 July 1979

Student s t test Values of $p<0\ 01$ were considered significant

The effect of the repeat angiography on the transit time without vasoactive drugs was tested in 10 patients (Table 2) No significant changes were found

Results

Prostaglandin $F_{2\alpha}$ Sixteen patients received 250 or 500 μg of prostaglandin $F_{2\alpha}$ ($PGF_{2\alpha}$) None of the patients was premenopausal Four had myomas 5 had benign cysts and 5 malignant ovarian tumors Two patients had leiomyosarcomas of the small intestine

After the administration of $PGF_{2\alpha}$ a decrease in the diameter of the uterine artery on the side of injection was found in 2 patients one with struma ovarii and one with myoma The reduction of the diameter was 0 5 mm and this reduction was bilateral in the patient with myoma

An increase in the diameter of the uterine artery *of less than 0 5 mm at the side of injection occurred* in 2 patients one with a myoma and one with a simple cyst In these cases the transit time was increased to the same extent as in other cases which received $PGF_{2\alpha}$

$PGF_{2\alpha}$ caused a significant increase in transit time on the side of injection (Table 3) On the contra*lateral side a significant increase in the transit time* was found in the uterine and vesical haemorrhoidal arteries ($p<0\ 01$) The mean increase of the transit time on the side of injection was 144 per cent and on the control side 67 per cent

The increase in transit time was the same in the various vessels of patients with myomas ovarian carcinomas or benign ovarian lesions nor was any difference observed between large and small tumors

Both systolic and diastolic pressures increased after the administration of $PGF_{2\alpha}$ the mean increase for both being 11 mmHg with a maximum after a mean of 21 seconds The maximum increase was *observed in a hypertonic patient the systolic and* diastolic pressures increased by 55 and 45 mmHg respectively

One of the patients who received 500 μg of $PGF_{2\alpha}$ complained of mid abdominal pain immediately after injection The pain ceased completely after about 30 to 40 seconds No other symptoms were *reported*

8 lysine vasopressin Thirteen patients 2 of whom

Table 1

Drugs tested doses and number of patients

Drug	Dose	No of patients
Prostaglandin $F_{2\alpha}$	250 μg	5
	500 μg	11
Vasopressin	0 25 IU	7
	0 5 IU	6
Noradrenalin	2 5 μg	3
	5 0 μg	4
Oxytocin	5 IU	14
Methylergometrine	250 μg	6
Bradykinin	5 μg	2
	10 μg	4

were premenopausal received 0 25 or 0 5 IU vasopressin Four patients had myomas 6 ovarian carcinomas and one a benign cyst 1 *patients had small encapsulated hematomas*

After the injection of vasopressin a decrease the diameter of the uterine artery on the side of jection was observed in 3 patients In 2 of th the decrease was less than 0 5 mm In one p menopausal woman with myoma the decrease 1 5 mm (Figure)

After injection of vasopressin the increa transit time was highly significant or significan all arteries on the side of injection wherea was significant ($p<0\ 01$) only in the inferior glu and internal pudendal arteries on the con side (Table 4) The mean increase in transit tim the arterial branches on the side of injection was *per cent and on the control side 80 per cent*

The increase in transit time was not dependent malignancy or on tumor mass However a dif ence was observed concerning the increase transit time of the uterine artery In patients w myoma the mean increase in the uterine artery 372±197 per cent whereas it was 128±151 per c *in the other patients However this difference* not statistically significant

The systemic pressures increased after the adm istration of vasopressin The mean systolic press increased by 9 mmHg and the diastolic by 5 mmH a maximum being obtained after a mean of seconds

The patients did not report any subjective re tions after the injection of vasopressin

Table 2

Change in transit time (in per cent) durin~ 2 selective an~io~ra~hies of the internal iliac arteries perf med with an interval of 10 min (10 patients) No statist cally si~nificant chan~es

Artery	Right		Left	
	Mean ± SEM	Range	Mean ± SEM	Range
1 Superior gluteal	8±8	−50–100	13±5	0–40
2 Inferior gluteal	7±12	−50–100	5±4	0–33
3 Internal pudendal	7±5	−.0–33	13±6	−33–33
4 Obturator	6±8	−43–50	17±6	0–50
5 Uterine	7±6	−27–40	3±~	−3.–40
6 Vesical + medial haemorrhoidal	7±3	0–20	1.±13	−20–100

Table 3

Chan~e in transit time (in per cent) after injection of prostaglandin $F_{2\alpha}$ 250 or 500 µg in the ri~ht internal iliac artery of 16 patients The increase in transit time was significant (p<0.01) or highly si ni~cant (p<0 001) on the side of injection On the control s de it was significant in arteries 5 and 6

Artery	Right		Left	
	Mean ± SEM	Range	Mean ± SEM	Range
1 Superior gluteal	151±38	−37–568	54±.1	−29–.0
2 Inferior gluteal	.07±46	−50–600	59±.6	−36–333
3 Internal pudendal	147±33	−14–467	83±35	−8–467
4 Obturator	159±50	−70–467	91±.9	−70–333
5 Uterine	116±30	−33–300	89±77	−12–.0
6 Vesical + medial haemorrhoidal	86±.1	79–250	.8±9	−.–167

Table 4

Change in transit time (in per cent) after in ection f 8-lysine vasop essin 0.5 or 0.5 IU in the right internal iliac artery of 13 patients The increase in transit time was significant or hi~hly si~nificant on the side of injection On the control side it was significant in arteries 2 and 3

Artery	Right		Left	
	Mean ± SEM	Range	Mean ± SEM	Range
1 Superior gluteal	.03±43	−17–500	62±34	−71–460
2 Inferior gluteal	134±37	.0–467	73±.3	−43–.0
3 Internal pudendal	222±43	14–600	66±.1	−14–233
4 Obturator	224±65	0–600	109±42	−18–370
5 Uterine	218±55	0–1 100	108±45	−50–500
6 Vesi al + medial haemorrhoidal	177±.8	0–320	64±26	−29–200

Noradrenalin Seven patients received 2 5 or 5 0 g of noradrenalin Two had myomas one had a and 4 had benign cysts All pa ents but one were premenopausal

In 4 patients (2 with myomas one with cystadenofibroma and one with a simple cyst) a decrease of less than 0.5 mm of the diameter of uterine artery was noted on the side of injection In one woman



a



b

The large myomatous uterus is rotated and the right uterine artery is stretched over to the left (→) a) Before and b) after administration of 0 5 IU vasopressin

with myoma a corresponding decrease of the diameter of the uterine artery was also observed on the control side

Noradrenalin consistently increased the transit time on the side of injection (Table 5) However this increase was statistically significant only in the obturator artery The transit time was not changed on the control side On the side of injection the mean increase in transit time in all branches was 78 per cent A slight and not consistent increase in blood pressure occurred both systolic and diastolic pressures increased by 5 mmHg or less

No subjective reactions were reported after the administration of noradrenalin

Oxytocin Fourteen patients 4 premenopausal were given 5 IU of oxytocin At operation one woman was found to have a normal gynecologic status Seven patients had myomas and 5 had benign cysts One woman had bilateral and inoperable carcinoma of the ovaries

After the administration of oxytocin the diameter of the uterine artery increased on the side of injection in 2 patients and decreased in one This change was less than 0 5 mm and not correlated to age or type of tumor

After injection of oxytocin a significant decrease in transit time was found in the internal pudendal artery on the side of injection and in the gl[illegible] superior and vesical haemorrhoidal arteries on the control side The mean decrease on the side of injection was 7 per cent and on the control side 6 per cent (Table 6)

The blood pressure consistently decreased the systolic pressure by a mean of 30 mmHg and the diastolic by a mean of 20 mmHg

The maximum change was observed after a per[illegible] of 30 seconds The maximum decrease in sys[illegible] pressure was 70 mmHg and in diastolic pressure [illegible] mmHg

No subjective reactions were noted after the administration of oxytocin

Methylergometrine Six patients 3 premenopausal received 200 μg of methylergometrine Three of these had myomas 2 had benign cysts and one a large ovarian carcinoma After the injection of methylergometrine no changes in the diameter of the uterine or other arteries were observed

Methylergometrine caused no significant cha[illegible] in transit time neither on the side of injection nor on the control side (Table 7) The mean cha[illegible]

Table 5

Change in transit time (in per cent) after injection of noradrenalin 2 5 or 5 0 µg in the right internal iliac artery of 7 patients The increase in transit time was highly significant in artery 4 on the side of injection No significant changes on the control side

Artery	Right		Left	
	Mean ± SEM	Range	Mean ± SEM	Range
1 Superior gluteal	48±16	−27–100	−5±7	−25–29
2 Inferior gluteal	70±26	−29–150	2±8	−33–29
3 Internal pudendal	111±35	−12–250	−9±8	−33–25
4 Obturator	127±12	100–150	8±13	−29–50
5 Uterine	65±23	−9–150	−5±7	−33–21
6 Vesical + medial haemorrhoidal				

Table 6

Change in transit time (in per cent) after injection of oxytocin 5 IU in the right internal iliac artery of 14 patients A significant decrease in transit time was found in artery 3 on the side of injection and in arteries 2 and 6 on the control side

Artery	Right		Left	
	Mean ± SEM	Range	Mean ± SEM	Range
1 Superior gluteal	18±24	−66–150	−23±7	−67–0
2 Inferior gluteal	−14±9	−60–40	14±19	−60–150
3 Internal pudendal	−22±7	−60–0	8±13	−60–100
4 Obturator	−23±11	−60–33	6±30	−40–150
5 Uterine	3±21	−67–100	29±23	−57–185
6 Vesical + medial haemorrhoidal	−7±8	−45–87	19±6	−50–25

ll vessels on the side of injection was −4 per cent nd on the control side −6 per cent

The effect on systemic blood pressure was negli ible a slight increase of 2 to 4 mmHg of both the ystolic and diastolic pressures being recorded

None of the patients reported any subjective reac ions after the administration of methylergometrine

Bradykinin Six patients one premenopausal received 5 or 10 µg of bradykinin Two had myo mas 3 had benign cysts and one had bilateral in operable ovarian carcinoma

Bradykinin caused an increase in the diameter of the uterine arteries in 3 patients The increase was less than 0 5 mm and occurred on the side of injec tion One of these patients postmenopausal with myoma also had a measurable increase in the dia meters of the inferior gluteal and internal pudendal arteries on the side of injection the increase being 0 5 mm

After bradykinin administration a highly signifi cant decrease in transit time was recorded in all arteries but one on the side of injection while no significant changes were found on the control side (Table 8) The mean decrease in all vessels on the side of injection was 60 per cent and on the control side 25 per cent

After bradykinin the venous phase was en hanced but this did not increase the diagnostic in formation On the contrary in the arterial and capil lary phases information was lost to some extent

A small but consistent decrease in blood pressure was recorded In the mean the systolic pressure decreased by 8 mmHg and the diastolic by 6 mmHg The maximum decrease occurred after 25 seconds in the mean

No subjective reactions were reported after the administration of bradykinin

Table 7

Change in transit time (in per cent) after injection of methylergometrine 200 µg in the right internal iliac artery of 6 patients No significant changes neither on the side of injection nor on the control side

Artery	Right		Left	
	Mean ± SEM	*Range*	*Mean ± SEM*	*Range*
1 Superior gluteal	−6±6	−33–0	−7±5	−29–0
2 Inferior gluteal	−7±5	−33–0	3±4	−10–0
3 Internal pudendal	14±13	−20–75	8±15	−29–75
4 Obturator	19±9	0–50	−7±9	−33–20
5 Uterine	−15±9	−38–0	−18±3	−23–10
6 Vesical + medial haemorrhoidal	−1±9	−33–20	−10±10	−29–0

Table 8

Change in transit time (in per cent) after injection of bradykinin 5 or 10 µg in the right internal iliac artery of 6 patients The decrease in transit time was highly significant for all but artery 2 on the side of injection No significant changes on the control side

Artery	Right		Left	
	Mean ± SEM	Range	Mean ± SEM	Range
1 Superior gluteal	−62±9	−100–−40	−18±32	−100–−40
2 Inferior gluteal	−50±14	−100–0	−3±27	−100–100
3 Internal pudendal	−64±7	−84–−40	−32±17	−75–33
4 Obturator	−68±6	−84–−50	−32±17	−73–33
5 Uterine	−60±8	−84–20	−39±27	−84–33
6 Vesical + medial haemorrhoidal				

Discussion

In order to obtain maximum information from an angiography the series must be performed in at least 2 projections In the present series the tube was tilted 6 in the second angiography and a vasoactive drug was injected into the right internal iliac artery whereas all other parameters (amount of contrast medium injection time exposure rate) were unchanged It was hoped that the branches of the left internal iliac artery could serve as a control However several of the drugs caused a systemic effect as reflected in the blood pressure recordings and in the changes in transit time on the control side

The interval between the 2 pelvic angiographies was at least 10 min In a control group where no drug was injected at the second angiography little or no change in transit time was observed and no change in the diameter of uterine or other arteries (Table 2) Therefore any change in these para-meters after drug administration was regarded as a drug effect The present results revealed that the vascular reactions to the drugs used were the same in normal vessels as in vessels supplying the pelvic tumors It has been shown that in certain tumors newly formed vessels do not differentiate into arterioles and venules (BILLING & LINDGREN 1944) but *remain embryonic in type* and to a large extent lack smooth muscle cells in their walls As such vessels should not be able to react to vasoactive drugs like normal vessels a difference might be visible during pharmaco angiography (ABRAMS EKELUND et al 1972 EKELUND & LUNDERQUIST) In the present cases no such differences were found and none of the drugs used increased the diagnostic information

$PGF_{2\alpha}$ caused a marked contraction of the vessels and increased the transit time up to 600 per cent This was somewhat unexpected findings as $PGF_{2\alpha}$

doses of 10 to 80 μg has been found to be a potent ator when used for superior mesenteric and lenic angiography (DENCKER et coll 1972 LEGGE 77) However the circulatory effects of $PGF_{2\alpha}$ m to depend not only on the vascular region t also on the concentration of the agent used ALIK & MCGRIFF 1976) Thus $PGF_{2\alpha}$ infused into brachial artery caused constriction at low and atation at high doses (ROBINSON et coll 1973) fferences in reaction to prostaglandin between nous vascular regions or a biphasic action (vaso-atation at low doses vasoconstriction at high) ght explain the contractile effect of prostaglandin und in the present series in which the dose was proximately 10 times higher than that used pre ously in selective visceral angiographies (DENC R et coll LEGGE) Isolated human vessels from umbilical (PARK et coll 1972) cerebral (TODA 76) and peripheral (MIKKELSEN & ANDERSSON 78) circulations are contracted by $PGF_{2\alpha}$ It may argued that the increase in transit time in the rine circulation can be caused partly by a con actile effect on the myometrium Although such an fect cannot be excluded it seemed to be of minor portance as the constrictor effect was even more arked in e g the inferior gluteal artery on the side injection An effect on the systemic circulation as reflected by the consistent increase in both stolic and diastolic blood pressures

8 lysine vasopressin in the doses used was the ost potent of the vasoconstrictors but this effect as not particularly marked on the uterine vascula re A marked increase in this vascular region could ve been expected as it is well known that vaso-essin has not only a direct contractile effect on the erine vessels but also contracts the myometrium AKERLUND & ANDERSSON 1976) This is particu rly marked in the non pregnant uterus As the sig ficance of the increase in transit time was similar the uterine arteries and in the other branches of e internal iliac artery the vascular compression ust be of less importance than the direct effect n the vessels

Vasopressin caused an increase in systolic and iastolic blood pressures It also increased the ransit time of the arterial branches on the control ide This increase was significant in 2 of the 6 essels examined

Noradrenalin as could be expected caused a asoconstriction but only on the side of injection The increase in transit time was highly significant in only one of the 6 arteries This may be explained by the small doses used which had practically no effect on the blood pressure No difference in re sponse was found comparing tumor vessels and nor mal vessels

Oxytocin was found to have almost no effect on the various vessels Although it is well known that oxytocin has a contractile effect on the non pregnant myometrium (JOELSSON et coll 1966) the transit time in the uterine artery did not increase (Like vasopressin oxytocin had a tendency to increase the transit time in the uterine arteries in patients with myomas more than in those with other tumors but this difference was not obvious and not statisti cally significant)

The decrease in both systolic and diastolic pres sure after injection of oxytocin was consistent and significant This confirms the results of MAYES & SHEARMAN (1956) who reported a very rapid and significant fall in the blood pressure after intra venous administration of oxytocin in doses varying from 2 to 5 IU This decrease in blood pressure may explain the decrease in transit time which was observed in a few arteries on both the side of in jection and the control side

No effect of *methylergometrine* could be demon strated This is in line with the findings of GARRETT & MOIR (1958) and GARRETT (1959) who found that the non pregnant uterus has a low sensitivity to methylergometrine much less than the puerperal uterus The direct effect of methylergometrine on the blood vessels of the non pregnant uterus is small (KOFLER 1972) and its vascular effect is generally negligible (CLARK et coll 1978)

As in other vascular regions *bradykinin* caused a significant vasodilatation of most branches of the internal iliac artery but only on the side of injection It has been suggested (WEBER & NOVAK 1976) that bradykinin improves the demonstration of vessels affected by local inflammation and that the com bined use of bradykinin and a vasoconstrictor may be helpful in certain cases to differentiate between inflammatory and malignant lesions Only one pa tient in the present series who received bradykinin had a malignant tumor and pathologic vessels were not better demonstrated after the bradykinin injec tion

The present results thus suggest that the vaso-active drugs in the doses tested do not increase the diagnostic information obtained by selective angio-graphy of pelvic tumors in women

SUMMARY

Angiography was performed before and after intra-arterial administration of prostaglandin $F_{2\alpha}$, 8-lysine vasopressin, oxytocin, methylergometrine, noradrenalin and bradykinin in 62 women with various pelvic tumors. It is concluded that the use of the vasoactive drugs in the doses tested did not improve the angiographic diagnosis in unselected cases of female pelvic tumors.

REFERENCES

ABRAMS H. L.: The response of neoplastic renal vessels to epinephrine in man. Radiology 82 (1964), 217.

ÅKERLUND M. and ANDERSSON K.-E.: Vasopressin response and terbutaline inhibition of the uterus. Obstet. and Gynec. 48 (1976), 528.

ALTEMUS R.: Selective catheterization of the hypogastric arteries: advantages and discussion of technique. Radiology 91 (1968), 484.

— Differentiating uterine and extrauterine masses by bilateral selective hypogastric arteriography. Radiology 92 (1969), 1020.

BILLING L. und LINDGREN Å. G. H.: Die pathologisch-anatomische Unterlage der Geschwulstarteriographie. Eine Untersuchung der arteriellen Gefässe des Hypernephroms und des Magenkarzinoms. Acta radiol. 25 (1944), 625.

BOIJSEN E. and REDMAN H. C.: Effect of bradykinin on celiac and superior mesenteric angiography. Invest. Radiol. 1 (1966), 422.

— — Effect of epinephrine on celiac and superior mesenteric angiography. Invest. Radiol. 2 (1967), 184.

CLARK B. J., CHU D. and AELLIG W. H.: Actions on the heart and circulation. In: Ergot alkaloids and related compounds. Handbook of experimental pharmacology, Vol. 49, p. 322. Edited by B. Berde and H. O. Schild. Springer Verlag, Berlin, Heidelberg, New York 1978.

DANFORD R. O.: The effect of glucagon on renal hemodynamics and renal arteriography. Amer. J. Roentgenol. 108 (1970), 665.

DENCKER H., GÖTHLIN J., HEDNER P., LUNDERQUIST A., NORRYD C. and TYLÉN U.: Superior mesenteric angiography and blood flow following intra-arterial injection of prostaglandin $F_{2\alpha}$. Amer. J. Roentgenol. 125 (1975), 111.

EKELUND L. and LUNDERQUIST A.: Pharmacoangiography with angiotensin. Radiology 110 (1974), 533.

— GÖTHLIN J. and LUNDERQUIST A.: Diagnostic improvement with angiotensin in renal angiography. Radiology 105 (1972), 33.

FREED T. A., HAGER H. and VINIK M.: Effects of intraarterial acetylcholine on renal arteriography in normal humans. Amer. J. Roentgenol. 104 (1968), 312.

GARRETT W. J.: A theory of uterine action. J. Obstet. Gynaec. Brit. Emp. 66 (1959), 927.

— and MOIR J. C.: Ergot and the non-pregnant uterus. J. Obstet. Gynaec. Brit. Emp. 65 (1958), 583.

JOELSSON I., INGELMAN-SUNDBERG A. and SANDBERG F.: The in vivo effect of oxytocin and vasopressin on the nonpregnant human uterus. J. Obstet. Gynaec. Brit. Cwlth 73 (1966), 832.

KAHN P. C. and CALLOW A. D.: Selective vasodilatation as an aid to angiography. Amer. J. Roentgenol. [illegible] (1965), 213.

— FRATES W. J. and PAUL R. E. JR.: The epinephrine effect in angiography of gastrointestinal tract tumors. Radiology 88 (1967), 686.

KAPLAN J. H. and BOOKSTEIN J. J.: Abdominal visceral pharmacoangiography with angiotensin. Radiology 103 (1972), 79.

KARLSSON S. and PERSSON P. H.: Angiography, ultrasound and fine needle aspiration biopsy in the evaluation of gynecologic tumors. Acta radiol. Diagnosis 20 (1979), 779.

— — Angiography in uterine and adnexal tumors. Acta radiol. Diagnosis 21 (1980), 11.

KOLLER F.: Über die Mikrozirkulation an der Portio vaginalis uteri. Wien. klin. Wschr. 84 (1972) Suppl. [illegible]

LECCI D. A.: The use of prostaglandin $F_{2\alpha}$ in selective visceral angiography. Brit. J. Radiol. 50 (1977), [illegible]

MALIK K. U. and MCGIFF J. C.: Cardiovascular actions of prostaglandins. Prostaglandins: Physiological, pharmacological and pathological aspects. In: Advances in prostaglandin research, p. 103. Edited by S. M. M. Karim. MTP Press, Manchester 1976.

MAYES B. T. and SHEARMAN R. P.: Experience with synthetic oxytocin: the effects on the cardiovascular system and its use for the induction of labour and control of the third stage. J. Obstet. Gynaec. Brit. Emp. 63 (1956), 812.

MIKKELSEN E. and ANDERSSON K.-E.: Contractile effects of prostaglandin $F_{2\alpha}$ on isolated human peripheral arteries and veins. Acta pharmacol. (Kbh.) 43 (197[illegible]), 398.

PARK M. K., RISKOV C. and DYER D. C.: Vasoactive actions of prostaglandins and serotonin on isolated human umbilical arteries and veins. Canad. J. Physiol. Pharmacol. 50 (1972), 393.

REDMAN H. C., REUTER S. R. and MILLER W. J.: Improvement of superior mesenteric and portal vein visualization with tolazoline. Invest. Radiol. 4 (1969), [illegible]

ROBINSON B. F., COLLIER J. G., KARIM S. M. M. and SOMERS K.: Effect of prostaglandins A_1, A_2, B_1, E_2 and $F_{2\alpha}$ on forearm arterial bed and superficial hand veins in man. Clin. Sci. 44 (1973), 367.

TODA N.: Potassium-induced relaxation in isolated cerebral arteries contracted with prostaglandin $F_{2\alpha}$. Pflügers Arch. 364 (1976), 235.

UDÉN R.: Cholecystokinin-pancreozymin in celiac and superior mesenteric angiography. Acta radiol. Diagnosis 12 (1972), 363.

WEBER J. und NOVAK D.: Abdominale und periphere Pharmakoangiographie mit Angiotensin und Bradykinin. Radiologe 16 (1976), 524.

OM THE DEPARTMENTS OF DIAGNOSTIC RADIOLOGY (DIRECTOR PROF E BOIJSEN) AND SURGERY (DIREC TOR PROF S BENGMARK) UNIVERSITY HOSPITAL S-22185 LUND SWEDEN

PERCUTANEOUS TRANSHEPATIC PORTOGRAPHY IN PANCREATIC CARCINOMA

Diagnosis and evaluation of resectability

W REICHARDT and I IHSE

The prognosis for patients with pancreatic carci is poor The results of pancreatico duodenec my according to Whipple have been discouraging OSTER et coll 1967) Therefore a renewed inte in total pancreatectomy has arisen and promis have recently been reported (BROOKS & ULEBRAS 1976 IHSE et coll 1977) Only surgery cure patients with pancreatic malignancy How a proper selection of patients is necessary as surgery is not meaningful once the tumour as grown outside the pancreas (IHSE et coll) Cur diagnostic methods such as ultrasound com er tomography scintigraphy endoscopic retro ade cholangiopancreaticography (ERCP) percu neous transhepatic cholangiography (PTC) and ngiography have increased the possibilities of an accurate preoperative morphologic dia nosis (OKUDA et coll 1974 GOLDSTEIN et coll 974 CLASSEN et coll 1975 SHEEDY et coll 1977 USBAND et coll 1977 TRILLER 1978)

Previously SUZUKI et coll (1972) and TYLÉN & NESJÖ (1973) found a correlation between angio hy (extent of arterial involvement) and operabil ty and survival time BURANASIRI & BAUM (1972) others have emphasized the importance of the enous phase of coeliac and superior mesenteric ography in the evaluation of pancreatic carci Contrast enhancement is improved in direct ortography compared with the venous phase of and more detailed information about morphologic abnormalities is thus obtained

The results of percutaneous transhepatic portography (PTP) and selective phlebography of the pancreatic veins in pancreatic carcinomas have been compared with the findings at angiography Special attention was paid to the diagnostic accuracy and prediction of resectability of the lesions

Material and Methods

During 1973 to 1978 35 patients with microscopically confirmed carcinoma of the head of the pancreas were examined with percutaneous transhepatic portography and selective phlebography of the veins of the head of pancreas at this Department of Diagnostic Radiology As the methods and criteria for evaluation have been described in detail elsewhere (GÖTHLIN et coll 1974 REICHARDT et coll 1978) only a brief summary is now given The portal vein was punctured using a 25 cm long needle coated with a polyethylene catheter (OD 1 6 mm ID 1 0 mm Surgimed Denmark) Contrast medium was injected with the tip of the catheter placed in the superior mesenteric vein In cases involving the confluence the splenic vein was also examined Forty ml of Isopaque Coronar 370 mg I/ml (Nyegaard Norway) was injected at a rate of 8 ml/s 16 films were exposed (5 films/5 s 8 films/4 s 3 films/6 s) After selective catheterization of the pancreatic veins 8 films were exposed (2 films/s) after injection of 2 to 10 ml of contrast medium The amount of contrast medium was adjusted to the size of the vessel and the injection was made by hand

In 33 of the patients a selective angiography was


Submitted for publication 31 May 1979



a



b



c

Fig 1 Carcinoma of the head of the pancreas a) Selective phlebography of the anterior superior pancreaticoduodenal vein Occlusion of the veins of the head The lines represent the shape of the obstructed common bile duct at PTC b) PTP Injection into the superior mesenteric vein Stenosis of the confluence with a pressure gradient of 6 cm H_2O c) PTP Injection into the splenic vein Stenosis of the confluence with a pressure gradient of 10 cm H_2O The tumour was not resectable

performed including injection into the coeliac and superior mesenteric arteries In 31 patients 25 mg Tolazolin was injected directly into the superior mesenteric artery immediately before the injection of contrast medium in order to improve filling of the veins The criteria for evaluation of the angiographic findings were those described previously (LUNDERQUIST 1965 BOOKSTEIN et coll 1969 BURANASIRI

Table I

Radiologic diagnosis in 33 patients with pancreatic carcinoma

	Carcinoma	Suggestion of carcinoma	Pancreatitis	Atheromatosis	Post operative abnormalities	Normal	No adequate examination
Angiography	28	0	0	2	1	2	0
Selective phlebography	21	4	3	0	0	0	5



a



b



c

Fig 2 PTP in three patients with carcinoma of the head of the pancreas Varying extent of venous involvement was observed a) Circular stenosis of the portal vein confluence and splenic vein with irregularity of the wall of the vessels b) Marked stenosis of the superior mesenteric vein close to the confluence c) Impression of the superior mesenteric vein slight stenosis

BAUM) and include Arterial displacement arterial stenosis and occlusion tumour vessels accumulation of contrast medium within the tumour venous displacement and venous stenosis and occlusion

In 34 of the patients obstructive jaundice was the main symptom and percutaneous transhepatic cholangiography was performed before angiography and portography One tumour was detected at elective cholecystectomy In 30 patients extirpability of the tumour was estimated at laparotomy and the findings were compared with those obtained at angiography and phlebography In 2 patients the radiologic results were compared with autopsy findings one and two months after examination respectively One 70 year old patient was not operated upon but palliated with a transhepatically applied endoprosthesis

Results

Angiography In 28 of the 33 patients the tumour diagnosis was made at angiography (Table 1) Arterial encasement limited to small intrapancreatic arteries or tumour vessels was evident in 12 patients and in 11 the gastroduodenal artery was also involved Encasement of other extrapancreatic arteries was



a b

Fig 3 Carcinoma of the head of the pancreas At angiography indication of non resectability a) Venous phase of angiography considered as normal b) PTP revealed impression of the superior mesenteric vein At surgery a tumour 5 cm in diameter was resected radicality was doubtful Lymph node metastases were present

found in 5 patients and in addition 2 had liver metastases

Evaluation of the venous phase of the angio graphy disclosed venous lesions in 7 patients while in 3 venous involvement was suggested In 4 cases no adequate venous filling was obtained

In 5 patients the diagnosis of tumour was not made at angiography No abnormality was found in 2 In 2 patients the vascular abnormalities were er roneously considered as atheromatosis and in both selective phlebography indicated tumour growth In one patient stenosis of the gastroduodenal artery was the only finding but was not of diagnostic value because of previous resection of the stomach Selec tive phlebography disclosed abnormalities sugges tive of pancreatitis The patient died 2 months after angiography and a tumour 2 cm in diameter at the papilla surrounded by pancreatitis was found at au topsy

Portography and selective phlebography In 21 of the 33 patients correct diagnosis was made at selec tive pancreatic phlebography (Fig 1) and in 4 the veins of the head of the pancreas were found to be obliterated suggesting tumour growth (Table I) In 3 cases the veins of the head were irregular sl and either stretched or tortuous indicating pancr tis (REICHARDT et coll REICHARDT 1980) cases the selective phlebography could not evaluated due to extravasation of contrast me and in 3 due to inadequate filling of the pancre veins

Infiltration of the superior mesenteric vein por vein or confluence was found in 4 patients Cr for infiltration were circular stenosis with irregula ty of the wall of the vessels (Fig 2) or tu thrombus A marked stenosis in 12 cases indica tumour growth adjacent to the vessel

Smooth local impression of the vein was found 7 cases in 2 the involvment of the veins w doubtful In 8 cases no involvement of the port the superior mesenteric or the splenic vein w found

Evaluation of resectability Including pa with encasement of the gastroduodenal artery tumours were regarded as non resectable at a graphy In spite of this resection was performed






a b c

Fig 4 Carcinoma of the head of the pancreas a) Simultaneous coeliac and superior mesenteric artery injection Stenosis of the smaller pancreatic arteries Short slight stenosis of the gastroduodenal artery at its origin b) Venous phase of angiography No venous involvement c) PTP Slight impression of the superior mesenteric vein At surgery a tumour 5 cm in diameter was resected radicality was doubtful


of these cases but in 3 surgery was not radical and the patients died within 6 months after surgery One patient in whom radicality was doubtful died 10 months after resection No recurrence was found at autopsy

The portography revealed venous involvement in 23 patients Five of these tumours were resected but in 3 instances not radically In 2 patients with tumours of about 5 cm diameter resection was performed with doubtful radicality (Figs 3 4) In these 5 patients the resection was difficult and the blood loss during operation marked All patients died within 20 months after surgery

In all cases the portography demonstrated the morphologic abnormalities of the portal system more distinctly than did the venous phase of superior mesenteric angiography (Fig 5) In 12 cases the portography disclosed involvement of the portal system undetected at angiography In 4 of these 12 cases non extirpability was already indicated by en



a



b

Fig 5 Carcinoma of the head of the pancreas a) Venous phase of superior mesenteric artery injection Compression of the confluence dilated tributaries of the superior mesenteric vein b) PTP Injection into the superior mesenteric vein revealed placement of the vein marked stenosis and thrombus (→)

casement of extrapancreatic arteries or liver metastases In an additional 3 patients the gastroduodenal artery was encased In 5 patients the involvement of the veins demonstrated at portography was the only sign of non extirpability

Discussion

For diagnosis of a pancreatic carcinoma several methods are available such as ultrasound computer tomography scintigraphy ERCP PTC and angiography In the majority of patients the diagnosis can be cytologically confirmed by fluoroscopically guided fine needle biopsy (TYLÉN et coll 1976 HAAGA & ALFIDI 1976 HO et coll 1977 GOLDSTEIN et coll 1978 EVANDER et coll 1978) As most of the patients with carcinoma of the head of the pancreas are admitted with obstructive jaundice transhepatic cholangiography combined with fine needle aspiration biopsy is the first diagnostic step at this hospital As soon as the diagnosis of a carcinoma is established it is of importance in planning the treatment to determine the extent of the tumour and its extirpability The size of the tumour can be estimated by ultrasound computer tomography and angiography and these methods are also useful for the detection of liver metastases As invasion of the large vessels adjacent to the pancreas is a limiting factor for radical surgery angiography and portography should be the proper method to evaluate the extirpability pr operatively A clear correlation between angiograp ic findings operability and survival time has be demonstrated (SUZUKI et coll TYLÉN & ARNES

Table 2

Carcinomas of the head of the pancreas with venous inv... but without arterial abnormalities indicating n n resectab...

Case	Portography	Angiography venous phase	Surgical findings
1	++	+	Tumour of about 10 cm diameter not resectable
2	++	(−)	Not resectable liver metastases
3	++	−	Tumour of 4 cm diameter resect... not radical
4	++	−	Not resectable
5	+	(+)	Tumour of ?5 cm diameter rese... not radical
6	+	−	Movable liver metastases
7	+	−	Tumour of 5 cm diameter resected radicality doubtful lymph node metastases

++ stenosis
\+ impression or displacement
(+) uncertain involvement
(−) no adequate filling
− no abnormality

order to improve the results of radical surgery a areful selection of patients based on a proper pre rative evaluation of the extirpability of the pan eatic carcinomas is of utmost importance

Previously it has been suggested that involve ent of extrapancreatic arteries is indicative of n extirpability of the tumour SUZUKI et coll und that even encasement of the gastroduodenal ery or several intrapancreatic arteries indicates operability

TYLÉN & ARNESJO found in 26 patients with in olvement of the gastroduodenal artery only 6 re ctable tumours and none of these 6 patients lived ore than 12 months In the present series 11 pa ents had encasement of the gastroduodenal artery 2 of these the tumours were resected in one case e resection was not radical and the patient died 6 onths after surgery The other patient had a very ight stenosis of the gastroduodenal artery at its rigin (Fig 4) possibly caused by atheromatosis hese findings argue for non resectability in cases ith obvious tumour encasement of the gastroduo enal artery It has not been reported to date if ncasement of the main stems of the portal vein ystem is a reliable indication of non extirpability n most of the present patients involvement of the rge veins was combined with abnormalities indi ating non resectability at angiography such as en asement of the gastroduodenal artery or other xtrapancreatic arteries In 7 patients (Table 2) with venous involvement without arterial abnormalities ndicating non extirpability the tumour was regarded n 4 as non resectable at laparotomy Three of these patients were operated upon with resection In 2 the esections were not radical and in one radicality was doubtful and furthermore lymph node metastases were present

Surgery was not radical in any patient with evi dent involvement of the veins In all cases with mi nor displacement of the vessels in which resection was performed the operations were technically diffi cult and complicated by intraoperative bleedings In ? of 5 cases surgery was regarded as radical but with small margin (2 mm) These results suggest that patients with stenosis of the main stems of the portal vein system are not suitable candidates for radical surgery This contradicts the results of MARIONS (1974) who reported at least 2 cases with stenosis of the veins in which resection was considered radical If a localized impression of the portal vein is ob served at portography radical surgery may be attempted but the procedure may be technically diffi cult

The present results indicate the usefulness of por tography in the evaluation of resectability of pan creatic carcinoma The method should be used as a supplement in patients in whom angiography does not give unequivocal information about non resect ability

Resection of tumours encasing the gastroduodenal artery was formerly regarded as worthwhile in low risk patients (TYLEN & ARNESJÖ) As regional intra arterial infusion of cytotstatics has been reported to diminish pain (GAZET 1973) palliative resection no longer seems to be motivated further emphasizing the need for a proper preoperative evaluation of resectability

The diagnosis of pancreatic carcinoma can be made at selective phlebography of the pancreatic veins However in most cases the diagnosis is easi er to obtain with other less invasive methods and phlebography cannot be recommended for diagnos tic routine use A number of cases will still remain where the differentiation between carcinoma and pancreatitis is difficult and in these cases selective phlebography of the pancreatic veins can be of value (REICHARDT et coll REICHARDT)

SUMMARY

In 33 patients with carcinoma of the head of the pan creas both angiography and percutaneous transhepatic portography combined with selective phlebography of the pancreatic veins were performed The tumour diagnosis was made in 28 patients by angiography and in 21 by phlebography Correlation was found between extrapan creatic artery encasement involvement of the main stems of the portal vein system and non resectability of the tu mour In 5 patients venous involvement demonstrated by portography was the only indication of non resectability of the tumours

REFERENCES

BOOKSTEIN J J REUTER S R and MARTEL W Angiographic evaluation of pancreatic carcinoma Radiology 93 (1969) 757

BROOKS J and CULEBRAS J M Cancer of the pan creas Palliative operation Whipple procedure or total pancreatectomy? Amer J Surg 131 (1976) 156

BURANASIRI S and BAUM S The significance of the ve nous phase of celiac and superior mesenteric arterio graphy in evaluating pancreatic carcinoma Radiology 102 (1972) 11

CLASSEN M ANACKER H STADELMANN O SEIFERT E and VON FRITSCH E The diagnosis of tumors of the papilla of Vater and of the pancreas by endoscopic radiologic cholangio-pancreaticography (ERCP) *In* Efficiency and limits of radiologic examination of the pancreas p 203 Edited by H Anacker Thieme Verlag Stuttgart 1975

EVANDER A IHSE I LUNDERQUIST A TYLÉN U and ÅKERMAN M Percutaneous cytodiagnosis of carcinoma of the pancreas and bile duct Ann Surg 188 (1978) 90

FOSTER J H NEILSON R O and DENNIS D L A ten year experience with carcinoma of the pancreas A cooperative study Arch Surg 94 (1967) 332

FREENY P C WEINSTEIN C J TAFT D A and ALLEN F H Cystic neoplasms of the pancreas New angiographic and ultrasonographic findings Amer J Roentgenol 131 (1978) 795

GAZET J C Intraarterial chemotherapy for cancer of the pancreas *In* Modern trends in oncology p 121 Edited by R Raven Butterworth London 1973

GOLDSTEIN H M NEIMANN H L and BOOKSTEIN J J Angiographic evaluation of pancreatic disease Radiology 112 (1974) 275

— — and ZORUOCA J Percutaneous transperitoneal aspiration biopsy of pancreatic masses Amer J dig Dis 23 (1978) 840

GÖTHLIN J LUNDERQUIST A and TYLÉN U Selective phlebography of the pancreas Acta radiol Diagnosis 15 (1974) 474

HAAGA J R and ALFIDI R J Precise biopsy localization by computed tomography Radiology 118 (1976) 603

— — HAVRILLA T R TUBBS R GONZALES L MEANEY T F and CORSI M A Definitive role of CT scanning of the pancreas Radiology 124 (1977) 723

HO C S MCLOUGHLIN M J MCHATTIE J D and TAO L C Percutaneous fine needle biopsy of the pancreas following endoscopic retrograde cholangio-pancreatography Radiology 125 (1977) 351

HUSBAND J E MEIRE H B and KREEL L Com… of ultrasound and computer assisted tomogra… pancreatic diagnosis Brit J Radiol 50 (1977) 8…

IHSE I LILJA P ARNESJÖ B and BENGMARK S T… pancreatectomy for cancer Ann Surg 186 (197…

LUNDERQUIST A Angiography in carcinoma of the p…creas Acta radiol (1965) Suppl No 235

MARIONS O Radiological investigation in jaun… Opusc med (1974) Suppl No 34

OKUDA K TANIKAWA K EMURA T KURATOMI S JINNOUCHI S URABE K SUMIKOSHI T KANDA… FUKUYAMA Y MUSHA H MORI H SHIMOKAWA… YAKUSHIJI F and MATSURA Y Non surgical pe…neous transhepatic cholangiography—diagnostic si…ficance in medical problems of the liver Amer J d… Dis 19 (1974) 21

REICHARDT W Selective phlebography in pancreatic … peripancreatic disease Acta radiol Diagnosis (1980) 513

— LUNDERQUIST A and TYLÉN U Selective phl…graphy in carcinoma of the pancreas Acta radiol Diagnosis 19 (1978) 305

SHEEDY P F STEPHENS D H HATTERY R R and W…LIAMSON B R Computed tomography of the pa…creas Radiol Clin N Amer 15 (1977) 349

SUZUKI T KAWABE K IMAMURA M and HOSHI… Survival of patients with cancer of the pancreas … lation to findings on arteriography Ann Surg 1… (1972) 37

TRILLER J Sonographische Topographie des Pa… Radiologe 18 (1978) 255

TYLÉN U and ARNESJÖ B Resectability and prognosis of carcinoma of the pancreas evaluated by angiogra… Scand J Gastroenterol 8 (1973) 691

— — LINDBERG L G LUNDERQUIST A and ÅKERM… M Percutaneous biopsy of carcinoma of the pa… guided by angiography Surg Gynec Obstet 1… (1976) 1737

Acta Rad ologica Diagnos s 21 (1980) Fasc 5

FROM THE FIRST DEPARTMENT OF SURGERY KYOTO UNIVERSITY MEDICAL SCHOOL KYOTO JAPAN

ANGIOGRAPHY AND PANCREATODUCTOGRAPHY IN RESECTABLE CARCINOMA OF THE PANCREAS

T SUZUKI T MANABE T TANI and T TOBE

In the past decade various radiologic approaches such as angiography pancreatography and cholangiography have been employed in attempts to achieve early detection of carcinoma of the pancreas However the clinical value of these methods particularly in an early stage of malignancy has as yet not been clearly determined

In a previous report (SUZUKI et coll 1979 a) the precise location or extension of a pancreatic tumor could not be satisfactorily established without combined evaluation of both angiography and pancreatoductography which were also of considerable importance for the selection of the proper surgical procedure such as total pancreatectomy Although the diagnostic value of these types of procedures has been evaluated separately no assessment of their combined use seems to have appeared especially of in carcinoma of the pancreas in a resectable stage Therefore an evaluation was made of the combined use of angiography and pancreatoductography for determination of the size and extension of a pancreatic tumor when still resectable as well as an assessment of its value for the surgical management

Material and Methods

Selective angiography and endoscopic retrograde pancreatoductography were successfully performed preoperatively in 51 patients with carcinoma of the pancreas Eighteen of these patients could be operated upon using the Whipple procedure total pancreatectomy or distal pancreatectomy These 18 patients at a resectable stage are the subject of the present evaluation

The clinical diagnosis was confirmed at microscopy In 15 patients the tumor was located in the head in 3 in the body of the pancreas Tumors located in the ampulla of Vater the terminal bile duct or the duodenum were all excluded from the series

In addition to conventional celiac and superior mesenteric angiography in a p projection oblique projections with superselective or pharmacologic technique were used (SUZUKI et coll 1979 b) Endoscopic retrograde pancreatography was performed with an Olympus JFB 2 duodenofiberscope under fluoroscopic control Patients in whom cannulation of the pancreatic duct was unsuccessful were excluded from the series irrespective of the endoscopic detection of duodenal mucosal lesions or cannulation of the common bile duct Laparotomy was carried out in all of the patients within three weeks after the radiologic examinations

The smaller intrapancreatic arteries such as the duodenal branches of the pancreaticoduodenal arteries even if clearly demonstrated at superselective or pharmacologic angiography were frequently difficult to evaluate Similarly at endoscopic retrograde pancreatography the small branches of the main pancreatic duct were sometimes difficult to evaluate Accordingly the assessment of vascular

Submitted for publication 3 December 1979

Table 1

Radiologic findings in 18 resectable carcinomas of the pancreas

Case No	Size of tumor (cm)	Vascular stenosis or obstruction	Ductal stenosis or obstruction	Capsular invasion	Stagnation of pancreatic secretion
1	1 5×1 0	−	−	−	−
2	1 7×1 7	−	+	−	+
3	2 0×1 5	−	+	−	+
4	2 0×1 5	+	+	−	+
5	[illegible] 0×1 7	−	+	−	+
6	2 5×1 2	−	+	+	+
7	3 0×1 5	+	+	+	+
8	3 0×[illegible]	−	+	+	+
9	3 0×2 0	+	−	+	−
10	4 0×3 5	+	+	+	+
11	4 0×4 0	+	−	+	−
12	4 2×3 0	+	+	+	−
13	5 0×3 0	+	+	+	+
14	5 0×4 0	+	+	+	+
15	5 5×3 5	+	+	+	+
16	6 0×6 0	+	+	+	+
17	6 5×4 0	+	+	+	+
18	7 0×6 0	+	+	+	+

invasion by tumor was based on evaluation of the vessels down to the level of the pancreaticoduodenal dorsal pancreatic pancreatica magna and transverse pancreatic arteries and the splenic and superior mesenteric veins The assessment of ductal invasion was based on abnormalities of the main pancreatic duct The indication of tumor invasion was considered to be stenosis or obstruction of these vessels or of the duct Displacement stretching pooling of contrast medium or peripheral defects were not used as diagnostic criteria in the present series because such abnormalities are not always specific for malignancy

Based on the combined evaluation of presence or absence of vascular and ductal tumor invasion the radiologic results were divided into four groups (1) no vessel or duct abnormalities indicating tumor (2) no vessel but duct abnormalities (3) vessel but no duct abnormalities (4) both vessel and duct abnormalities The radiologic results were correlated with the findings in the resected specimens such as vascular and capsular invasion of the tumor and stagnation of secretion in the distal pancreas

Because retrograde cannulation of the choledochus was not possible in all of the cases concomitant evaluation of the common bile duct was not performed

Table 2

Comparison of vascular and ductal morphology in resectable and unresectable carcinoma of the pancreas

Radiologic group	Resectable cases	Unresectable cases	Total
1	1	0	1
2	5	0	5
3	2	2	4
4	10	31	41
Total	18	33	51

Results

Of the 18 patients with resectable tumors one was classified as belonging to group 1 5 to group 2 2 to group 3 and 10 to group 4 Accurate diagnosis of these lesions with pancreatoductography alone was obtained in 83 per cent with angiography alone in 67 per cent while combination of the methods increased the diagnostic accuracy to 94 per cent

Measurements of the resected specimens showed that the size of tumors in centimeters ranged from 1 5×1 0 to 7 0×6 0 on cut sections the maximum diameter ranging from less than 2 cm (5 tumors) to

Table 3

Incidence of capsular involvement and stagnation of pancreatic secretion in resectable and unresectable carcinoma of the pancreas

Radiologic group	Resectable cases			Unresectable cases		
	No of cases	Capsular invasion	Stagnation of pancreatic secretion	No of cases	Capsular invasion	Stagnation of pancreatic secretion
1	1	0	0	0	-	-
2	5	2	5	0	-	-
3	2	2	0	2	?	0
4	10	9	9	31	31	31
Total	18	13	14	33	33	31

intermediate group of 2 to 4 cm (6 tumors) to ore than 4 cm (7 tumors)

Lesions 2 cm or less in size belonged to the graphic groups 1 2 or 4 while all lesions of ore than 4 cm in diameter belonged to group 4 hose ranging from 2 to 4 cm in size belonged to 2 3 or 4

The indication for total pancreatectomy for carma of the pancreas is closely related both to mor infiltration of the capsule of the pancreas and stagnation of secretion in the distal pancreas which were assessed by combined evaluation of the uctal and vascular morphology

Five tumors did not invade the capsule one in 1 and 4 and 3 in group 2 The remaining 13 11 of which had vascular invasion demnstrated at angiography involved the capsule of he gland

Stagnation of secretion in the distal pancreas due to obstruction or stenosis of the main pancreatic by a tumor in the head was not demonstrated in cases one in group 1 2 in group 2 one in group 4 the latter one the secretion in the distal part of the was drained by an accessory pancreatic duct the main pancreatic duct being obstructed by tumor involvement The remaining 14 cases all with manifest invasion of the main pancreatic duct on pancreatoductography also exhibited stagnation of pan reatic secretion These results are summarized in Table 1

Preoperative angiography and pancreatoductography were successfully carried out in 33 patients with *unresectable* carcinoma of the pancreas on whom either by pass operation or exploratory laparotomy was performed Of these 33 cases 2 belonged to group 3 while 31 belonged to group 4 The former 2 tumors originated from the region of the uncinate process None of these tumors belonged to groups 1 or 2 Thus the diagnostic accuracy of pancreatoductography and angiography in the unresectable series of tumors was 94 and 100 per cent respectively The preoperative findings in the resectable and unresectable series are listed in Table 2

All the unresectable tumors had a marked extension outside the capsule of the pancreas Stagnation of pancreatic secretion was also revealed in all lesions except in the two tumors originating in the uncinate process

The incidence of capsular involvement or stagnation of pancreatic secretion in both resectable and unresectable carcinoma appears in Table 3

Discussion

It has been widely accepted that angiography and pancreatoductography are the most effective procedures at present in the diagnosis of carcinoma of the pancreas but no report has attempted to correlate these two approaches especially with regard to the diagnosis of the tumor at a resectable stage

In this series of 18 resectable carcinomas of the pancreas the findings at preoperative angiography and endoscopic retrograde pancreatoductography were analyzed Pancreatoductography demonstrated tumors as small as 2 cm in diameter especially when located adjacent to the duct On the other hand angiography was more useful in identifying carcinoma arising in the uncinate portion or the subcapsular region of the pancreas which was not

accessible at pancreatoductography even when the lesions were too advanced to permit resection (SUZUKI et coll 1972 1979a)

The diagnostic possibility to demonstrate relatively small tumors at angiography has been evaluated by several authors BOOKSTEIN et coll (1969) reported 8 lesions less than 5 cm in diameter at the time of surgery one with normal pancreatic vessels another 3 with nonspecific abnormalities The remaining 4 lesions were confidently diagnosed as malignant the smallest being 1 5 cm in diameter According to RANNIGER & SALDINO (1969) the tumor size in the angiographically diagnosed cases of pancreatic carcinoma varied from approximately 2 5 to 5 5 cm in diameter The same range was also present in cases with normal angiography In TYLÉN s (1973) series 6 patients had tumors 1 to 4 cm in diameter In 4 of these encasement of small arteries in the head of the pancreas was demonstrated According to MACGREGOR & HAWKINS (1973) 2 patients with carcinoma of 1 5 cm in diameter in the head of the pancreas were correctly diagnosed angiographically both patients were treated by the Whipple procedure

In the present series as far as the vessels up to the level of the pancreaticoduodenal arteries and the superior mesenteric vein are concerned the smallest tumor which could be disclosed by angiography measured 2 0 cm × 1 5 cm (in the head of the pancreas) while the largest tumor not identified at angiography was 3 0 cm in diameter (in the neck of the pancreas) Both these tumors were diagnosed by pancreatoductography

HALL et coll (1978) made a prospective evaluation of endoscopic pancreatography in the diagnosis of periampullary tumor Two tumors of the head of less than 2 cm were diagnosed at pancreatoductography 3 of 13 resectable carcinomas were not detected

In the present series the diagnostic accuracy of angiography and pancreatoductography in a resectable stage of carcinoma was 66 and 83 per cent respectively By combined evaluation of these procedures the diagnostic accuracy was improved to 94 per cent suggesting that the vascular and the ductal abnormalities demonstrated are complementary In fact the smaller tumors originating in the vicinity of the pancreatic duct could be assessed by ductography while those in the uncinate portion were identified by angiography rather than ductography

Total pancreatectomy has been attempted for carcinoma of the head of the pancreas to improve dismal results after the Whipple procedure H ever long survival has not been attained even a total pancreatectomy except in patients wi tumor growth outside the capsule of the panc Almost all patients in whom vascular involve was revealed at angiography had macroscopic c cerous invasion of the capsule of the pancreas order to attain a long survival after surgery it wo seem important to carry out total pancreatect before vascular involvement is manifest at preope tive angiography

It has been pointed out that stagnation of sec tion in tumor of the head offers optimum cond for transductal or translymphatic metastatic s in the pancreatic tissue peripheral to the tu (NAKASE et coll 1977) implying that total p createctomy should be indicated for carcinoma the head when associated with stagnation of p creatic secretion In the present series almo tumors with invasion of the main pancreatic d pancreatoductography had evidence of stagna the distal part of the pancreas In this respect pancreatoductography provides a helpful tool decision on total pancreatectomy Thus for se tion of the proper surgical procedure in an e stage of pancreatic carcinoma both the ductal the vascular invasion demonstrated at preopera radiography has significant importance

SUMMARY

Angiography and pancreatoductography were p formed in 18 patients with resectable carcinoma of pancreas The presence or absence of vascular and d tumor involvement was evaluated Accurate diag was obtained in 83 per cent at pancreatoductogra alone in 66 per cent at angiography alone while comb tion of the methods resulted in 94 per cent accura Tumor involvement of the capsule and secretion s tion in the distal part of the pancreas are of importan the surgical management and the survival after rese An improved result after surgery may be obta combined evaluation of the vascular and ductal morph gy as demonstrated at preoperative radiography

Request for reprints Dr Takashi Suzuki First De ment of Surgery Kyoto University Medical S Sakyo-ku Kyoto Japan 606

REFERENCES

BOOKSTEIN J J REUTER S R and MARTEL W A graphic evaluation of pancreatic carcinoma Radi 93 (1969) 757

ALT T J BLACKSTONE M O COOPER M J HUGHES R G and MOOSSA A R Prospective evaluation of endoscopic retrograde cholangiopancreatography in the diagnosis of periampullary cancers Ann Surg 187 (1978) 313

ACGREGOR A M C and HAWKINS JR I F Selective pharmacodynamic angiography in the diagnosis of carcinoma of the pancreas Surg Gynec Obstet 137 (1973) 917

AKASE A KOIZUMI T FUJITA N ONO H MATSUMOTO Y and HONJO I Studies of the growth and infiltration of experimental tumor of the pancreas in rabbits Amer J Surg 133 (1977) 590

ANNIGER K and SALDINO R M Arteriographic diagnosis of pancreatic lesions Radiology 86 (1966) 470

LDINGER S I Catheter replacement of the needle in percutaneous arteriography A new technique Acta radiol 39 (1953) 368

SUZUKI T IMAMURA M TAMURA K SUMIYOSHI A SAKANASHI S NISHIMURA Y and TOBE T (a) Correlative evaluation of angiography and pancreatoductography in relation to surgery for cancer of the pancreas Surgery 85 (1979) 644

— — MATSUOKA K and TOBE T (b) Surgical importance of oblique projection in arteriography for cancer of the pancreas Surg Gynec Obstet 148 (1979) 847

— KURATSUKA H UCHIDA K MATSUMOTO Y and HONJO I Carcinoma of the pancreas arising in the region of the uncinate process Cancer 30 (1972) 796

TYLÉN U Accuracy of angiography in the diagnosis of carcinoma of the pancreas Acta radiol Diagnosis 14 (1973) 449

FROM THE DEPARTMENT OF DIAGNOSTIC RADIOLOGY UNIVERSITY HOSPITAL S 22185 LUND SWEDEN

COMPLICATIONS OF PERCUTANEOUS TRANSHEPATIC CATHETERIZATION OF THE PORTAL VEIN AND ITS TRIBUTARIES

J HOEVELS A LUNDERQUIST and T OWMAN

The direct approach to the portal venous circula on by percutaneous transhepatic puncture and ltheterization is by now a widely accepted radio aphic method which has been used for (1) Dia iostic and therapeutic procedures in patients with rrhosis of the liver portal hypertension and bleed g esophageal varices (2) selective venous blood impling and hormone assay for diagnosis and loca zation of endocrine gastro-intestinal and pancreatic imors (3) portal spleno mesenteric and pancreatic hlebography in the evaluation of tumor resectability ı patients with carcinoma of the extrahepatic bile ucts or the pancreas and for evaluation of (4) the iagnostic effectiveness of portal phlebography in atients with malignant lesions of the liver

Previously the technical aspects of percutaneous ranshepatic portography and pancreatic mesen eric and gastro esophageal phlebography have een described (LUNDERQUIST & VANG 1974 ,OTHLIN et coll 1974 LUNDERQUIST & TYLEN 1975 HOEVELS 1978 HOEVELS et coll 1978 REICHARDT et coll 1978) The purpose of the pres nt report is to assess the type and rate of complica tions of these procedures in a large series

Technique

As patency of the portal vein is a prerequisite for any kind of percutaneous transhepatic examination of the portal and splanchnic venous systems celiaco mesenteric angiography was performed first In the majority of cases the concentration of the contrast medium in the venous phase of superior mesenteric angiography was enhanced by selective injection of 25 mg of Tolazolin hydrochloride in the superior mesenteric artery In elective examina tions a platelet count below $50\times10^9/l$ and a pro longed prothrombin time were considered as con traindications to the percutaneous transhepatic catheterization of the portal vein However in se vere acute variceal bleeding the portography and obliteration of varices were performed in spite of prolonged prothrombin time in patients in whom other methods had failed to stop the bleeding

Percutaneous transhepatic portography was per formed from the right mid axillary line after pre medication with 10 mg diazepam and 0 5 mg atropin After local anesthesia a 25 cm long stylet fitted with an at fluoroscopy discernible catheter (OD/ID 1 6/ 1 0 mm Surgimed A/S Olstykke Denmark) was inserted under fluoroscopy parallel to the table top towards the area directly cranial to the estimated position of the liver hilum The stylet was im mediately removed and the catheter slowly with drawn until blood was freely aspirated After iden tification of a branch from the portal vein by injec tion of contrast medium a guide wire with a slightly curved soft tip was introduced through the catheter

Submitted for publication 26 February 1980

Table 1

Indication for percutaneous transhepatic catheterization of portal venous system and type of examination (440 examinations in 398 patients)

Indication	Percutaneous transhepatic portography	Mesenteric/ splenic phlebography	Transhepatic obliteration of esophageal varices	Pancreatic phlebography
Cirrhosis portal hypertension esophageal varices	198	140/165	73	-
Possible primary or metastatic liver tumor	110	-	-	-
Possible malignant lesion in porta hepatis or hepatoduodenal ligament	28	12/18	-	5
Periampullary carcinoma	37	18/25	-	29
Pancreatitis	5	5/5	-	5
Localization of hormone producing tumor of pancreas	45	15/45	-	45
Localization of hormone producing tumor of bowel or mesentery	17	17/12	-	-
Total	440	207/270	73	84

Portography mesenteric splenic and pancreatic phlebography were performed for evaluation of tumor resectability The diagnosis of such a carcinoma was made with one or several other methods i e *percutaneous transhepatic cholangiography ERCP computer tomography ultrasound examination* combined with fine needle aspiration biopsy and cytology

and manipulated into the main stem of the portal vein The catheter was then pushed over the guide wire into the main stem of the portal vein

A cranially (i e upwards medially) directed puncture was avoided as this results in an intrahepatic angulation of the catheter rendering manipulation of the catheter for selective procedures difficult or impossible In the majority of cases the catheterization of the portal vein was achieved after 2 to 5 puncture trials but in single patients 6 to 10 punctures were needed in order to find a portal vein branch The catheter was not completely withdrawn from the liver before a repuncture was performed to limit the number of puncture holes in the liver capsule and thereby reducing the risk of bleeding into the abdominal cavity Portal venous pressure was recorded using an open manometer in portal hypertensive patients The technique of percutaneous transhepatic puncture and catheterization of the portal vein and its tributaries is described in detail elsewhere (HOEVELS HOEVELS et coll)

Selective catheterization of the left gastric and short gastric veins was performed when these vessels participated in the collateral circulation to gastro-esophageal varices Following selective injection of contrast medium into those veins they were obliterated by injection of various compounds using Bucrylate (isobutyl 2 cyanoacrylate LUNDERQUIST & VANG 1974 LUNDERQUIST et coll 1977 197[illegible]

Catheterization of the splenic intestinal and pancreatic veins for demonstrating the morphology [illegible] blood sampling was performed using [illegible] shaped guide wires (LUNDERQUIST et coll 197[illegible] REICHARDT et coll 1979 REICHARDT & I[illegible]MANSSON 1980) It was regarded essential to [illegible] catheterization with the catheter alone as this [illegible] found to increase the risk of injury to the wall of the blood vessels


When the examination was completed a small piece of gelfoam was injected through the catheter beneath the liver capsule in order to seal the puncture tract

Material

The series included 406 patients ranging from [illegible] to 83 years of age In 8 of these [illegible] catheterization of the portal vein failed Al[illegible]



a



b

ig 1 a) Percutaneous transhepatic portography Subintimal injection of contrast medium with elevation of the intima (→) medially in main stem of portal vein b) Subintimal deposit of contrast medium around tip of catheter

40 examinations were performed in the remaining 98 patients one examination in 366 patients 2 in 3 3 in 8 and 4 in one patient

The indications for percutaneous transhepatic atheterization of the portal and splanchnic veins nd the type of examination in the patients in whom he procedures succeeded are given in Table 1 In he 8 patients in whom the examination failed the ndications were liver cirrhosis portal hypertension and esophageal varices in 4 cases possible liver netastases in 3 and an endocrine tumor of the pancreas in one case

Complications

The complications accounted for were exclusively related to mechanical injury to the liver tissue the blood vessels bile ducts or gallbladder respectively In the majority of cases the lesions were detected at fluoroscopy during the examination (i e extravasation of contrast medium subintimal injection leakage of medium subcapsularly and on the surface of the liver puncture of the gallbladder or of the inferior vena cava displacement of the liver from the right abdominal wall because of massive intraabdominal bleeding) or on films after completion of the examination (area without accumulation of contrast medium in the parenchymal phase of the portography indicating occlusion of portal vein branches or hematoma of the liver)

Extravasation of contrast medium into the hepatoduodenal ligament mesentery or retroperitoneal space occurred in 35 patients following penetration of the wall of the portal mesenteric or splanchnic veins by the tip of the catheter The patient usually experienced pain which ceased spontaneously within 15 to 30 min Subintimal injection was observed in the main stem of the portal vein (Fig 1) left main branch of the portal vein splenic or mesenteric veins in 32 cases without causing symptoms


Serious lesions which were related to the percutaneous transhepatic puncture and catheterization in general became clinically symptomatic shortly after the examination Complications demanding surgical intervention (i e massive intraabdominal hemorrhage massive bile leakage to the abdominal or pleural space) usually occurred within 48 hours after the percutaneous transhepatic examination

Clinically relevant complications in the total material of 448 examinations (440 successful and 8 unsuccessful puncture attempts of the portal venous system) occurred in 41 examinations (9 2%) and consisted of 23 cases (5 1%) of intraabdominal hemorrhage and one uncontrollable external bleeding from the puncture site Of these three mortalities

a



b



c

Fig 2 Superior mesenteric and celiac angiographies following multiple unsuccessful puncture attempts of the intrahepatic portal venous system a) Venous phase of superior mesenteric angiography Occlusion of the main stem of the portal vein combined with multiple collaterals to the liver in the hepa[illegible] ligament b) Celiac angiography Large pseudoaneurysm [illegible] left liver lobe c) Late phase of hepati[illegible] angiography [illegible] leakage of contrast medium from pseud[illegible]aneurysm



Fig 3 Hepatic angiography Large fusiform pseudoaneurysm (→) in the central part of the right liver lobe following percutaneous transhepatic portography 6 and 2 weeks previously

...irred because of uncontrollable hemorrhage (Table 2) Two patients had bleeding into the right ... space and 6 leakage of ascitic fluid into the pleural space In 5 cases bile effusion occurred into the right pleural space and in 4 unintentional puncture of the gallbladder Three of the patients with intraabdominal hemorrhage belong to the first ... cases in the present series and at that time a ... puncture catheter (OD/ID 2 2/1 4 mm) was used This catheter was subsequently replaced by a narrower catheter (OD/ID 1 6/1 0 mm)

One patient with liver cirrhosis and severe coagulopathy died from bleeding from the puncture site and generalized gastrointestinal hemorrhage Two patients with extrahepatic cholestasis due to a periampullary carcinoma died because of intraabdominal bleeding In the latter 2 patients the examination was performed in combination with percutaneous transhepatic intubation of the bile ducts for drainage

Laparotomy had to be performed in 7 patients because of intraabdominal hemorrhage Four of these had either cirrhosis of the liver or obstruction of the extrahepatic bile ducts because of a malignant tumor In 2 patients an approximately 2 cm long tear of the liver capsule at the site of the puncture with continuous hemorrhage was found and sutured In 4 patients blood clots were found at the puncture site on the liver surface or in the abdominal cavity No other bleeding source was found and spontaneously ceased hemorrhage from the puncture tract was thought to explain the intraabdominal blood Severe bleeding from a hepatic aneurysm into the abdominal cavity necessitated ligation of the feeding artery in one case in which angiography had not been performed to demonstrate portal vein patency Angiography after multiple unsuccessful transhepatic puncture attempts showed occlusion of the portal vein and hemorrhage from a large pseudoaneurysm in the left lobe of the liver (Fig 2)

Clinical suggestion of bleeding into the abdominal cavity was present in an additional 14 patients Seven of these received blood transfusion whereas in the remaining 7 cases no therapy was needed

In the vast majority of cases a small (<4 cm × 4 cm) subcapsularly located region was observed adjacent to the puncture catheter without accumulation of contrast medium in the sinusoidal phase of the transhepatic portography This was regarded as caused by a small subcapsular hematoma

Hepatic angiography was performed in 32 patients at intervals ranging from 1 to 8 months after a percutaneous transhepatic portography In one of these cases a 0 5 cm × 2 0 cm fusiform aneurysm (Fig 3) had developed originating from a segmental artery of the right lobe of the the liver In 5 patients a small subcapsular lesion suggesting hematoma was seen

Repeat transhepatic portography in patients with portal venous hypertension or a suggested endocrine tumor of the pancreas respectively demonstrated a lesion in the right lobe of the liver in 12 cases probably a hematoma One of these patients was operated upon 6 months later because of an insulinoma and a large organized hematoma of the liver (Fig 4) was confirmed However hepatic surgery was not considered necessary

Total occlusion of the superior mesenteric vein was found in one patient Thrombi in the extra or intrahepatic branches of the portal vein were demonstrated in 18 patients all of whom had cirrhosis of the liver and portal hypertension

Total or partial thrombosis of the portal vein after selective occlusion of the left or short gastric veins in patients with hepatofugal blood flow to gastroesophageal varices has been reported from this clinic (BENGMARK et coll 1979) However thrombus formation is probably not induced by the puncture and catheterization of the portal venous



a



b

Fig 4 a) Percutaneous transhepatic portography and pancreatic phlebography in a patient with insulinoma Normal portography b) Repeat portography 6 months later Large space-occupying lesion subcapsular in cranial and lateral parts of right liver lobe with displacement of the adjacent intrahepatic portal branches Compression of portal vein branches in liver hilum mass lesion At operation an organized hematoma but no tumor was found

system but related mainly to the alteration of the hemodynamics in the portal and splanchnic veins resulting from the sudden occlusion of portal systemic collaterals Therefore this complication is not considered in the present context

Sepsis following the transhepatic portography in patients with non dilated bile ducts was not observed Temporary slight rise of temperature after the examination was not considered a complication High fever indicating seeding of bacteria or toxic agents into the blood circulation or signs of cholangitis were only observed when portography and transhepatic drainage of the biliary tract were performed simultaneously in patients with dilated bile ducts because of extrahepatic stasis In such cases the complication was not attributed primarily to the portography but to the combined access to the portal and bile duct systems In patients with longstanding biliary stasis and percutaneous transhepatic bile drainage a high risk of asymptomatic biliary infection exists (HANSSON et coll 1979) which may result in bacterial seeding into the blood circulation when portography is performed

Unintentional puncture of the gallbladder occurred in 4 patients resulting in temporary pain under the right costal margin in 3 cases In the remaining patient an exploratory laparotomy had to be performed because of possible generalized bile peritonitis A perforation of the neck of the gallbladder with continuous bile leak was found and cholecystectomy performed

Discussion

The direct percutaneous approach to the liver for various diagnostic and therapeutic methods is widely used Although procedures such as fine needle aspiration biopsy percutaneous transhepatic cholangiography and percutaneous non surgical bile duct intubation for drainage are regarded as low risk methods a variety of important complications are on record (LEVINSON et coll 197? We

Table 2

Complications of percutaneous transhepatic access to portal vein and its tributaries (n = 448)
Puncture and catheterization of portal vein successful in 440 cases unsuccessful in 8 cases

	No of cases	Procedure after complication or outcome
Patients with cirrhosis and portal hypertension (n=202)		
Intraabdominal hemorrhage	9	Exploratory laparotomy in 3
Generalized gastrointestinal hemorrhage plus bleeding from puncture site	1	Lethal
Right sided hemothorax	2	Drainage
Ascitic leakage to right pleural cavity	6	Drainage in 3
Patients with extrahepatic cholestasis (n=68)		
Intraabdominal hemorrhage	8	Lethal in 2 exploratory laparotomy in 1
Bile effusion in right pleural cavity	5	Drainage in 3
Patients without extrahepatic cholestasis (n=178)		
Intraabdominal hemorrhage	6	Exploratory laparotomy in 3
Unintentional puncture of gallbladder	4	Exploratory laparotomy in 1

Combined (i e simultaneous) portography and percutaneous transhepatic bile duct intubation for drainage
In one of these cases bleeding resulted from a hepatic aneurysm after unsuccessful puncture attempts of portal vein

TER et coll 1976 JULER et coll 1977 JAIN et coll 1977 TYLÉN et coll 1977 OKUDA et coll 1978) A puncture of the liver for bile duct intubation or portography implies the risk of damaging the liver parenchyma the bile ducts and the various venous and arterial hepatic vessels A review of the frequency of vascular lesions of the liver due to non surgical bile duct intubation showed that aneurysms arterio-portal venous and arterio hepatic venous fistulae may develop (HOEVELS & NILSSON 1980) However in the vast majority of cases these lesions seemed to be clinically irrelevant confirming the results of other authors (WALLACE et coll 1972 HELLEKANT 1976 MOSKOWITZ et coll 1978) Theoretically the same type of vascular injury in the liver following transhepatic portography may occur owever reliable data are not available from this Angiography after the portography was per in 32 of the 440 examinations only and strated an intrahepatic aneurysm in one patient and a probable subcapsular hematoma in 5 patients

Complications reported following transhepatic puncture and catheterization of the portal vein have been intraperitoneal hemorrhage (VIAMONTE JR et coll 1975 1977 SCOTT et coll 1976 WIDRICH et coll 1978) perforation of visceral veins (VIAMONTE JR et coll 1977) bleeding caused by inadvertent puncture of an intercostal artery (PEREIRAS et coll 1977) perforation of the right flexure of the colon (WIDRICH et coll 1976 BURCHARTH 1979) ascitic pleural effusion (GUNTHER et coll 1977) right sided hemothorax (SCOTT et coll 1976 GUNTHER et coll 1977 DEIMER et coll 1978) fatal hemorrhage from a tear in the inferior vena cava (DEIMER et coll 1978) and from hepatic puncture wounds (SCOTT et coll 1976) and perforation of the duodenum (WIDRICH et coll 1978)

Three patients in the present series died shortly after the transhepatic procedure One of these who had cirrhosis of the liver and severe coagulopathy bled into the gastrointestinal tract and from the puncture site through the skin and subcutaneous tissue Therefore the transhepatic portography was regarded as a contributing factor to the uncontrollable exsanguination The remaining 2 patients died because of massive intraabdominal hemorrhage following the portography in combination with percutaneous intubation of the bile ducts for drainage A large hepatic artery was punctured in the area of

the hilum of the liver in one of these patients probably being the bleeding source At autopsy large masses of clots were found in the abdomen but in none of these cases was a major lesion of the liver parenchyma or hepatic vessels found Puncture of segmental hepatic arteries was observed in several additional cases without subsequent clinical complications Occlusion of the punctured artery or the formation of a pseudoaneurysm (Fig 3) may however be the sequelae of this type of vascular trauma

The significance of subintimal injection in the portal vein or its main tributaries remains unknown No symptoms indicating subsequent portal vein thrombosis due to the lesion occurred The possibility of local thrombus formation at the site of the intimal lesion cannot be ruled out

The risk of large hepatic hematomas is evident (Fig 4) However the frequency of such hematomas cannot be concluded from this series because repeat examinations were not performed in the majority of cases

The origin of intraabdominal bleeding in most cases is apparently the puncture tract through the liver parenchyma Sealing of the catheter tract by gelfoam particles seems to reduce the risk of bleeding markedly No severe intraabdominal hemorrhage occurred in patients who were treated with this prophylactic measure

Accidental puncture of non dilated intrahepatic bile ducts was made in at least 30 patients without any side reactions Puncture of a non dilated gallbladder surprisingly resulted in bile peritonitis in one of four patients Therefore it is to be recommended in case of inadvertent gallbladder puncture to aspirate its content before withdrawing the catheter

In conclusion serious complications after percutaneous transhepatic catheterization of the portal vein and its tributaries are few but the risk of fatal bleeding seems not totally avoidable Serious complications most often occur in severely ill patients such as those with cirrhosis of the liver coagulopathy and bleeding esophageal varices or in patients with longstanding extrahepatic cholestasis

SUMMARY

The complications of percutaneous transhepatic catheterization of the portal vein and its tributaries were assessed in 406 patients in whom 440 examinations had been performed and 8 unsuccessful attempts Clinically relevant complications consisting of abdominal or ex[illegible] hemorrhage occurred in 24 cases with fatal outcome [illegible] Complications involving the right pleural space occ[illegible] in 13 patients collection of ascitic fluid in 6 bile eff[illegible] in 5 and bleeding in 2 Laparotomy was needed in 7 c[illegible] due to intraabdominal hemorrhage The gallbladder [illegible] unintentionally punctured in 4 cases Furthermore a v[illegible]ety of minor complications of little clinical signific[illegible] such as extravasation of contrast medium subintimal [illegible]jection of contrast medium and minor intrahe[illegible] hematomas were observed

REFERENCES

BENGMARK S BÖRJESSON B HOEVELS J JOELSSON B LUNDERQUIST A and OWMAN T Obliteration of esophageal varices by PTP—a follow up of 43 patients Ann Surg 190 (1979) 549

BURCHARTH F Percutaneous transhepatic portograph[illegible] I Technique and application Amer J Roentgenol 132 (1979) 177

DEIMER E FUNOVICS J und MULLER M Zur trans[illegible]hepatischen Verodung blutender Ösophagusva[illegible] bei der Leberzirrhose Fortschr Rontgenstr 1[illegible] (1978) 119

GÖTHLIN J LUNDERQUIST A and TYLÉN U Sele[illegible] phlebography of the pancreas Acta radiol Diagn[illegible] 15 (1974) 474

GUNTHER R KURTENBACH P GEORGI M Sch[illegible] H D und FARACK U Perkutane transhep[illegible] Thrombosierung der Vena coronaria ventriculi be[illegible] Ösophagusvarizenblutung Fortschr Rontgenstr 1[illegible] (1977) 6

HANSSON J A HOEVELS J SIMERT G TYLÉN U an[illegible] VANG J Clinical aspects of nonsurgical percutaneous transhepatic bile drainage in obstructive lesions of t[illegible] extrahepatic bile ducts Ann Surg 18[illegible] (1979) [illegible]

HELLEKANT C Vascular complications following need[illegible] puncture of the liver Acta radiol Diagnosis 17 (19[illegible] 209

HOEVELS J Ergebnisse der perkutanen transhep[illegible] Portographie Fortschr Rontgenstr 128 (1978) [illegible]

— and NILSSON U Intrahepatic vascular lesions [illegible]ing nonsurgical percutaneous transhepatic bile duct [illegible]tubation Gastrointest Radiol 5 (1980) 127

— LUNDERQUIST A and TYLÉN U Percutaneous tra[illegible]hepatic portography Acta radiol Diagnosis 19 (19[illegible] 643

JAIN S LONG R G SCOTT J DICK R and SHERLOCK S Percutaneous transhepatic cholangiography using the Chiba needle—80 cases Brit J Radiol 50 (19[illegible] 175

JULER G L CONRAY R M and FUELLEMAN R W E[illegible] leakage following percutaneous transhepatic cho[illegible]giography with the Chiba needle Arch Surg 1[illegible] (1977) 954

LEVINSON J D OLSEN G TERMAN J W CLEAVE[illegible] C R GRAHAM JR C P and BREEN K J Hem[illegible] secondary to percutaneous liver biopsy Arch [illegible] Med 130 (1972) 396

LUNDERQUIST A and TYLEN U Phlebography of the pancreatic veins Radiologe 15 (1975) 198

— and VANG J Sclerosing injection of esophageal varices through transhepatic selective catheterization of the gastric coronary vein A preliminary report Acta radiol Diagnosis 15 (1974) 547

— — Transhepatic catheterization and obliteration of the coronary vein in patients with portal hypertension and esophageal varices New Engl J Med 291 (1974) 646

— BORJESSON B OWMAN T and BENGMARK S Isobutyl 2-cyanoacrylate (Bucrylate) in obliteration of gastric coronary vein and esophageal varices Amer J Roentgenol 130 (1978) 1

— SIMERT G TYLÉN U and VANG J Follow up of patients with portal hypertension and esophageal varices treated with percutaneous obliteration of gastric coronary vein Radiology 122 (1977) 59

— ERIKSSON M INGEMANSSON S LARSSON L I and REICHARDT W Selective pancreatic vein catheterization for hormone assay in endocrine tumors of the pancreas Cardiovasc Radiol 1 (1978) 117

MOSKOWITZ H POLIVY C HACKFORD A W MANN N and IOSEL M Complications of Chiba needle transhepatic cholangiography Brit J Radiol 51 (1978) 541

OKUDA K MUSHA H NAKAJIMA Y TAKAYASU K SUZUKI Y MORITA M and YAMASAKI T Frequency of intrahepatic arteriovenous fistula as a sequela to percutaneous needle puncture of the liver Gastroenterology 74 (1978) 1204

PEREIRAS R VIAMONTE JR M RUSSELL E LEPAGE J WHITE P and HUTSON D New techniques for interruption of gastroesophageal venous blood flow Radiology 124 (1977) 313

REICHARDT W and INGEMANSSON S Selective vein catheterization for hormone assay in endocrine tumours of the pancreas Technique and results Acta radiol Diagnosis 21 (1980) 177

— LUNDERQUIST A and TYLEN U Selective phlebography in carcinoma of the pancreas Acta radiol Diagnosis 18 (1978) 305

— INGEMANSSON S LUNDERQUIST A and NOBIN A Selective mesenteric phlebography in patients with carcinoid tumors Gastrointest Radiol 4 (1979) 179

SCOTT J LONG R DICK R and SHERLOCK S Percutaneous transhepatic obliteration of gastroesophageal varices Lancet II (1976) 53

— — — — Percutaneous transhepatic catheterization and sclerosis of bleeding varices Gut 17 (1976) 390

TYLEN U HOEVELS J and VANG J Percutaneous transhepatic cholangiography with external drainage of obstructive biliary lesions Surg Gynec Obstet 144 (1977) 13

VIAMONTE JR M PEREIRAS R RUSSELL E LEPAGE J and HUTSON D Transhepatic obliteration of gastroesophageal varices Results in acute and nonacute bleeders Amer J Roentgenol 129 (1977) 237

— LEPAGE J LUNDERQUIST A PEREIRAS R RUSSELL E VIAMONTE M and CAMACHO M Selective catheterization of the portal vein and its tributaries Radiology 114 (1975) 457

WALLACE S MEDELLIN H and NELSON R S Angiographic changes due to needle biopsy of the liver Radiology 105 (1972) 13

WALTER J F PAASO B T and CANNON W B Successful transcatheter embolic control of massive hematobilia secondary to liver biopsy Amer J Roentgenol 127 (1976) 847

WIDRICH W C ROBBINS A H NABSETH D C O HARA E T JOHNSON W C and LOUGHLIN K V Portal hypertension changes following selective splenorenal shunt surgery Radiology 121 (1976) 295

WIDRICH W C JOHNSON W C ROBBINS A H and NABSETH D C Esophagogastric variceal hemorrhage Arch Surg 113 (1978) 1331

Acta Radiologica Diagnosis 21 (1980) Fasc. 5

FROM THE DEPARTMENTS OF DIAGNOSTIC RADIOLOGY AND UROLOGY, THE NORWEGIAN RADIUM HOSPITAL, OSLO, NORWAY

ANTEGRADE TESTICULAR VEIN PHLEBOGRAPHY AND FUNICULAR LYMPHOGRAPHY IN TESTICULAR TUMORS

H. H. LIEN, A. KOLBENSTVEDT, A. MILLER and S. J. BAKKE

The radiologic diagnosis of retroperitoneal metastases from testicular tumors has been based on the combined use of lymphography, cavography and urography (BAUM et coll. 1963, MAHAFFY 1964, HOPF & FUCHS 1970). Retrograde phlebography of the left renal and testicular veins has also proved useful (LIEN & KOLBENSTVEDT 1976, LIEN 1980).

Funicular lymphography before orchidectomy is a direct method for demonstration of the regional lymph nodes of the testes (BUSCH et coll. 1965, CHIAPPA et coll. 1966, SAYEGH et coll. 1966, WAHLQVIST et coll. 1966, MAHAFFY 1969, HULTÉN et coll. 1973). Most patients with testicular neoplasms referred to this hospital have had their involved testis removed before admission. However, some still have both testes and in these a unilateral funicular lymphography has been performed since 1970.

At funicular lymphography the spermatic cord with the testicular lymphatics and the adjacent testicular veins are exposed. When lymphography has been completed, antegrade phlebography may easily be performed by injecting water soluble contrast medium into a vein of the cord. Because of difficulties associated with the retrograde approach (LIEN & KOLBENSTVEDT 1977, LIEN), antegrade phlebography was introduced in 1974. Previously antegrade testicular vein phlebography had been performed in patients with varicocele (LANE 1955, GOSPODINOW & TOPALOW 1959, MOUCHA 1960, VASSILEV 1962), but no mention has been found of this procedure in cases of tumor of the testis except for a preliminary report based on 5 patients (KOLBENSTVEDT et coll. 1975). The present report considers the value of antegrade testicular vein phlebography and funicular lymphography in the demonstration of metastases from testicular tumors. Normal as well as pathologic phlebographic and lymphographic appearances are described.

Anatomy

The veins of the testis, epididymis and scrotum are composed of a deep and a superficial system (JAVERT & CLARK 1944).

The deep system drains the testis and epididymis and forms the pampiniform plexus which lies in front of the vas deferens in the upper part of the scrotum. At the superficial abdominal ring the plexus terminates in 3 or 4 veins which pass upwards through the inguinal canal within the cremasteric fascia and unite at the deep abdominal ring to form the internal testicular vein, which most commonly terminates in the inferior vena cava on the right side and in the renal vein on the left. A small vein accompanies the ductus deferens and empties into the internal iliac vein via the vesical veins. The external testicular vein drains the cremaster muscle and lies superficial to this muscle in the inguinal canal; it joins the inferior epigastric vein and may communicate with

Submitted for publication 21 November 1979.

the superficial system of veins near the superficial abdominal ring

The superficial system of veins drains the dartos and scrotal skin forming anterior and posterior scrotal veins (AHLBERG et coll 1966) The former most commonly drains into the femoral vein while the latter passes to the external iliac vein

These 2 systems can be profoundly altered by operation for example hernia repair in childhood In accordance with most reports the veins referred to in the following as the testicular veins are identical with the internal testicular veins

Testicular lymphatics 4 to 8 channels accompany the testicular artery and vein and drain into primary regional nodes which are located on the ipsilateral side of the lumbar spine somewhat more distal on the right than on the left side (CHIAPPA et coll) A crossover of testicular lymphatics to the contralateral lumbar nodes also occurs somewhat more frequently from the right side to the left (BUSCH et coll HULTÉN et coll)

Material

During the period January 1974 through December 1978 antegrade testicular vein phlebography was performed in 29 patients who underwent orchidectomy 16 on the right side and 13 on the left Nineteen patients were aged between 20 and 39 years 8 between 40 and 59 and 2 patients were more than 60 years old Twenty-one patients had seminoma and 6 other malignant tumors while 2 had benign lesions

Funicular lymphography was carried out in 26 of these 29 patients

Methods

Under intravenous diazepam propanidid anesthesia *in the operating theatre the urologist injected* 0 5 ml 11 per cent Patent blue violet dye into the testicular parenchyma posteriorly Local anesthetic (Xylocain Exadrin 0 5 per cent) was then injected as for an inguinal hernia operation An oblique incision was made 2 cm above the inguinal ligament The external oblique aponeurosis and the underlying cremasteric fascia containing fibers of the cremaster muscle were divided in the line of incision exposing the spermatic cord surrounded by the thin internal spermatic fascia Within the cord lie the testicular lymphatics and the pampiniform venous plexus Particular attention was paid to hemostasis The wound was covered with sterile towels and the patient allowed to wake up before being transported to the department of diagnostic radiology on the movable operating couch Here under strict aseptic conditions without further anesthesia a funicular lymphography was performed by slow injection (1.5 ml per hour) of 1 5 to 3 ml Lipiodol Ultra Fluid (0 48 g I/ml) Films were exposed in the supine position in a p and lateral projections Next one of the deep veins of the spermatic cord was isolated and a polyethylene catheter inserted A scalp vein set was used in 4 patients thereby obviating the use of a catheter Leakage was prevented by silk ligatures After a test injection under TV fluoroscopy 15 to 20

Table 1

Findings at antegrade testicular vein phlebography and funicular lymphography

Side of examination	Antegrade phlebography			Funicular lymphography		
	Metastases	Normal	Total	Metastases	Normal	Total
Right	5	11	16	4	[illegible]	16
Left	[illegible]	7	13	4	6	[illegible]
Total	11	18	29	8	18	[illegible]

Table 2

Lymphography phlebography and urography in 29 patients with tumor of the testicle

Examination	No of patients with metastases
During operation	
(1) Funicular lymphography (6 cases)	8
(2) Antegrade testicular vein phlebography	11
(3) Combination of (1) and (2)	11
After operation	
(4) Lymphography from the foot	10
(5) Cavography (incl iliac veins)	6
(6) Retrograde left renal and testicular vein phlebography	7
(7) Urography	9
(8) Combination of (4) (5) (6) and (7)	10
Combination of all examinations (1–8)	11



Fig 1 Seminoma of the right testis Normal phlebography Testicular lymphatics visible after funicular lymphography a) A p projection Duplication of the testicular vein Tributary from the lateral abdominal wall at the level of the iliac crest b) Lateral projection Anterior course of the testicular vein



Fig 2 Seminoma of the right testis Normal phlebography a) A p projection b) Lateral projection Posterior curve of the testicular vein before entry into the anterior part of the inferior vena cava

ml Urografin 60 per cent was injected manually and single exposures made in both a p and lateral projections When considered necessary oblique films were obtained In cases with stenosis of the testicular vein serial films were exposed to demonstrate the collateral circulation

When the radiologic examination was completed the couch with the patient was moved back to the operating theatre where orchidectomy was performed after division of the cord at the internal abdominal ring

Except for 2 patients in whom microscopy indicated benign lesions the other routine radiologic examinations (LIEN) were performed after 5 to 7 days

Retroperitoneal surgery allowing microscopic confirmation was performed in 2 cases only Repeat survey films of the abdominal nodes containing contrast medium were exposed in all patients with malignant testicular tumors In one patient the testicular vein was re-examined via the retrograde approach Cavography was abnormal in 6 patients and in 3 of these repeat cavography was performed Phlebography of the left renal vein was abnormal in 7 patients and repeated in 2 and urography was abnormal in 9 patients and repeated in 5 of these

Regression of a mass following treatment or gradual progression in spite of treatment were both considered suggestive of metastases

Complications Extravasation of contrast medium around the testicular veins occurred in 4 patients 2 of these had tumor induced phlebographic abnormalities at a higher level The extravasation caused only slight discomfort No other complications occurred that could be attributed to the radiologic examinations in connection with the operation In particular no postoperative wound infections developed



Fig 3 Seminoma of the right testis Normal phlebography a) A p projection Retrograde filling of the right renal vein The lymph vessels curve medially in the upper part b) Lateral projection Posterior course of the testicular vein which empties into the posterior part of the inferior vena cava The lymph vessels turn forwards before entering nodes situated anteriorly



Fig 4 Benign lesion of the left testis Normal phlebography a) A p projection Duplication of the testicular vein Filling of a vein in the lesser pelvis which is connected with the hemorrhoidal plexus b) Lateral projection The vein in the lesser pelvis runs in a dorsal direction (→) Posterior curve of the upper part of the testicular vein

Results

Antegrade testicular vein phlebography was successfully performed in all 29 patients Metastases were demonstrated in 5 of 16 patients on the right side and in 6 of 13 on the left (Table 1)

Funicular lymphography was successful in all 16 patients on the right side and revealed metastases in 4 of these On the left side it was successfully performed in 10 patients and metastases were demonstrated in 4 It was unsuccessful in 3 patients and 2 of these had metastases demonstrated at antegrade phlebography

The yield of all different examinations in demonstrating metastases is listed in Table 2 Examinations in connection with operation revealed secondary tumor growth in 11 patients while a combination of the different postoperative examinations showed metastases in 10 of these

Normal phlebographic appearances on the right side were found in 11 patients The testicular vein entered the inferior vena cava in 10 patients and joined the junction between the right renal vein and inferior vena cava in one In 6 patients the testicular vein entered the vena cava anteriorly In one of these (Fig 1) the vein had a straight course while in 5 the vein curved posteriorly at the levels of L3 and L4 (Fig 2) The testicular vein had a posterior course with a corresponding posterior entry into the inferior vena cava in 4 patients (Fig 3) In the remaining patient in whom the testicular vein entered the junction between the right renal vein and the inferior vena cava the course was more lateral than usual

Five patients had duplication or triplication of the right testicular vein The only tributary filled was a vein from the lateral abdominal wall (Fig 1) which in 4 cases joined the testicular vein at an acute angle at the level of the iliac crest (Table 3)

On the left side normal phlebography was found in 7 patients The length of the renal vein from the



Fig 5 Seminoma of the left testis a) A p projection Lateral displacement of lymph node with filling defect (↔) The duplicated testicular vein (↔) demonstrates further lateral extent of the tumor Filling of tributaries of the lateral abdominal wall with flow into a capsular vein on the convexity of the kidney emptying into the renal vein via the adrenal vein (⊳→) Filling of a segmental lumbar vein slightly above the iliac crest b) Lateral projection Anterior displacement of upper part of the testicular vein Filling of a collateral vein which runs in a posterior direction in the lesser pelvis (→) c) Retrograde phlebography Injection into the testicular vein Regression of the tumor after radiation therapy indicated by more medial location of lymph nodes and testicular vein A slight displacement of the upper part of the vein remains indicating that the tumor masses have not completely disappeared

entry of the testicular vein to the left margin of the inferior vena cava ranged from 4 5 cm to 7 0 cm (average 5 9 cm) Two patients had a posterior curve of the testicular vein in the upper part (Fig 4) In all 7 patients the testicular vein was duplicated or triplicated The frequency with which tributaries were filled appears in Table 3 A vein in the lesser pelvis was considered to be a communication with a lower branch of the inferior mesenteric vein (Fig 4)

Table 3

Filling of tributary veins in 18 patients without retroperitoneal metastases (right 11–left 7)

Vein	No of patients with filling	
	Right side	Left side
Lateral abdominal wall tributary	4	2
Network near renal hilum	–	1
Internal iliac	–	1
Communication to inferior mesenteric	–	1

Phlebographic findings in patients with metastases Tributary veins were more frequently filled in cases with retroperitoneal tumor growth (Table 4) Duplication or triplication was encountered on the left side in all 6 patients and on the right side in 4 of 5

Displacement occurred in 9 patients always in a ventral direction Seven of these had additional lateral displacement (Figs 5 6) and one medial One patient had ventral displacement only (Fig 7) Impressions occurred in 5 patients and were always associated with displacement Displacement only was found in 4 patients Occlusion existed in 2 patients in one on the right side with collaterals emptying into the superior mesenteric vein (Fig 8) and in the other on the left with collateral circulation through perirenal and lumbar veins

Normal lymphography Nodes situated in the

lumbar regions were in all cases the first lymph nodes to be filled at funicular lymphography

On the right side (11 patients) the lymph vessels followed the course of the testicular vein in the lower part and curved medially in the upper part (Fig 3) However an intermediate loop towards the hilum of the right kidney was observed in 2 patients (Fig 9)

The number of contrast filled nodes ranged from 1 to 12 All patients had nodes in the midline and to the right while 5 patients had nodes on the left side in addition The former nodes were situated anteriorly (Fig 3) and had a slightly more ventral position than those filled at foot lymphography in 2 patients Contrast filled nodes lateral to those demonstrated at lymphography from the foot were not found

On the left side (6 patients) the lymph vessels and the testicular vein had a similar course in all patients except in one in whom the vein was situated more medially than usual

The number of contrast filled nodes ranged from 1 to 12 Two patients had nodes which were situated more laterally than those demonstrated at lymphography from the foot In another patient a lateral node was partially filled at funicular lymphography and well filled at the additional foot lymphography

Lymphographic findings in patients with metastases Obstruction of lymph vessels with collateral circulation and displacement of vessels and nodes were encountered in all 8 patients (Figs 5 6 8) Filling defects were also frequently found (Fig 5)

All patients had displacement in both ventral and lateral directions and the first nodes filled at funicular lymphography were in all cases more lateral than those filled by the pedal route However a still further lateral extent of the tumor was demonstrated at antegrade phlebography in 4 cases (Fig 5) and at urography in one In the remaining 3 patients the most lateral extent was demonstrated by funicular lymphography (Figs 6 8)

Discussion

The results support the view that antegrade testicular vein phlebography is useful in the demonstration of metastases from testicular tumors (KOLBENSTVEDT et coll) It revealed metastases in one patient in whom no abnormality was found at all other examinations (Fig 7) and showed the most lateral extent of the tumor in 4 of the 8 patients with abnormal funicular lymphography as well as in the 2 patients with metastases and technically unsuccessful funicular lymphography



Fig 6 Teratoma of the right testis a) Funicular lymphography Lateral displacement of lymph vessels and nodes Obstruction in the upper part with stretched and irregular collateral b) Antegrade phlebography The testicular vein is displaced but not as laterally as the lymph nodes No filling of tributary veins

Table 4

Filling of tributary veins in 11 patients with retroperitoneal metastases (right 5–left 6)

Vein	No of patients with filling	
	Right side	Left side
Lateral abdominal wall tributary	-	4
Ascending lumbar	1	2
Lumbar	1	3
Renal capsular	2	5
Adrenal	2	3
Ureteric	1	3
Network near renal hilum	2	3
Internal iliac	1	
Communication to superior mesenteric	1	–
Communication to inferior mesenteric	–	-

Funicular lymphography has the advantage tha



a b

ig 7 Embryonal carcinoma of the right testis a) A p projection nplication of the testicular vein below L3 level but no abnor ies visible b) Lateral projection Anterior displacement tive of metastasis at the level of L3 and L4 (→) Surgery firmed the finding All other examinations were normal



Fig 8 Seminoma of the right testis Occlusion of the testicular vein at the level of the iliac crest (→) with runoff of contrast medium into the portal venous system via the superior mesenteric vein Occlusion of lymph vessels in the lumbar region with dis placed tortuous and irregular collaterals demonstrating further extent of the tumor

he contrast medium is retained within the lymph iodes The reduction of the tumor during treatment nay therefore be easily demonstrated in follow-up ilms (Fig 5) However this can also be obtained by ymphography from the foot even though the nodes illed by the pedal route did not demonstrate the ateral extent as well as those filled by the funicular route

Funicular lymphography demonstrated the most lateral extent of the tumor in 3 patients but was difficult to perform and technically unsuccessful in 3 patients It requires a surgical microscope and is onsuming because the oily contrast medium o be injected very slowly to avoid rupture of the lymph vessel Its use in routine work has therefore een questioned (FUCHS 1969) The additional in ormation obtained seems not to justify further use as a routine examination

Antegrade testicular vein phlebography was easy to perform and far less time-consuming The only extra equipment needed is a movable operating couch or facilities for radiography in the operating theatre Thus most hospitals possess the equipment necessary and this procedure should therefore be considered when orchidectomy for malignant tumor is planned

Normal phlebographic findings No mention has been found in the literature about the varying course of the right testicular vein in the lateral view (Figs 1–3) A knowledge of this course is important so that the normal curved appearance is not mistaken for displacement caused by a tumor

A slight posterior curve in the upper part also occurred on the left side in 2 patients (Fig 4) Otherwise medial left testicular veins generally had a more ventral position as compared with the lateral

ones and this coincides with the previous report on the retrograde phlebography (LIEN & KOLBENSTVEDT 1977) In this investigation duplication or triplication was encountered in 33 of the 75 patients in whom retrograde filling exceeded 5 cm while in the present series duplication or triplication existed in all of the 7 normal subjects The vein was duplicated in the entire course in 3 of these and only in the middle and lower part in 4 The different frequencies may be explained by non filling of the lower part of the testicular vein at the retrograde examination

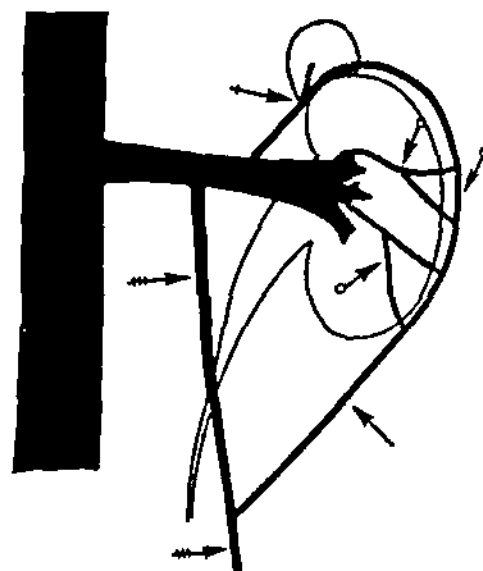
The tributary vein from the lateral abdominal wall which was seen on the right side in 4 patients (Fig 1) and on the left side in 2 was filled also at retrograde examinations (JACOBS 1969 LIEN & KOLBENSTVEDT 1977) being the most frequently filled tributary in the series of LIEN & KOLBENSTVEDT In one patient the left internal iliac vein was filled directly (Table 3) This occurred when the contrast medium at the first attempt was injected into a thin vein of the spermatic cord probably the ductus deferens vein Network near the renal hilum was found in one case on the left side and communications to the inferior mesenteric vein also in one case on the left side (Fig 4)

Phlebographic findings in patients with metastases Ventral and lateral displacement of the testicular vein was the most frequent abnormality as also found at retrograde examination (LIEN)

Tributary veins were frequently filled in cases with lumbar metastatic spread (Table 4) The tributary filling also included veins of the renal capsule the ascending lumbar segmental lumbar adrenal and ureteric veins which were not demonstrated at any of the 18 normal phlebographies Only 2 patients had no tributaries demonstrated (Figs 6 7)

In cases with stenosis of the testicular vein the lateral abdominal wall tributary played an important role in collateral circulation by transporting the contrast medium to the renal capsular veins (Fig 5) The latter empty into the renal vein and also communicate with the adrenal vein which on the right side terminates in the inferior vena cava and on the left side enters the left renal vein most frequently confluent with the inferior phrenic vein (ANSON et coll 1948) The veins mentioned establish a ring on the convex border of the kidney which corresponds to the l arc veineux peri renal reported in autopsy cases by TUFFIER & LEJARS (1891) They held this ring to be constant (Fig 10) and emphasized the


Fig 9 Seminoma of the right testis A p projection Lateral vessel runs in a loop towards the ileum of the right kidney before turning medially and distally


Fig 10 Perirenal venous ring on the left side (after TUFFIER & LEJARS) Lateral abdominal wall tributary (→) gonadal vein (↠) adrenal vein (↔) and renal capsular veins (o→)

potential value of these veins in collateral circulation in renal vein occlusion

The perirenal venous ring on the right side is illustrated in Fig 11 In this case the capsular veins



Fig 11 Demonstration of the perirenal venous ring on the right side Phlebography after injection into a capsular vein Demonstration of the lateral abdominal wall tributary (→) the testicular vein (↠) and the adrenal vein (↔)

and the connections in both directions have been filled by retrograde injection

Drainage from the testicular vein to the ascending lumbar vein via the segmental lumbar veins also took place (Fig 5)

Collateral flow to the superior mesenteric vein occurred in one patient with occlusion of the right testicular vein (Fig 8) In a functional anatomic investigation including both radiography and dissection EDWARDS (1951) found connections to the veins of the posterior abdominal wall to be important porta systemic communications which normally were patent These venous connections were due to the juxta position of visceral and systemic vascular plexuses in the embryo and were most prominent to the derivatives of the subcardinal veins i e the adrenal gonadal and ureteric veins The communicating veins most commonly consisted of multiple fine channels Occasionally connections with diameter 2 to 3 mm were found EDWARDS stated that these veins infrequently possessed valves and therefore could conduct blood in either direction

BRAMWIT & HUMMEL (1969) reported a case with obstruction of the inferior vena cava by a Wilms tumor in which the superior mesenteric vein was filled from the right ovarian vein On the other hand mesenterico gonadal anastomoses with flow in the opposite direction were demonstrated by L HERMINÉ et coll (1972) in 3 patients with cirrhosis of the liver In these cases the right gonadal vein was filled from the mesenteric veins following injection into the coeliac artery The present patient with occlusion of the right testicular vein and collateral flow into the portal system via the superior mesenteric vein had no additional collaterals filled

In 2 patients with narrowing of the upper part of the testicular vein on the left side a vein was filled which ran in a dorsal direction in the lesser pelvis (Fig 5) A similar vein was found in one patient with a normal phlebography (Fig 4) Due to its dorsal course this vein was thought to communicate with the lower branches of the inferior mesenteric vein Thus porta systemic connections between the left testicular vein and the veins draining the lowest part of the gastrointestinal tract also seem to exist This corresponds with the experiences of SPANNER (1940) who at autopsy found communications from the left gonadal vein to the left colic vein and to the upper and lower sigmoid branches of the inferior mesenteric vein

Normal lymphographic findings The normal drainage of the testis to lumbar lymph nodes may be disrupted by inguinal or scrotal surgery (BUSCH et coll) Collaterals may therefore be formed which empty into inguinal or iliac nodes Lymph vessels from the medial part of the testis and epididymis may normally enter the medial external iliac nodes (CUNÉO & MARCILLE 1901) Neither iliac nor inguinal nodes were found in the present series

Different opinions exist regarding to what extent lymph nodes primarily filled at funicular lymphography are filled at a later lymphography from the foot (CHIAPPA et coll SAYEGH et coll HULTÉN et coll) In the present series only 4 of 18 patients had nodes contrast filled at funicular lymphography but not being filled by the pedal route (2 from the right side with anterior nodes and 2 from the left side with nodes situated laterally)

Lymphography in patients with metastases All 8

patients with retroperitoneal tumor growth demonstrated at funicular lymphography had larger metastatic masses which were also demonstrated by phlebography and foot lymphography The particular value of funicular lymphography in detecting early metastases (CHIAPPA et coll) was thus not confirmed

The most frequent indication of metastases was obstruction and displacement of lymphatics with filling of collaterals often appearing as a reticulum of stretched tortuous and irregular lymph vessels (Figs 6 8)

Demonstration of the most lateral extent of the tumor in 3 of a total of 26 cases was the most important additional information obtained at funicular lymphography It appears that this procedure no longer merits a place in the routine examinations of patients with tumor of the testis

Conclusion

Antegrade testicular vein phlebography was easy and quickly performed It demonstrated metastases in one patient in whom all other examinations were normal and showed the most lateral extent of the tumor in most cases *It should be considered when* orchidectomy for malignant tumor of the testis is planned

Funicular lymphography demonstrated the most lateral extent of the metastases in 3 patients but was time consuming and technically difficult It should therefore be discontinued as a routine examination

*Collateral routes in testicular vein stenosis in*cluded a perirenal venous ring (formed by a permanent tributary from the lateral abdominal wall the renal capsular and adrenal veins) the portal venous system and the lumbar and ascending lumbar veins Renal capsular adrenal ureteric lumbar and ascending lumbar veins were not filled in patients *without demonstrated metastases*

SUMMARY

Antegrade phlebography of a testicular vein in connection with orchidectomy was performed in 29 patients and funicular lymphography was successful in 26 of these Eleven patients had retroperitoneal metastases and 18 were normal The phlebographic and lymphographic findings in both groups are described and discussed as well as the collateral pathways in cases with stenosis of the testicular vein Antegrade phlebography is recommended but *funicular lymphography does not merit a place in the* routine examinations of patients with testicular tumor

REFERENCES

AHLBERG N E BARTLEY O CHIDEKEL N and FR JOHSSON Å Phlebography in varicocele scroti Acta radiol Diagnosis 4 (1966) 517

ANSON B J CAULDWELL E W PICK J W and BEATON L E The anatomy of the pararenal system of veins with comments on the renal arteries J Urol (Baltimore) 60 (1948) 714

BAUM S BRON K M WEXLER L and ABRAMS H L Lymphangiography cavography and urography Comparative accuracy in the diagnosis of pelvic and abdominal metastases Radiology 81 (1963) 207

BRASWIT D N and HUMMEL W C The superior and inferior mesenteric veins as collateral channels in inferior vena cava obstruction Radiology 92 (1969) 99

BUSCH F M SAYEGH E S and CHENAULT JR O W *Some uses of lymphangiography in the management of* testicular tumors J Urol (Baltimore) 93 (1965) 490

CHIAPPA S USLENGHI C BONADONNA G MARANO P and RAVASI G Combined testicular and foot lymph*angiography in testicular carcinomas* Surg Gynec Obstet 123 (1966) 10

CUNÉO B et MARCILLE M Topographie des ganglions iliopelviens Bull Soc anat (Paris) 76 (1901) 653

EDWARDS E A Functional anatomy of the porta systemic communications Arch intern Med 88 (1951) 137

FUCHS W A Diagnosis of cancer metastases in lymph nodes *In* Lymphography in cancer Chapter 7 p 101 Edited by W A Fuchs J W Davidson and H W Fischer Springer Verlag Berlin Heidelberg New York 1969

GOSPODINOW G I und TOPALOW J B Phlebographie der Nierenvene auf dem Wege der Vena spermatica sinistra Fortschr Rontgenstr 91 (1959) 664

L HERMINÉ C PARIS J C QUANDALLE P GERARD A DELMOTTE J S DELHAYE J P et PARIS J *Anastomoses porto-caves spontanees mesentérico-*gonadiques au cours des cirrhose A propos de trois observations Ann Radiol 15 (1972) 823

HOPF M A und FUCHS W A Die Lymphographie Cavographie und Urographie als Kombinationsuntersuchung Radiologe 10 (1970) 280

HULTÉN L KINDBLOM L G LINDHAGEN J ROSENCRANTZ M SEEMAN T and WAHLQVIST L Funicular and pedal lymphography in testicular tumors Acta chir scand 139 (1973) 746

JACOBS J B Selective gonadal venography Radiology 9 (1969) 885

JAVERT C T and CLARK R L A combined operation for varicocele and inguinal hernia *A preliminary report* Surg Gynec Obstet 79 (1944) 644

KOLBENSTVEDT A LIEN H H MILLER A and HAVELAND H Antegrade spermatic vein phlebography in *testicular tumors A preliminary report* Radiology 114 (1975) 461

LANE J W Radiographic studies in varicocele U S armed Forces med J 6 (1955) 1589

LIEN H H Lymphography and phlebography followed by urography in metastases from testicular tumors *In*

Phlebography in metastases from testicular tumors A comparison with lymphography and computed tomography Thesis University of Oslo 1980
— and KOLBENSTVEDT A Venography of the left renal and left gonadal veins as a supplement to lymphography Report of four cases Lymphology 9 (1976) 23
— — Phlebographic appearances of the left renal and left testicular veins Acta radiol Diagnosis 18 (1977) 321
MAHAFFY R G A comparison of the diagnostic accuracy of lymphography cavography and pelvic venography Brit J Radiol 37 (1964) 422
— The value of diagnostic lymphography to the surgeon Clin Radiol 20 (1969) 440
MOLCHA D La phlebographie des veines spermatiques Quelques deductions radio-anatomiques et chirurgicales Note preliminaire Presse med 68 (1960) 2094
SAYEGH E BROOKS T SACHER E and BUSCH F Lymph *angiography of the retroperitoneal lymph nodes* through the inguinal route J Urol (Baltimore) 95 (1966) 102
SPANNER R Die Kurzschlusswege zwischen Aorten und Pfortadersystem sowie zwischen Pfortader und Hohlvene Arteriovenose und portocavale Anastomosen in der Bauchhohle des Menschen Zbl inn Med 61 (1940) 633
TUFFIER et LEJARS Les veines de la capsule adipeuse du rein Arch Physiol norm path 23 (1891) 41
VASSILEV I Etude radiographique de la veine spermatique gauche au cours des varicocèles idiopathiques Presse med 70 (1962) 704
WAHLQVIST L HULTÉN L and ROSENCRANTZ M Normal lymphatic drainage of the testis studied by funicular lymphography Acta chir scand 132 (1966) 454

FROM THE DEPARTMENTS OF DIAGNOSTIC RADIOLOGY (DIRECTOR H LODIN) AND LUNG MEDICINE (DIRECTOR G DAHLSTRÖM) AKADEMISKA SJUKHUSET UNIVERSITY HOSPITAL S-751 14 UPPSALA SWEDEN

PULMONARY PSEUDOTUMOURS AND ASBESTOS

G HILLERDAL and A HEMMINGSSON

Exposure to asbestos is a well known cause of pleural lesions With the massive exposure which occurred in the infancy of the asbestos industry extensive pulmonary fibrosis developed and as a rule also extensive pleural fibrosis appearing as adhesions at autopsy The increasing awareness of the dangers of inhaling asbestos dust resulted in protective measures and considerably smaller amounts of inhaled dust It was then realized that late reactions could occur in the pleura one or more decades after exposure to even minor amounts of asbestos The most common of these lesions appear as plaques in the parietal pleura progressing slowly over several decades (BOHLIG & OTTO 1975 HILLERDAL 1978) Other manifestations are diffuse thickening of the parietal and visceral pleura (SOLOMON & WEBSTER 1976) and benign pleurisy and malignant mesothelioma (BECKLAKE 1976) Localized fibrous thickening of the visceral pleura with involvement of the underlying lung parenchyma causing a mass (pseudotumour) does not seem to have been reported previously During the last few years this entity in some cases leading to thoracotomy has appeared at this hospital

Material

Of 10 patients with pseudotumour of the lung 9 were known to have been exposed to asbestos (Table 1) The remaining patient (Case No 4) denied exposure but had been working as a builder The patients were all men with a mean age of 62 years ranging from 46 to 83 2 were smokers and 4 ex smokers The interval between the first exposure to asbestos and the detection of the intrathoracic lesion was long 21 to 70 years with a mean of 37 years Only in one patient (Case No 3) were chest symptoms the reason for radiography of the chest The reasons in the other patients are given in Table 1

Methods

Conventional radiography of the chest was performed in all cases computer tomography with a Delta scanner 50 FS in Cases Nos 3 7 and 8 Bronchoscopy was carried out in 9 of the patients and cytologic examination of the sputum in all 10 Fine needle biopsy was performed in 7 cases Thoracotomy was carried out in 5 patients in one patient who died of myocardial infarction the lesions were observed at autopsy (Table 2)

Results

The rounded mass was located in connection to the basal part of the left upper lobe in 7 patients in 5 of them the lingula In one patient the basal part of the right upper lobe was involved and in 2 cases the right lower lobe In 2 patients the costodiaphragmatic sinus on the same side was obliterated (Fig 1) but in the remaining 8 it was normal Pleural plaques were present in 8 of the 10 patients (Figs 1 2 4) At

Submitted for publication 13 November 1979

Table 1

Case history data

Case No	Occupation	Asbestos exposure (years)	Latency time (years)	Reason for chest radiography	Time from previous radiography not showing pseudotumour
1	Repairman worked with insulation	5	27	Health survey	4 years
2	Builder	34	40	Check up of pleural plaques	4 months
3	Builder	22	27	Chest pain	1 year
4	Builder	Denies exposure	41	Screening because of hypertension	3 years
5	Plumber s assistant mixed dry asbestos powder with water	5	43	Health survey	5 years
6	Factory worker	52	70	Check up for asbestosis	2 years
7	Electric factory worker insulated machines	11	39	Health survey	5 years
8	Electrician used asbestos at times	16	31	Investigation of brain tumour	6 months
9	Radio factory worker in sulation with small asbestos plates	2	21	Check up of pleural plaques	3 years
10	Plumber insulation with asbestos	7	35	Health survey	Not known

Time from first exposure to asbestos until the pseudotumour was first seen
Time from probable exposure (from first year of working in the building trade)

Table 2

Findings at thoracotomy or autopsy

Case No	Pleural adhesions	Parietal pleura	Visceral pleura	Lung parenchyma
1	Almost totally adherent	Thickened	Grossly thickened over lingula	Parts of lingula almost completely atelectatic
2	Small adhesions	Plaques	Thickened over lingula and surroundings	Tip of lingula folded and atelectatic
4	None	Many calcified plaques	Grossly thickened dorso medial part of left upper lobe	Small atelectasis under the plaque
5	Only over apex	Many small plaques	Thickened over border between right upper and right lower lobes	Anterior segment of right upper lobe atelectatic
6	None	Widespread calcified plaques	Thickened esp over left upper lobe medially	Probably atelectatic close to plaque Asbestosis in parenchyma
9	None	Widespread plaques	Lateral part of left upper lobe locally thickened	Partly atelectatic near visceral plaque

bronchoscopy normal conditions were found in all patients Sputum cytology was normal in all but one in whom the findings strongly suggested adenocarcinoma Fine needle biopsy suggested a tumour in 2 cases and a hamartoma in one and was inconclusive in the remaining 7 Computer tomography disclosed the mainly pleural nature of the mass with involvement of the parenchyma (Figs 3b 4d) and also the pleural plaques (Fig 4c d)

The 5 patients who underwent thoracotomy and

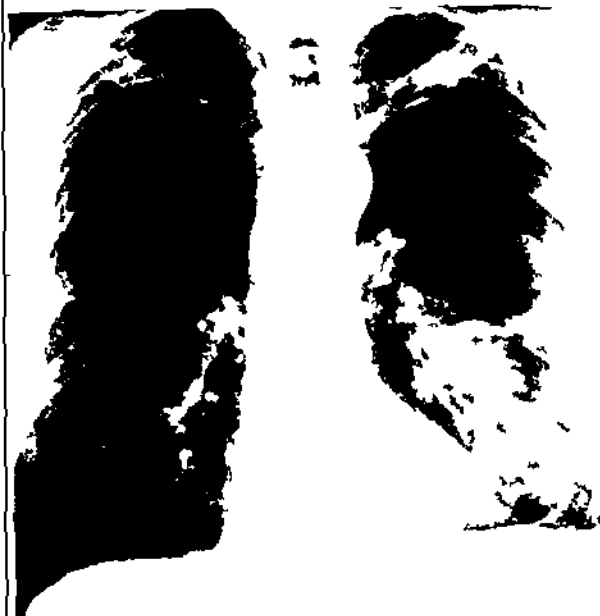


Fig 1a



Fig 1b



Fig 2a



Fig 2b

Fig 1 Small pleural lesions on the right side left sinus obliterated and a mass outside the left hilum

Fig 2 Widespread pleural lesions with calcifications A rounded mass anteriorly at the upper left hilum

the one autopsy case all had thickening of the visceral pleura over the mass and parts of the underlying lung were atelectatic (Table 2) The final pathologic diagnosis in all these cases was unspecific chronic fibrous pleurisy with involvement of the underlying lung parenchyma

Discussion

The patients all had in common an occupational exposure to asbestos with the exception of one (Case No 4) who denied this However being a builder he might well have been exposed without



a



b

Fig 3 A mass on left side No pleural plaques CT The
broadly adherent to pleura anteriorly

knowing it Eight of the patients including the one who denied exposure also had pleural plaques of the type typical of asbestosis Thus asbestos is the most likely agent to have caused the lesions They were located in the visceral pleura with involvement of the underlying lung parenchyma in the 5 thoracotomy patients and the one autopsy case

Exposure to asbestos may cause various pleural manifestations of which parietal pleural plaques diffuse thickening of the parietal and visceral pleura (SOLOMON & WEBSTER) benign exudative pleurisy and diffuse malignant mesothelioma are the best known (BECKLAKE BOHLIG & OTTO) Localized fibrotic lesions of the visceral pleura with involvement of the underlying lung parenchyma causing a pseudotumour should be added to this list as evident in the present cases These lesions can reach a considerable size in a short length of time (e g Cases Nos 2 and 8) in contrast to parietal pleural plaques which typically progress slowly over a number of decades (BOHLIG & OTTO HILLERDAL) They can be difficult to localize at ordinary chest radiography and even at fluoroscopy A malignant tumour is often suggested The diagnosis may be further confused by the results of cytologic examinations as illustrated by Cases Nos 2 5 and 6 due to the fact that mesothelial cells are often very difficult to assess (ELLIS & WOLFF 1977)

Atelectatic pseudotumour of the lung was first described in connection with therapeutic pneumothorax (GALY 1955 ROCHE & ROUSSELIN 1957 HEINE 1967) In 1971 HANKE published a
view of similar pseudotumours occurring in con
tion with exudative pleurisy when part of the lu
parenchyma becomes atelectatic due to the presen
of pleural air or fluid This part then becom
kinked upwards or downwards and adheres to th
pleura which later becomes fixed by fibrosis a
when the lung re expands this part remains atelec
tic A virtually asymptomatic but sometimes qu
large effusion on one side or the other is known
occur in some patients exposed to asbestos (GAEN
LER & KAPLAN 1971 MATTSON 1975) The rath
sudden appearance of the lesions in the prese
cases and the small adhesions around them indica
that they probably represent sequelae of such
pleuritis or an asbestos pleurisy with a small ex
date

The pseudotumours reported in the literature hav
been located mainly in connection to the lower lobe
(BALMÈS & THÉVENET 1956 BÉNARD et coll 197
CHOFFEL et coll 1977 DUROUX et coll 19
FAHDLI & DERRICK 1965 KRETZSCHMAR 19
MAGGI 1969 MONOD & DURET 1946 MONOD 194
OUDET et coll 1956 ROCHE et coll 1965) contrar
to the present patients In most of them the uppe
lobes were involved especially on the left side
MATTSON & RINGQVIST (1970) described a lesion i
the lingula in 8 of 42 patients with pleural plaque
and it seems probable that the lingula is particular
susceptible to these abnormalities

Pleural plaques have previously been mistaken


a


b


c


d

Fig. 4 a) Bilateral pleural plaques b) Six months later A mass medially below the right hilum c) Computer tomography at a level just above the hila Pleural plaques on both sides d) Computer tomography at the level of the mass which is located posteriorly homogeneous broadly adherent to the pleura and with calcification

cases for pulmonary malignancies (GALATIUS-JENSEN & HALKIER 1965 SWEETMAN 1977 TIMIUS 1963) but nowadays such mistakes should occur Asbestos is however a cause of bronchogenic and pleural tumours (BECKLAKE 1976 HLIG & OTTO) and pseudotumours add to this problem With computed tomography which is at present the best method for detecting noduli in the lung (MUHM et coll 1977) it can be determined whether lesions on ordinary chest films are located in the pleura or in the lung (PUGATCH et coll 1978) Pleural plaques are also easily observed with this technique (KREEL 1976 PREGER 1978) If as in case 8 an area of calcification is located within the mass it is very probably benign (AYERS & HUANG 1978) Other possible differential diagnoses are localized mesothelioma and malignant mesothelioma (HUTCHINSON & FRIEDENBERG 1963 RATZER et coll 1967 WANEBO et coll 1976)

Conclusion

In patients exposed to asbestos and with or without pleural plaques who develop a lesion of a possibly tumorous nature the possibility of a pseudotumour should be considered The best method to obtain a certain diagnosis is the use of computer tomography If the lesion is located in or in direct connection with the pleura thoracotomy should be considered only in special cases

SUMMARY

Ten patients are described in whom a localized reaction in the visceral pleura developed comparatively rapidly involving parts of the underlying lung parenchyma forming an atelectatic pseudotumour The lesions were mistaken for pulmonary malignancy leading to thoracotomy in 5 patients It is suggested that these lesions can occur many years after exposure to asbestos and that they are sequelae of benign pleurisy Computer tomography is of great value in these cases and may obviate thoracotomy

REFERENCES

AYERS W R and HUANG H K The use of computerized tomography in the diagnosis of pulmonary nodules Comp Tomogr 2 (1978) 55

BALMES A et THEVENET A Pleuresies enkystees pseudotumorales J Radiol Electrol 37 (1956) 569

BECKLAKE M R State of the art Asbestos related diseases of the lung and other organs Their epidemiology and implications for clinical practice Amer Rev resp Dis 114 (1976) 187

BENARD Y MANDARD J C EVRARD C et LEMÉNAGER J Opacite ronde pseudo tumorale par atelectasie (à propos d une observation) Rev franç Mal Resp 1 (1973) 1171

BOHLIG H und OTTO H Asbest und Mesotheliom Fakten Fragen Umweltprobleme Thieme Verlag Stuttgart 1975

CHOFFEL C VERDOUX P et MILLERON B Les atelectasies rondes pseudo tumorales sans antecedents pleuraux averes (a propos de deux cas) Poumon 23 (1977) 295

DUROUX A MARTY J et JARNIOU P Fausses tumeurs intrathoraciques par pleuresies enkystées J franç Med Chir thor 4 (1950) 405

ELLIS K and WOLFF M Mesotheliomas and secondary tumors of the pleura Semin Roentgenol 12 (1977) 303

FAHDLI H and DERRICK J R Twisted lingula A cause of a solitary pulmonary nodule Ann thorac Surg 1 (1965) 753

GAENSLER E A and KAPLAN A I Asbestos pleural effusion Ann intern Med 74 (1971) 1978

GALATIUS JENSEN F and HALKIER E Radiological aspects of pleural hyalo-serositis Brit J Radiol 38 (1965) 944

GALY P Tumeurs benignes et pseudo-tumeurs inflammatoires pulmonaires et pleurales Documentation anatomo clinique Acta chir belg (1955) Suppl No 2 p 5

HANKE R Rundatelektasen (Kugel und Walzenatelektasen) Ein Beitrag zur Differentialdiagnose intrapulmonaler Rundherde Fortschr Rontgenstr 114 (1971) 164

HEINE F Pneumothoraxatelektasen Ergebn Lun… Tuberk 17 (1967) 1

HILLERDAL G Pleural plaques in a health survey m… al Frequency development and exposure to asbest… Scand J resp Dis 59 (1978) 257

HUTCHINSON W B and FRIEDENBERG M J I… trathoracic mesothelioma Radiology 80 (1963) 9…

KREEL L Computer tomography in the evaluatio… pulmonary asbestosis Preliminary experiences … the EMI general purpose scanner Acta radiol D… nosis 17 (1976) 405

KRETZSCHMAR R Uber atelektatische Pseudotumor… der Lunge Fortschr Rontgenstr 122 (1975) 19

MAGGI N Ombra rotonda del polmone di difficile i… pretazione radiologica ed a rara patogenesi (… Italian) Nunt radiol 35 (1969) 485

MATTSON S B Monosymptomatic exudative pleuris… persons exposed to asbestos dust Scand J resp D… 56 (1975) 263

— and RINGQVIST T Pleural plaques and exposure… asbestos Scand J resp Dis (1970) Suppl No 75

MONOD R Un cas demonstratif de pleuresie contra… simultant un kyste du poumon Poumon 5 (1949) 5

— et DURET M Les pleuresies contractées pseud… tumorales Rev med franç 4 (1946) 58

MUHM J R BROWN L R and CROWE J K Use… computed tomography in the detection of pulmo… nodules Mayo Clin Proc 52 (1977) 345

OUDET P SCHIEL D WAGNER J P HUTT J P … RUEBSAMEN G Pleuresies purulentes torpides enk… tees (formes pseudo-tumorales) J Radiol Electrol … (1956) 385

PREGER L Absbestos related disease Grune & Strat… New York 1978

PUGATCH R D FALING L J ROBINS A H and SNY… G J Differentiation of pleural and pulmonary lesio… using computed tomography J comput Ass Tomog… 2 (1978) 601

RATZER E R POOL J L and MELAMED M R Pleu… mesotheliomas Amer J Roentgenol 99 (1967) 86…

ROCHE G et ROUSSELIN L Opacités pulmonaires mu… ples dues au pneumothorax therapeutique R… Tuberc 21 (1957) 506

— DELANOE Y et GÉNEVRIER R Opacités pseud… tumorales après pleuresies sero-fibrineuses de… grande cavite J franç Med Chir thor 19 (1965) 7…

SOLOMON A and WEBSTER I The visceral pleura in a… bestosis Environ Res 11 (1976) 128

SWEETMAN W R Pleural fibromas masquerading as c… lesions of the lung Amer Surg 43 (1977) 719

TIVENIUS L Benign pleural lesions simulating tumo… Thorax 18 (1963) 39

WANEBO R J MARTINI N MELAMED M R HILARIS … and BEATTIE E J Pleural mesothelioma Cancer … (1976) 2481

ROM THE DEPARTMENT OF DIAGNOSTIC RADIOLOGY AKADEMISKA SJUKHUSET S-750 14 UPPSALA SWEDEN

VIDEODENSITOMETRY AND THERMODILUTION FOR MEASURING LEFT VENTRICULAR FUNCTION

U ERIKSON G HELMIUS K PAVEK and G RUHN

Using videodensitometry it is possible to determine the ejection fraction of the left ventricle meas re its function and if the left ventricular end iastolic volume is known also the stroke volume nd cardiac output (BJÖRK et coll 1974)

As the method is relatively new it seemed of alue to compare it in animal experiments with e well established physiologic method of thermo ilution which has been employed for determining ft ventricular function (KAROVIC & BOSKA 1969 NGHOFF et coll 1970 PAVEK 1974)

Material and Methods

A sheep (male fine wool) weighing 42 kg and 2 eagle dogs weighing 17 5 and 17 1 kg were used

The sheep was premedicated with chloral hydrate 12 g/kg body weight given intravenously Following an intravenous injection of Pentotal in a dose of 01 g/kg body weight it was intubated with a cuffed ndotracheal tube Ventilation was assisted with an Engstrom respirator (O_2 25% N O 75% fluothane about 1%)

The dogs were anaesthetized with Immobilon + Pentobarbital 0 03 g/kg body weight and intubated with a cuffed endotracheal tube Ventilation with air was provided with an Engstrom respirator

The left ventricle was catheterized from the right carotid artery with a red Odman catheter with side holes but no end hole and the distal end of the catheter was shaped like a pig s tail Through the right and left femoral arteries respectively one catheter was inserted into the carotid artery for pressure recording and another was placed in the ascending aorta 1 to 2 cm above the aortic valve The thermistor was inserted through the second catheter and was placed just distal to the tip of the catheter The indicator fluid (0 9% NaCl or Urografin 60%) at room temperature was injected into the left ventricle with an automatic Contrac syringe (Contraves Switzerland) The injections were triggered by the R wave of the ECG for a delayed start and the injection time was adjusted so that the fluid was given during one diastole The ECG and the injection time were registered simultaneously with a Mingograf 82B direct writing recorder (Siemens Elema Sweden) The injection of contrast medium was controlled by fluoroscopy and was registered simultaneously with the ECG and the densitometer curve on an OD X40 video tape recorder (Oude Delft The Netherlands) The thermodilution curve was registered at the same paper speed which permitted direct comparisons between densitometric and thermodilution curves (Fig 1) The videodensitometry was carried out with a Philips videodensitometer (Philips Medical Systems Sweden)

When thermodilution and videodensitometry were performed at the same time contrast medium (Urografin 60%) at room temperature was used as indicator and when thermodilution was performed alone physiologic saline was used instead The amount of indicator substance was 5 to 12 ml and the injection time was less than 0 8 s

Submitted for publication 0 July 1979

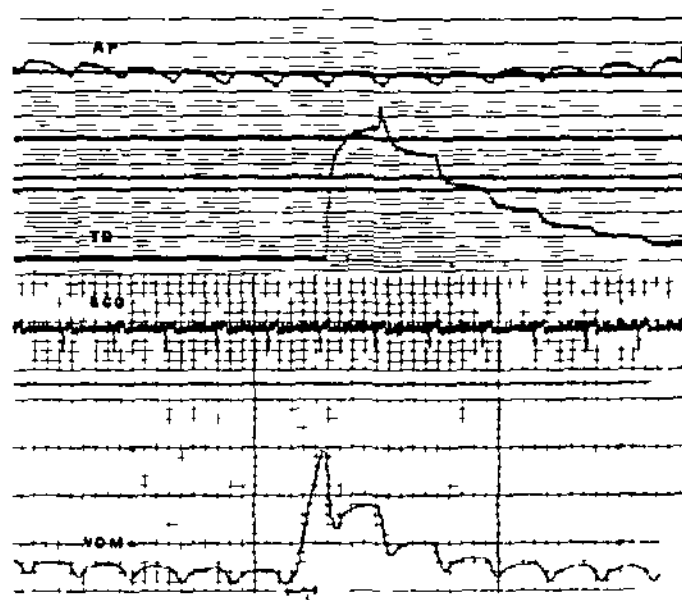


Fig 1 Example of simultaneous thermodilution (TD) video densitometry (VDM) aortic pressure (AP) and ECG recordings in a dog The densitometric measurements were made in the left ventricle and the thermodilution determinations in the aortic arch

Apnoea is an absolute requirement in cardio videodensitometry During all indicator injections—both in thermodilution with physiologic saline and in simultaneous thermodilution and videodensitometry with contrast medium—the respirator was shut off for about 30 s Only exceptionally did the injections cause arrhythmia A catheter position in the left ventricle not producing mitral incompetence was chosen

The thermodilution curves were recorded with an UV writer (Atlas Copco Sweden) simultaneously a thermodilution computer calculated the numerical values for the cardiac output (l/min) The computer had been precalibrated with measurements in a circulation model where the flow was determined volumetrically The ejection fraction was calculated from the successive steps in the thermodilution curve analogously with calculation from the video densitometer curve (ERIKSON et coll 1978)

Procedure The first dog was examined over a period of 30 min During this time the heart rate was 60 to 70 beats per min Eight saline injections followed by 8 injections of contrast medium and finally a further 6 injections of saline were given during the examination period

The second dog was first examined under the influence of anaesthesia alone and 6 injections of physiologic saline and 8 injections of contrast medium were given into the left ventricle After an infusion of 300 ml of Rheomacrodex for increasing the cardiac output further measurements were made

The sheep was examined 3 times with intervals of 30 min The effect of the anaesthesia on the blood gas values was controlled before each examination period PO in arterial blood varied between 9[illegible] and 92 0 mm Hg PCO between 46 8 and 44 0 mm Hg and Ph between 7 42 and 7 49 During each examination period 4 to 7 injections of contrast medium and 5 or 6 saline injections were given

In all 3 animals the amount of indicator substance was varied between 5 and 12 ml in order to obtain optimum recordings with both videodensitometry and thermodilution

The left ventricular end diastolic volume (LVEDV) was determined by the area length method using the formula

$$LVEDV=(8/3\pi)\times(A\ /L)\approx 0\ 85\times(A^2/L)\ ml$$

The area of the left ventricle in diastole (A cm²) was determined planimetrically either from video tape or from cine film recorded under similar conditions A lead square with an area of 16 cm² and a ruler with mm markings were used as references and were reproduced on the film on the same plane as the left ventricle The distance from the aortic valve to the apex (L cm) was measured with the ruler

As the ejection fraction (EF) = the stroke volume (SV)/LVEDV the cardiac output (CO) in ml/min can be calculated from the formula

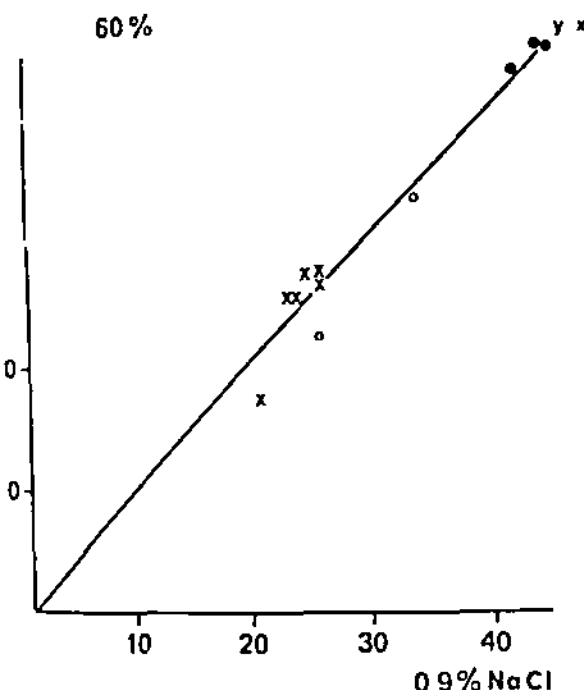
$$CO=LVEDV\times EF\times \text{heart rate}$$

Results

In thermodilution the 2 indicator substances saline and contrast medium were compared with respect to the ejection fraction and cardiac output obtained (Figs 2 3) Mean values obtained from paired injections with the same amount of indicator and at the same injection rate and with a time difference of less than 4 min were compared The 2 indicator substances gave similar measurement results

Determinations of the ejection fraction by means of videodensitometry and thermodilution were compared (Fig 4) A tendency to a somewhat higher value at videodensitometry was found

A similar comparison was made with respect to



ig ? Ejection fractions (per cent) calculated from thermodilution curves with use of Urografin 60% and 0 9% NaCl At each point both substances had the same temperature of 23 C and were injected in the same amount and at the same rate ~sheep ●=dog 1 and O=dog 2

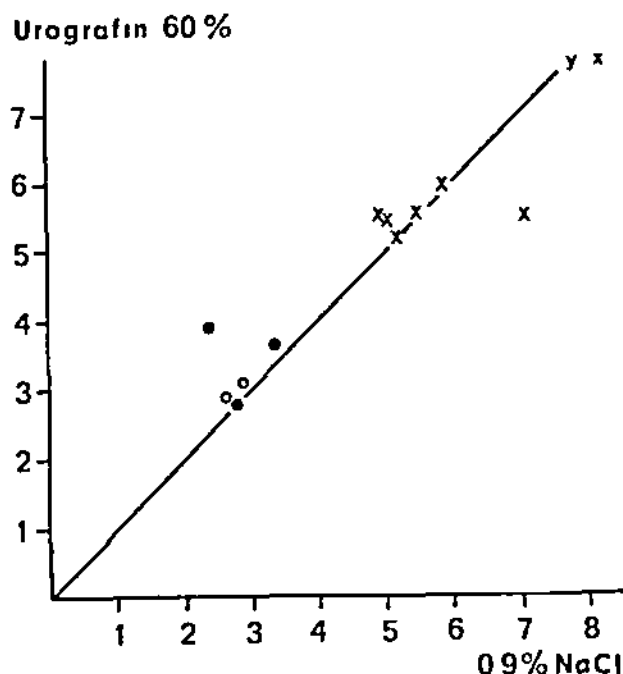


Fig 3 Cardiac output determinations (l/min) under the same conditions as in Fig 2 Symbols as in Fig 2

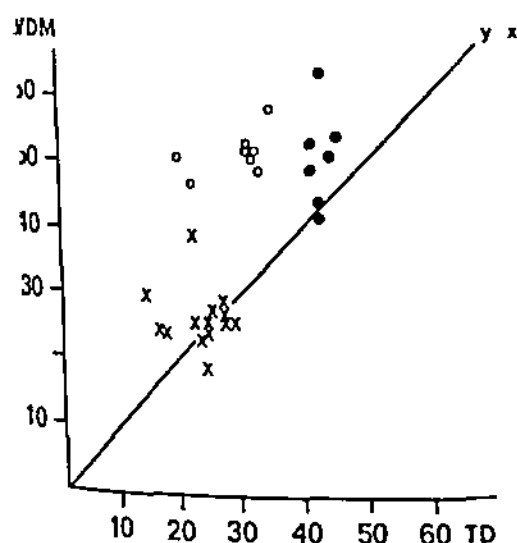


Fig 4 Comparison between ejection fraction (per cent) determined by videodensitometry (VDM) and thermodilution (TD) The determinations were made simultaneously Symbols as in Fig ?

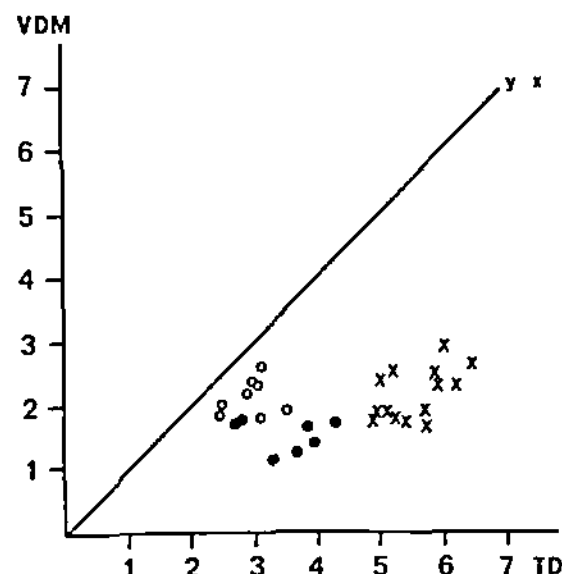


Fig 5 Cardiac output determinations (l/min) under the same conditions as in Fig 4 Symbols as in Fig 2

the cardiac output (Fig 5) Markedly lower values were found at videodensitometry

Using the area length method the left ventricular end-diastolic volume was 75 ml in the sheep 46 ml in the first dog and 55 ml before and 57 ml after the Rheomacrodex infusion in the second dog

Discussion

Radiographic contrast medium and physiologic saline were found to be equivalent as indicator substances in thermodilution measurements The change in cardiac output which could result from the

indicator injection itself was not greater with contrast medium than with saline The increase in cardiac output that is usually ascribed to vasodilatation due to the contrast medium did not affect the present results as this effect did not occur during the recording of the thermodilution curve

The difference between videodensitometry and thermodilution in the calculation of the ejection fraction reflects the fact that the thermodilution curve is flatter in its descending part than the videodensitometry curve The reason for this may be that the videodensitometer measures over the entire ventricle while the thermodilution values are obtained at one single point outside the ventricle

The thermodilution method and the videodensitometry are based upon different assumptions

(1) The videodensitometrically determined ejection fraction is based upon measurement of the step by step decreasing total amount of contrast medium in the left ventricle The video signal is integrated from the entire ventricular surface and is independent of mixing of contrast medium and blood In other words the ejection fraction is a ratio Therefore any consistent error in the measurement of the successively decreasing amount of contrast medium has no effect on the resulting value of the ejection fraction For the same reason no absolute scale in the videodensitometric curve is required

(2) The ejection fraction determined with the thermodilution method is based upon curves obtained at measurement in the ascending aorta This method demands that the ratio between successive steps is representative of (=the same as) the ratio of volume averaged temperature in the left ventricle during consecutive end diastoles In other words the thermodilution method requires that the temperature in the ventricle at end diastole is homogeneous and that the same temperature is measured in the ascending aorta during the following systole In case of incomplete mixing it is assumed that a sample which is representative of volume averaged temperature in the left ventricle during end diastole will arrive at the aorta and will be recorded during the following systole (PAVEK et coll 1970)

A part of the thermodilution indicator can be deposited in a slow exchange compartment of the ventricle and this would result in a flatter and prolonged curve The volume of the ascending aorta with its additional mixing capacity would have the same effect A slowly decaying curve will result in a low ejection fraction

The great difference in the determinations of the cardiac output between the 2 methods is somewhat more difficult to explain The most uncertain step in the videodensitometric determination is the calculation of the left ventricular end diastolic volume However the values obtained with this method seem reasonable in view of the size of the experimental animal and the fact that volume determinations of casts using the area length method indicate that determinations of the end diastolic volume include a source of error of about 10 per cent (LAHDE 1976) The end diastolic volumes obtained in the animals seem to indicate a considerable error in the cardiac output determinations by the thermodilution method A few experiments gave values two or three times higher than the predicted If these values were reasonable this would mean that the end diastolic volume of the left ventricle would be as large as the whole heart Another cause of the error of measurement might be that the measurement point in which the thermistor is located does not give representative values In the thermodilution method the temperature is only measured at one point For example a source of error may be that the receptor is located near the wall of the aorta The videodensitometric method records the indicator over a large area (in this case the projected surface of the left ventricle) and should yield more representative results

SUMMARY

In animal experiments contrast medium and physiologic saline were found to be equivalent as indicator substances in thermodilution The ejection fraction is determined with approximately the same accuracy with thermodilution as with videodensitometry The cardiac output on the other hand is smaller when determined with videodensitometry than with thermodilution The results indicate that thermodilution gives too high values

REFERENCES

BJÖRK L ERIKSON U and HALLSTROM A The video volumeter A new desk top instrument for real time videodensitometric analysis of dynamic contrast agent changes in roentgen images Ups J med Sci 79 (1974) 148

ENGHOFF E MICHAELSSON M PAVEK K and SJÖGREN S A comparison between the thermal dilution method and the direct Fick and the dye dilution methods for cardiac output measurements in man Acta Soc Med upsalien 75 (1970) 157

ikson U Bjork L Cullhed I Enghoff E Nordgren L and Ruhn G Left ventricular function evaluated by videodensitometry in patients with coronary heart disease Acta radiol Diagnosis 19 (1978) 737

ovic K and Boska D Measurement of cardiac output by thermodilution Theoretical considerations and practical aspects Arch Kreisl Forsch 58 (1969) 228

Lahde S Cineangiographic determination of left ventricular volume Accuracy of methods Acta radiol (1976) Suppl No 348

Pavek E Pavek K and Boska D Mixing and observation errors in indicator-dilution studies J appl Physiol 28 (1970) 733

Pavek K Studies on thermodilution technique for determination of cardiac output Acta Univ upsalien (1974) Suppl No 174

OM THE DEPARTMENT OF DIAGNOSTIC RADIOLOGY (DIRECTOR PROF J GOTHLIN) UNIVERSITY OF BERGEN MEDICAL SCHOOL HAUKELAND SYKEHUS N 5016 BERGEN NORWAY

SIZE OF THE SUBARACHNOID SPACE IN STENOSIS OF THE LUMBAR CANAL

J L LARSEN and D SMITH

Stenosing lesions of the lumbar spine giving rise to :urologic symptoms and signs may be divided into categories stenosis of the lumbar spinal canal and enosis of the lateral recesses which can be re irded as synonymous with narrowing the interver bral foramina this is not discussed in the present ommunication

The two types of stenosis may occur independ ntly or in combination but then not necessary at e same level Stenosis of the canal is best dem nstrated in vivo as constriction at myelography hich for this purpose must be performed with the ubarachnoid space distended i e the patient must e in either the sitting or the standing position

Stenosis of the lumbar canal can be present at irth as a congenital malformation it can be de elopmental appearing during childhood and dolescence or it can be acquired The symptoms of he lesion do not usually manifest themselves until dult life Conflicting opinions exist as to whether he acquired forms also have a congenital/develop nental basis or not (for discussion see VERBIEST 1976) The present work was undertaken to find out whether it was possible to establish such a relation ship by myelographic examination of patients with and without demonstrable stenosis of the lumbar canal and to compare the size and form of the subarachnoid space in these patients

Material and Methods

The material consisted of 83 patients referred with symptoms of spinal stenosis low back pain or sci atica They were examined with conventional films of the lumbo sacral spine and with functional lumbar myelography (SORTLAND et coll 1977) According to the myelographic size of the subarachnoid space the patients were classified into 3 groups (1) Antero posterior diameter at any level and in any position <10 mm (2) antero posterior diameter 11 to 14 mm and (3) antero posterior diameter 15 mm or larger

If the subarachnoid space was locally deformed by disc prolapse measurements at that level were not taken into account and the patient was clas sified by measurements at non deformed levels

All the patients in group 1 had symptoms consist ent with those described in spinal stenosis (VERBIEST 1954 SCHATZKER & PENNAL 1968 WILSON et coll 1971 WEDGE et coll 1978) Clinically some patients in group 2 had a possible spinal stenosis while non of the patients in group 3 were referred under that tentative diagnosis

Lumbar myelography was performed with hori zontal beam projection With the patient on a tilt table stretcher films were exposed in several differ ent degrees of rotation including the prone position followed by functional myelography as advised by SORTLAND et coll This consisted of lateral films of the patients sitting in neutral position maximum extension and maximum flexion of the lumbar spine one a p film with the patient erect was also exposed

The contrast medium used was Amipaque 6 75 g

Submitted for publication 14 December 1979



Fig 1 Fig 2a Fig 2b

Fig 1 Man 71 years old Distribution of contrast medium during 1 h in upright position and flexion Almost complete block at the L3/L4 level with only a small amount of contrast medium behind L4 and in the distal part of the subarachnoid space

Fig 2 Two a p films of the same patient a) normal breathing b) during Valsalva s maneuver Greatly diminished transverse diameter of the subarachnoid space and increase in distance between the space and the lumbar pedicles The contrast medium is squeezed cranially by the Valsalva maneuver with better delineation of the upper lumbar space (L4 disc prolapse)

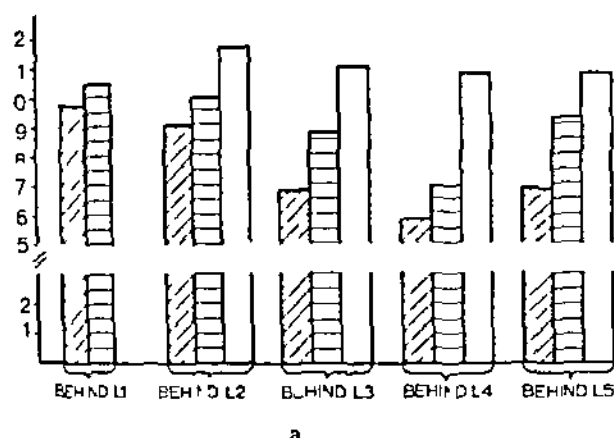
(Nyegaard & Co Norway) In the first part of the series a concentration of 250 mg I/ml was employed corresponding to an injected volume of 13 1 ml As this did not always result in satisfactory demonstration of the upper part of the lumbar canal the concentration was decreased to 200 mg I/ml with an increase of the injected volume to 16 3 ml It was also found advantageous to let the patient make small rotatory movements on the stretcher or to use the Trendelenburg position for a few seconds after the first part of the examination to facilitate mixing of contrast medium and CSF

When a total intraspinal block existed a high lumbar puncture was employed sometimes the patient was kept sitting in ventral flexion for one hour or more after injection of the contrast medium Even this did not always produce filling distal to the block (Fig 1)

The factor of magnification was estimated by measuring a lead marked ruler placed on the patient in a vertical plane parallel to the film and the spine in some patients this measurement was related to the known enlargement at CT and tomography The magnification factor varied around 0 7 for the lateral and 0 8 for the a p projection The size of the patients only caused minor variations

The smallest sagittal diameters were determined at the disc levels and at the middle of the intermediate vertebral bodies The transverse diameter of the subarachnoid space was measured just below the origin of the root sheaths at the narrowest level This level was found to be more appropriate than a fixed level related to the vertebral body which would not take into account variations of the root sheaths These are sometimes high in relation to the vertebral body and longitudinally oriented alternatively they emerge lower with a more transverse direction

The cross sectional image of the subarachnoid space varies from patient to patient and from level to level but will frequently be most narrow posteriorly This may cause difficulty in defining the posterior



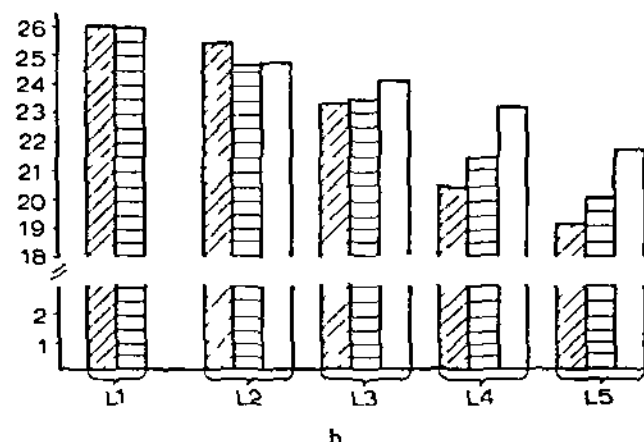


Fig 3 a) Mean sagittal and b) transverse diameters (in mm) of the subarachnoid space taken at intermediate vertebral body height and below the origin of the root sheath respectively in the three groups (1=▨ 2=▤ 3=□)

Table 1

Age and sex distribution of the 83 patients

	Sex		Mean age and range	
	Female	Male	Female	Male
Group 1	8	10	54 0 (?8–73)	54 1 (32–74)
Group 2	9	??	43 5 (18–71)	44 1 (5–70)
Group 3	17	17	4? 9 (0–67)	44 1 (31–6)
Total	34	49		

Table 2

Number of disc levels affected in each of the 18 patients with spinal stenosis (group 1)

	No of levels					Total
	1	2	3	4	5	
L1/L2						1
L2/L3						6
L3/L4	5	3	1	3	1	14
L4/L5	4					12
L5/S1						4
Total	9	4	1	3	1	

outline of the subarachnoid space in the lateral film due to the thin layer of contrast medium in the direction of the beam This difficulty was diminished by keeping the kV between 75 and 85

It was not always possible to make exact measurements in the upper part of the lumbar canal However such patients could not be excluded from the series as this would have given a bias large volume spaces being more difficult to outline

A pertinent problem when making measurements in the lumbo-sacral region and one which is not always given due consideration is the correct determination of vertebral levels A high proportion of patients with symptoms from this region have cranial or caudal lumbar shifts and asymmetries at the lumbo-sacral junction The adequate method to overcome this difficulty would be to count the vertebral segments from C1 however this was used in only a few cases When in doubt the final decision was based upon the topographic relationship of the lowermost lumbar vertebra to the upper limit of the ileosacral articulations

Consideration must also be paid to the breathing of the patient When asked to stop breathing many patients will make a forceful inspiration thereby increasing the intra abdominal and intraspinal pressure with ensuing constriction of the subarachnoid space (Fig 2) This is most obvious in the a p projection but can also be observed on the lateral view it can be avoided by inspecting the respiration and asking the patient to stop breathing at the end of expiration

Results

The sex and age distribution of the patients is given in Table 1 Measurements on the sub arachnoid space are presented in Figs 3 and 6

Sagittal diameter of the lumbar subarachnoid space Generally the sagittal diameters in group 1 were larger than those in group 2 which were in turn larger than those in group 3 This principle held at all levels both at the middle of the vertebral body and at the articular (disc) level (Fig 6) With respect to the mid corporeal diameters the group differences were significant ($p<0.02$) except at L2 between group 1 and group 2 and at L5 between group 2 and group 3 (Table 3)

In group 3 only minor variations of the sagittal diameter existed along the lumbar canal in the two other groups the trend was a decrease from L1 to L4 and then again a larger diameter at L5

Insufficient passage of contrast medium made measurements at L5 impossible in 3 cases and at L4 in 2 cases The measured values for these 2 levels in group 1 are thus to be considered as maxima and would probably have been smaller if determination had been possible in every case

On the other hand the values in group 3 from the upper part of the spinal canal must be regarded as minima The reason for this is that determination was not possible in some cases with a wide sub arachnoid space

In no case in the present series was the sagittal diameter shorter at the mid vertebral level than at the disc levels (i e at the articular segment) Of the 18 patients with stenosis 9 had involvement at one level only and 4 at two levels (Table 2) When adequate measurement was possible in these pa tients the sagittal diameter of the subarachnoid space was never below 14 mm at the mid vertebral level with the patient in maximum flexion

In the 13 patients with stenosis at one or two disc levels only the subarachnoid space was compara tively narrow also at adjacent disc levels in ap proximately 60 per cent of the cases

Transverse diameter of the subarachnoid space In all three groups the transverse diameter gradually diminished towards the distal end of the lumbar sub arachnoid space This was more marked in groups 1 and 2 with no significant difference between them than in group 3 (Fig 3b) Determination of the transverse diameters in the upper part of the lumbar spine was increasingly difficult from group 1 to 3 due to the greater volume of the subarachnoid space



Fig 4 Fig 5

Fig 4 Man 56 years old with tabes dorsalis Severe narr at the L2/L3 level where the a p diameter of the subara space is 7 mm Block at the L3/L4 level Extensive degene lesions

Fig 5 Patient in group 1 The dural sac and subarachnoid follow the bony canal in spite of the stenotic narrowing at disc level

Discussion

Previously SORTLAND et coll have shown the articular segment L3/L4 is the one most c monly affected by lumbar stenosis The present sults indicate that the subarachnoid space in sten and pre stenotic processes tends to be narrowe the a p diameter behind the fourth lumbar b while the diameter behind L3 is the second small

Of necessity any definition of spinal stenosi arbitrary ARNOLDI et coll (1976) used a worl concept Spinal stenosis is any type of narrowin the spinal canal nerve root canals (or tunnels intervertebral foramina It may be local segme or generalised It may be caused by bone or tissue and the narrowing may involve the bony c alone or the dural sac or both The present se deals with stenosis of the spinal canal giving ris symptoms It is difficult to see how such sympto could arise without pressure upon the cauda equ manifesting itself myelographically by demonstra compression of the subarachnoid space It t seems reasonable from the radiologic point of vi to define and categorize canal stenosis accordin the myelographic appearance of the subarachn space

Specific causes for bony constriction such

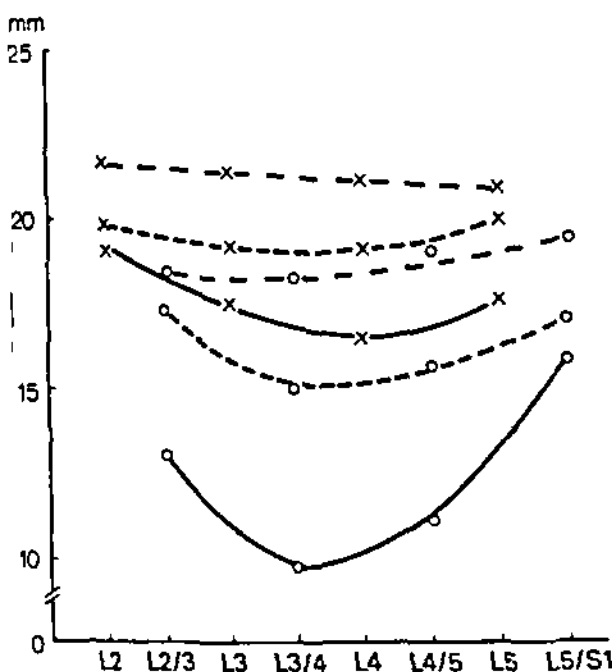


Fig 6 Mean sagittal diameter of the subarachnoid space at mid vertebral level (×) and disc level (O) in the groups 1 (—) 2 ( ) and 3 (– –)

Table 3

Comparison of sagittal diameter of the subarachnoid space behind the vertebral bodies in the different groups Evaluation by t o-tailed Student s t test The levels of significance were reached both by t pooled and by t separate tests

Group 1 < group 2			
	L[illegible]	p=0 470	t=−0 73
	L3	p=0 013	t=−2 67
	L4	p=0 000	t=−4 15
	L5	p=0 009	t=−3 03
Group 1 < group 3			
	L2	p=0 013	t=−2 64
	L3	p=0 000	t=−5 67
	L4	p=0 000	t=−7 79
	L5	p=0 000	t=−3 9[illegible]
Group 2 < group 3			
	L2	p=0 019	t=−2 45
	L3	p=0 001	t=−3 44
	L4	p=0 00	t=−3 23
	L5	p=0 [illegible]67	t=−1 1[illegible]

achondroplasia Paget s disease acromegaly fluorosis or trauma were not present in any of the present patients however one case had tabetic arthropathy (Fig 4)

Extensive measurements on anatomic specimens of the human lumbar vertebral canal have been made by HUIZINGA et coll (1951) SAND (1970) and EISENSTEIN (1976) The a p diameter of the bony canal has been shown to decrease from L1 to L3 with no significant difference between L3 and L4 but an increase in the diameter again at L5 SAND who also measured at the first sacral segment demonstrated a further increase in diameter at that level

The interpedicular distance did not vary significantly between the four upper lumbar vertebrae but increased at the L5 segment (SAND noted further enlargement in this direction also at the S1 level) EISENSTEIN and SAND both found the diameters in males to be 1 to 2 mm larger than in females As the dural sac with the confined subarachnoid space obviously is influenced by its bony surroundings knowledge of these anatomic facts is essential for an understanding of narrow lumbar canal pathology

The present investigation demonstrated no significant difference in size of the subarachnoid space between men and women irrespective of the presence or absence of stenosis Absence of sex related difference in the transverse diameter was also demonstrated in normal spines by DE VILLIERS & BOOYSEN (1976)

However a difference exists between the groups 1 2 and 3 Whatever the underlying cause of stenosis in the individual patient the a p diameter of the subarachnoid space at the intermediate body height demonstrates a tendency towards lower values than in normal control cases This diameter can be considered an indicator of the bony canal with certain limitations These limitations are partly the result of normal anatomic variations and partly of the pathologic processes involved In the upper lumbar spine the distance between the subarachnoid space and the bony canal varies from 1 to 3 mm This narrow space contains loose tissues and blood vessels In the middle of the lumbar spine (MAITROT 1978) or at the level of the fourth vertebral body (SALAMON et coll 1966) the dural sac with the subarachnoid space is sometimes but not always detached from the walls of the bony canal with ensuing variation of the intervening distance This is easily appreciated anteriorly on the lateral view but sometimes the posterior limit formed by the laminar convergence cannot be determined with certainty Nevertheless in a few of the present patients an increased space was obvious posteriorly this was best evaluated by computer tomography

employed in some of the examinations Hypertrophic intervertebral joints narrowed the posterior part of the canal from side to side in such a way that the dural sac and subarachnoid space was forced anteriorly This particular phenomenon was only observed in patients belonging to group 1 On the contrary *in many other cases the anterior limit of the* spinous process made a clearly visible impression in the subarachnoid space from behind when the patient extended It was found impossible to incorporate these variations in the statistical evaluations which must thus be considered with these reservations in mind In the great majority of cases however good correlation between the dural sac and the bony lumbar canal was found (Fig 5)

A characteristic finding in the present series was the decrease of sagittal diameter occurring at the L3 and L4 levels in the stenotic but not in the non stenotic group It thus seems that in groups 1 and 2 the dural sac and subarachnoid space adhere to the configuration of the bony lumbar canal (with its narrowing at the intermediate levels with widening above and below) in group 3 they have a tubular configuration This is the natural form of a thin walled liquid filled container providing minimum tension in its wall The stenosis has also been reported to be most severe in the sagittal direction (MCIVOR & KIRKALDY WILLIS 1976)

Sex distribution at different ages was unremarkable and no difference of age existed between groups 2 and 3 However the patients in group 1 were on the average about ten years older (Table 1) It is natural to regard this as an indication that the more severe forms of stenosis affect the older age groups but are not limited to those as the youngest female in group I was 28 years of age the youngest man 32 years

The best way to assess the role played by congenital/developmental factors versus acquired lesions in the development of spinal stenosis would be an investigation by time where the patients could be followed by radiography over a large span of years With the increasing use of radiologic examination of low back pain and sciatica this should be possible in the future

SUMMARY

Measurements of the subarachnoid space at myelography were carried out in three groups of patients one group with stenosis of the lumbar spinal canal one group without stenosis and one intermediate group Although spinal canal stenosis is most prominent at disc levels the results demonstrate decreased sagittal diameter at mid vertebral body level as well The mean transverse diameters did not differ in the three groups This points towards congenital or developmental factors as the basic abnormality in the majority of patients with stenosis of the lumbar spinal canal

REFERENCES

ARNOLDI C C and 20 co authors Lumbar spinal stenosis and nerve root entrapment syndromes Definition and classification Clin Orthop 115 (1976) 4

DEVILLIERS P D and BOOYSEN E L Fibrous spinal stenosis A report on 850 myelograms with a water soluble contrast medium Clin Orthop 115 (1976) 140

EISENSTEIN S Measurements of the lumbar spinal canal in 2 racial groups Clin Orthop 115 (1976) 42

HUIZINGA J HEIDEN J A v D and VINKEN P J J G The human lumbar vertebral canal A biometric study Proc kon ned Akad Wet Ser C 55 (1951) 22

MAITROT D Some anatomical considerations and clinical data *In* Radiculosaccography with water soluble contrast media Chapter 3 p 29 Edited by P Capesius and E Babin Springer Verlag Berlin Heidelberg New York 1978

MCIVOR G W D and KIRKALDY WILLIS W H Pathological and myelographic changes in the major types of lumbar spinal stenosis Clin Orthop 115 (1976) 42

PENNAL G F and SCHATZKER J Stenosis of the lumbar spinal canal Clin Neurosurg 18 (1971) 86

SALAMON G LOUIS R et GUERINEL G Le fourreau dural lombo sacre Etude radio anatomique Acta radiol Diagnosis 5 (1966) 1107

SAND P G The human lumbo sacral vertebral column An osteometric study Universitetsforlaget Oslo 19[illegible]0

SCHATZKER J and PENNAL G F Spinal stenosis A cause of cauda equina compression J Bone Jt Surg 50B (1968) 606

SORTLAND O MAGNÆS B and HAUGE T Functional myelography with metrizamide in the diagnosis of lumbar spinal stenosis Acta radiol (1977) Suppl No 355 p 42

VERBIEST H A radicular syndrome from developmental narrowing of the lumbar vertebral canal J Bone Jt Surg 36B (1954) 230

— Neurogenic intermittent claudication—lesions of the spinal cord and cauda equina stenosis of the vertebral canal narrowing of the *intervertebral foramina* and entrapment of the peripheral nerves *In* Handbook of clinical neurology Vol 20 p 611 Edited by P J Vinken and C W Bruyn North Holland Publ Co Amsterdam 1976

WEDGE J H KIRKALDY WILLIS W H and KINNARD P Lumbar spinal stenosis *In* Disorders of the lumbar spine p 51 Edited by A J Helfet and D M Gruebel Lee J B Lippincott Philadelphia 1978

WILSON C B EHNI G and GROLIMUS J Neurogenic intermittent claudication Clin Neurosurg 18 (1971) 62

FROM THE DEPARTMENT OF DIAGNOSTIC RADIOLOGY REGIONSJUKHUSET UNIVERSITY OF LINKÖPING
S 58185 LINKÖPING SWEDEN

CAROTID ANGIOGRAPHY OF ARTERIOVENOUS MALFORMATIONS DURING OPERATION

I JOHANSSON and C RÅDBERG

Angiography during operation provides a valuable control method during the course of operations of intracranial aneurysms vascular malformations and arteriovenous fistulas The angiography may alert the surgeon to modify or extend the operation and call attention to a risk of undesirable vascular occlusion Postoperative angiography may often be avoided as may supplementary intracranial operations

The method was described by LOOP & FOLTZ (1966) in connection with 10 vascular operations In 1974 GROSSART & TURNER reported 11 cases of arteriovenous malformation and 38 cases of arterial aneurysm in which angiography during operation had been used without complications The method was also used by BARTAL et coll (1968) VLAHOVITCH et coll (1969) performed angiography during operation in 50 patients with hemispheric tumours By catheterization of small cortical arteries precise topographic information could be obtained which facilitated local intra arterial administration of cytostatic drugs LAZAR et coll (1971) described a technique for retrograde catheterization of the superficial temporal artery with the catheter tip located at the carotid bifurcation

Material and Method

Over the period 1970–77 carotid angiography was performed at this hospital during operations of arterial aneurysms on 75 occasions and of arteriovenous malformation on 18 A radiation protected operation theatre is equipped with a roentgen unit suitable for serial angiography with two AOT film changers and a roentgen tube for a p and lateral projections (JEPPSSON & RÅDBERG 1970 RÅDBERG 1972)

The examinations are performed by radiologists with the assistance of technicians A catheter is introduced via the common carotid artery using image intensifier monitoring The most suitable projection is determined from preoperative films In surgically uncomplicated cases of arteriovenous malformations angiography is performed when all the supplying vessels have evidently been occluded In more difficult cases—usually because of complicated anatomy—angiography has been used as an aid to accurate orientation when only some of the feeding arteries have been occluded

The value of angiography during operation is illustrated in the following 4 cases of arteriovenous malformation

Case reports

Case 1 A girl aged 12 years At preoperative carotid angiography a small arteriovenous malformation was demonstrated (Fig 1 a b) with haematoma in the frontal parasagittal region

At the operation the cavity caused by the haemorrhage had a diameter of about 4 to 5 cm The right lateral ventricle was filled with clots On the floor of the cavity the

---

Submitted for publication 29 August 1979

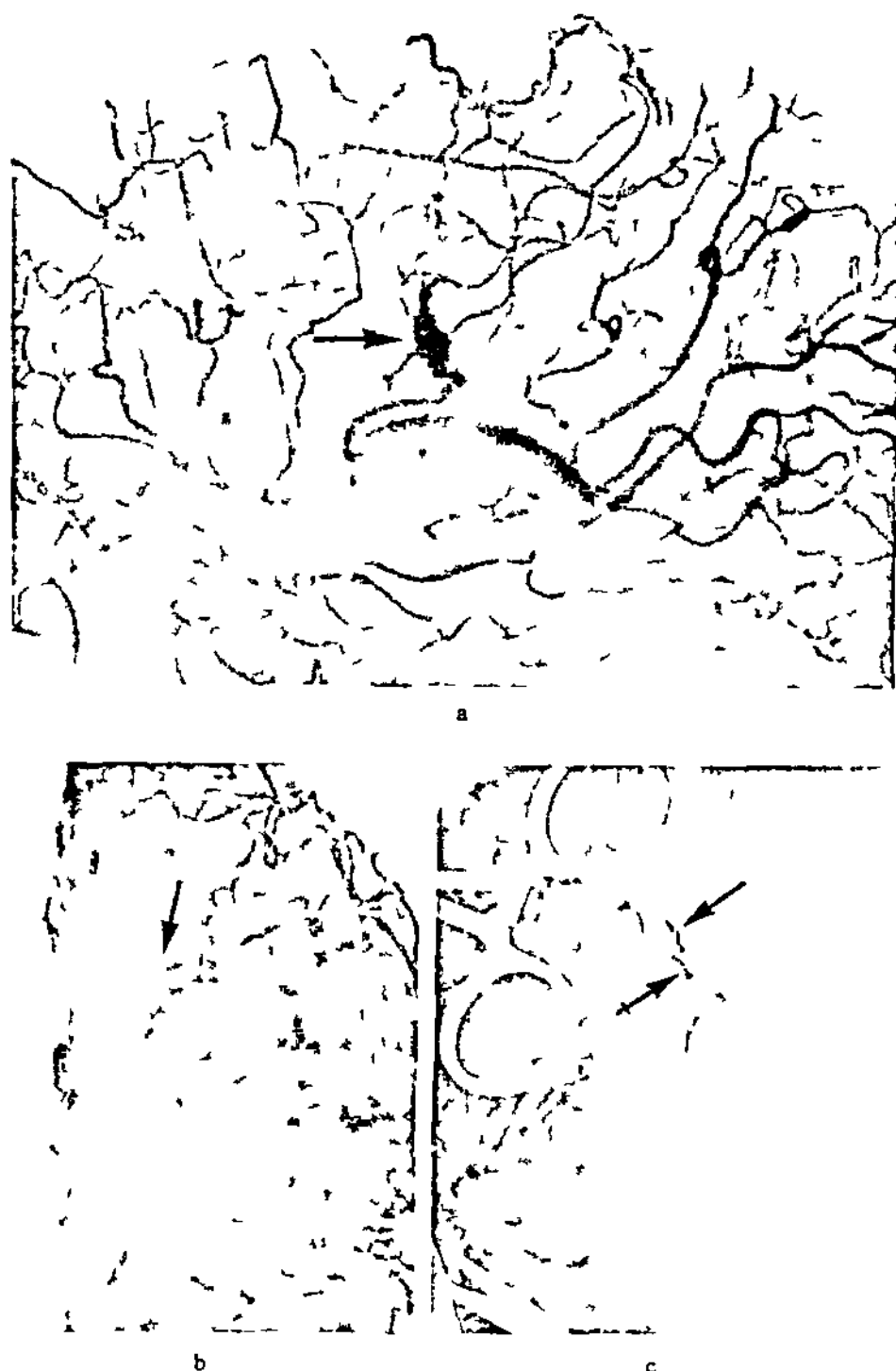


Fig 1 Case 1 a b) Preoperative carotid angiography The arteriovenous malformation (→) is draining into the thalamostriate vein c) Angiography during operation after clamping (→) of the malformation Draining vein (↔) filled with contrast medium indicating residual shunt

malformation was found When the supplying arteries were closed the vascular malformation seemed to collapse draining veins were then ligated At this stage carotid angiography was performed to confirm that the malformation was completely occluded The fact that contrast medium entered the main draining vein indicated the presence of a residual shunt (Fig 1 c) Further dissection centrally revealed 2 more supplying vessels which were ligated A clamp was applied somewhat further centrally on the draining vein and the malformation was excised

Comment With the aim of angiography the operation could be carried out with minimum disturbance of the central venous flow If angiography had not been performed a considerable risk of overlooking a



a



b



c



d

Fig 2 Case 2 a) Preoperative carotid angiography Arteriovenous malformation in or close to the wall of the anterior horn draining to a larger vein (→) running parallel to the pericallosal artery and to a small vein (↔) in the wall of the lateral ventricle b) The malformation (→) c) Angiography during operation after excision of that part of the malformation which apparently had bled The draining vein along the pericallosal arteries no longer filled (slight filling of the pericallosal artery of the non injected side) a malformation is still filled that seems to be more basally located than the one demonstrated pre operatively The draining vein in the wall of the lateral ventricle filled as before (↔) d) Postoperative angiography no malformation or draining vein filled

remnant of the malformation would have existed No further angiography was considered indicated either during or after the operation

Case 2 A man aged 29 years Preoperative right carotid angiography demonstrated a frontal arteriovenous malformation with *central haemorrhage* (Fig 2 a b) At the operation the haematoma was found to reach about 6 cm posteriorly along the wall of the lateral ventricle Anteriorly in the haematoma a vascular malformation was found which was supplied by as many as 7 small branches given off by the pericallosal arteries The arteries and also a draining vein which ran at the level of the pericallosal arteries were occluded The malformation was excised bloodlessly Angiography performed at this stage showed that some abnormal vessels still remained (Fig 2 c) During further exploration with the aid of the films another arteriovenous malformation was demonstrated slightly




Fig 3 Case 3 a b) Preoperative carotid angiography Large arteriovenous malformation fed mainly by the ascending frontal artery c d) First and third of three consecutive angiographies during operation Oblique projection demonstrating the vessels roughly as they were observed during operation In the last fil- (d) three further clamps one of them (→) occluding a large feed- ing vessel posterior to the malformation

more basally This was supplied from a small basal artery and draining through a vein in the wall of the lateral ventricle Nothing indicated that this part of the malformation which was located in the ventricle wall had contributed to the haemorrhage At postoperative angiography a week later no malformation was filled (Fig 2 d)

Comment The part of the malformation that had not contributed to the haemorrhage would probably have been overlooked had angiography not been performed during the operation This part was poorly or not at all filled at the preoperative angiography because the blood containing contrast medium was mainly shunted through the part that had bled

A definitive localisation of the non bleeding part is not possible as only a lateral film was exposed during the operation A comparison with the preoperative films is unreliable due to the operative deformation of the brain but the malformation demonstrated



a



b



c

Fig 4 Case 4 a b) Preoperative carotid angiography (a p projection with compression of the contralateral carotid artery in the neck) Parietal arteriovenous malformation mainly fed by a hypertrophied branch of the middle cerebral artery but probably a narrow branch (→) also contributes c) Angiography during operation after occlusion of the main feeding artery with a clamp (↔) Filling ceases 2 to 3 cm proximal to the clamp The malformation still filled via the narrow branch (→) which now is somewhat dilated due to the increased flow

during operation appears to be located somewhat lower than the one found preoperatively (cf Fig 2a c)

Case 3 A man aged 58 years Right preoperative carotid angiography disclosed the presence of an opercular arteriovenous malformation above the anterior part of the Sylvian fissure (Fig 3a b) with surrounding intracerebral frontal haematoma At the operation 7 feeding arteries were ligated with the guidance of 3 consecutive angiographies during operation After the last one several feeding arteries remained (Fig 3c d) but as the catheter had been in place for some 2 5 hours it was considered advisable to remove it and no final angiography was performed after the malformation had been excised Postoperative angiography 2 weeks later disclosed no remaining vascular malformation

Comment The surgeon considered that the angiographies during the operation had provided a useful guide for performing the operation with minimum trauma No evidence of complications due to the long period that the catheter had been in place was encountered

Case 4 A man aged 49 years Preoperative carotid angiography demonstrated an arteriovenous malformation in the left parietal region The malformation was supplied from a large branch of the middle cerebral artery and probably by a narrow branch partly covered by the former (Fig 4a b) At the operation the large supplying artery was occluded with a tantalum clamp The malformation was still pulsating and carotid angiography was therefore performed (Fig 4c) The filling of the large branch of the

middle cerebral artery ceased 2 to 3 cm proximal to the clamp On the other hand a slightly hypertrophied branch from the middle cerebral artery running towards the anterior part of the malformation was demonstrated This vessel had been only poorly demonstrated at the preoperative angiography It appeared to have increased in calibre since the large branch of the middle cerebral artery had been occluded With the guidance of the films this ramaining feeding artery now more clearly demonstrated was ligated At a second angiography during operation no malformation was found

Comment As was evident at the preoperative angiography the vascular malformation was supplied mainly from the large branch of the middle cerebral artery When the blood flow had been altered by occlusion of this branch a further vascular supply was demonstrated more clearly

Discussion

Angiography during operation is a useful aid in detecting remaining parts of a vascular malformation overlooked during surgical dissection the operation can then be completed at the same sitting The situation at various stages of the operation can be controlled by repeated angiography The surgical trauma may thus be minimized and the measures confined only to the pertinent vessels

In some cases where the feeding arteries vary greatly in calibre the information on the vascular supply provided by the preoperative angiography may be incomplete since the smaller branches will be only poorly or incompletely filled A complete demonstration of the whole vascular malformation with all its supplying vessels can then probably be obtained only by supplementing the preoperative angiography with angiography during operation The latter should be performed after occlusion of the main feeding artery The blood to the malformation will then be redistributed to possible smaller feeding vessels now dilated and more clearly demonstrable The cerebral vessels apparently respond immediately with an increase in calibre upon an increased flow demand

That the extirpation of the vascular malformation has been radical can be controlled by angiography at the end of the operation hereby avoi[ding] a postoperative angiography In those patient[s] whom an angiography was performed during op[era]tion no re-operation for removing remnants of [the] malformation has been necessary No complicat[ions] connected with the actual procedure occurred

SUMMARY

The value of carotid angiography during operation in [the] surgical treatment of arteriovenous malformation is illustrated by 4 patients After obliteration of the main supply to the malformation the blood may be redistributed to possible smaller feeding vessels now dilated and more clearly demonstrable than preoperatively In some cases angiography both preoperatively and during operation may be needed for a demonstration of the whole malformation with all its feeding vessels Angiography during operation reduces the need for postoperative angiography

REFERENCES

BARTAL A D TIROSH M S and WEINSTEIN M Angiographic control during total excision of a cerebral arteriovenous malformation J Neurosurg 29 (1968) 211

DRAKE C G and ALLCOCK J M Postoperative angiography and the slipped clip J Neurosurg 39 (1973) 683

GROSSART K W M and TURNER J W Per-operative angiography in cerebral vascular surgery Clin Radiol 25 (1974) 279

JEPPSSON S and RÅDBERG C Experiences of per-operative cerebral angiography Acta neurol scand 46 (1970) 627

LAZAR M L WATTS C C KILGORE B and CLARK K Cerebral angiography during operation for intracranial aneurysms and arteriovenous malformations J Neurosurg 34 (1971) 706

LOOP J W and FOLTZ E L Applications of angiography during intracranial operation Acta radiol Diagnosis 5 (1966) 363

RÅDBERG C Peroperative Angiographie wahrend neurochirurgischer Eingriffe *In* Angiographie und ihre Fortschritte S 104 Herausgegeben von K E Loose Georg Thieme Stuttgart 1972

VLAHOVITCH B FREREBEAU PH OUAKNINE G BILLET M et GROS CL L angiographie selective peropératoire dans les tumeurs cérébrales hemisphériques Acta radiol Diagnosis 9 (1969) 503

ROM THE DEPARTMENTS OF SURGERY (DIRECTOR L THORÉN) AND RADIATION PHYSICS (DIRECTOR J CEDERLUND) AKADEMISKA SJUKHUSET S 750 14 UPPSALA SWEDEN

SCINTIGRAPHIC ASSESSMENT OF BILIARY REFLUX INTO THE RESIDUAL STOMACH AFTER SUBTOTAL GASTRECTOMY AND GASTROJEJUNOSTOMY

S GUSTAVSSON L K ENANDER B JUNG and M KROG

Regurgitation of duodenal juice containing bile and pancreatic secretions has been reported in association with gastritis and symptoms after gastric , (DU PLESSIS 1962 CAPPER 1967 TOYE & WILLIAMS 1965) Biliary reflux is currently esti mated by endoscopy measurement of bilirubin or C labelled bile acids in gastric aspirates and by radiologic techniques (JAMES & PICKERING 1949 CAPPER et coll 1966 RHODES et coll 1969) These methods imply intubation of the oesophagus and the stomach which is more or less distressing to the patient Moreover it cannot be excluded that the intubation procedure or the mere presence of an e doscope or an intraluminal catheter in itself affects gastrointestinal motility A non invasive method for assessing biliary reflux is thus desirable

LÖHLEIN et coll (1977) introduced a scintigraphic method for determination of biliary reflux with external detection by a gamma camera of intra venously administered ^{99}Tc^{m} HIDA This radio pharmaceutic is rapidly taken up by the liver and is subsequently excreted in the bile A modification of this method is now reported

Material and Methods

The material consisted of 18 patients operated upon with subtotal gastrectomy and antecolic gas trojejunostomy at least 20 years previously In all cases a side to-side entero enteroanastomosis had been added

^{99}Tc^{m} tin colloid (0 4 μg SnCl 0 4 μg ascorbic acid and 2 MBq ^{99}Tc^{m}) in physiologic saline (2 ml) was added to 25 ml gruel and given orally Stannous diethyl IDA complex N (2 6 diethylacetanilido) iminodiacetic acid (Solco-HIDA Solco Nuclear Basle) labelled with 75 MBq ^{99}Tc^{m} in physiologic saline (used for scintigraphic demonstration of the biliary ducts by REICHELT et coll 1977 and PAUWELS et coll 1978) was given intravenously in a dose of 20 mg Toxic reactions or sensibilisation have not been observed after use in more than 10 000 patients (Solco Nuclear Basle 1978)

A gamma camera (Radicamera II General Elec tric) with a Ø 22 cm medium resolution low energy collimator was used

Two regions of interest were selected electroni cally in the image field The analysis was limited by the lack of digital storage and processing equipment for gamma camera images

Determination of biliary reflux No restrictions in food intake preceded the experiment After oral administration of ^{99}Tc^{m} tin colloid the patient was placed on the examination table in supine position with the superior part of the body about 30° above the horizontal plane One of the electronic windows was placed over the image of the gastric remnant the other over the small bowel Proper positioning was documented on Polaroid films

Next ^{99}Tc^{m} Solco HIDA was injected and re

Submitted for publication 8 November 1979

5 10 15 20

30 40 50 60 min

FATTY MEAL

Fig 1 Consecutive gamma camera images in a cholecystectomized patient After a fatty meal increased activity in the small bowel but gastric remnant not demonstrated No scintigraphic evidence of biliary reflux

peated gamma camera images were taken every fifth min for one hour occasionally also later The number of counts collected in the electronic windows were printed out every minute

Between 30 and 40 min after administration of HIDA a fatty meal containing butter and cheese was given orally without change of position of the patient or the gamma camera

Results

In all cases it was possible to define the position of the gastric remnant with the oral $^{99}Tc^{m}$ tin colloid test meal (Fig 5)

After injection of $^{99}Tc^{m}$Solco HIDA a rapid blood phase occurred (Figs 1 3 6) lasting a few minutes In this phase the digital printouts from both electronic windows (Figs 2 4 7) showed a transient increase resulting from activity in the large vessels and in tissues with high blood perfusion

After approximately 5 min activity had accumulated in the liver and after another 5 min the biliary ducts including the gallbladder were demon

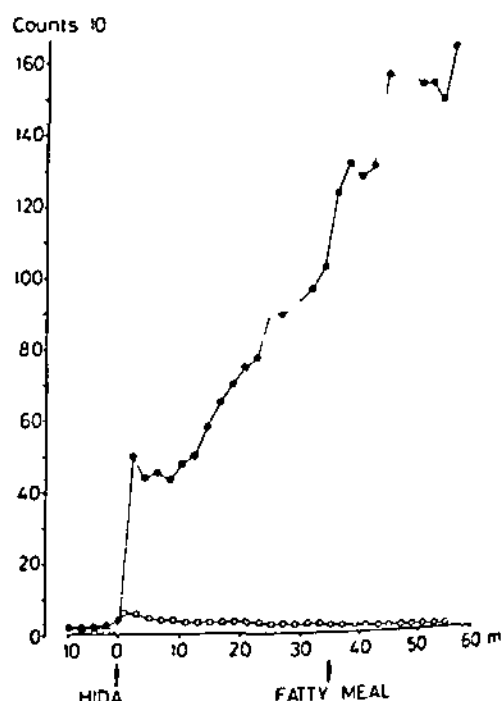


Fig 2 Same patient as in Fig 1 Time activity with steadily declining activity in gastric window (O) in spite of provocation of bile flow with fatty meal increase in number of counts in the small bowel window (●) Initial peaks attributed to blood activity during the first circulatory cycles

5 10 15 20

30 40 50 60 min

FATTY MEAL

ig 3 Biliary reflux after provocation of bile flow with a fatty ieal Gastric remnant appeared about 15 min after fatty meal n the 50 min image

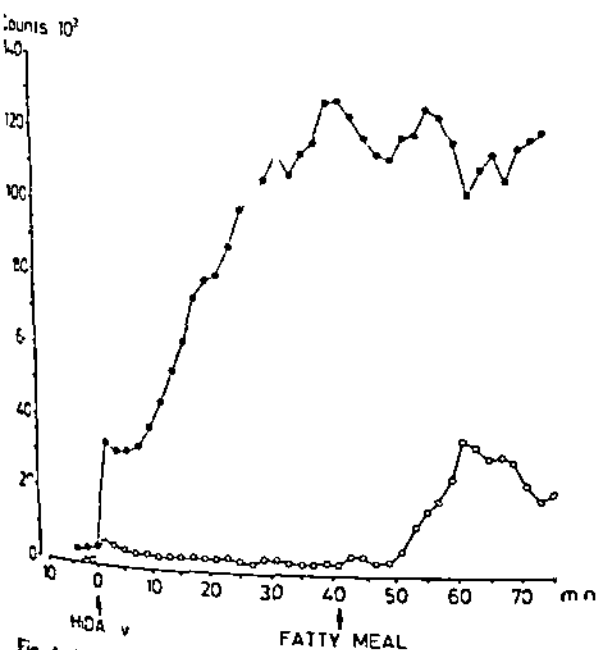


Fig 4 Same patient as in Fig 3 Activity in gastric remnant ( ) and small bowel (●) Increase in gastric activity after fatty meal provocation indicates biliary reflux

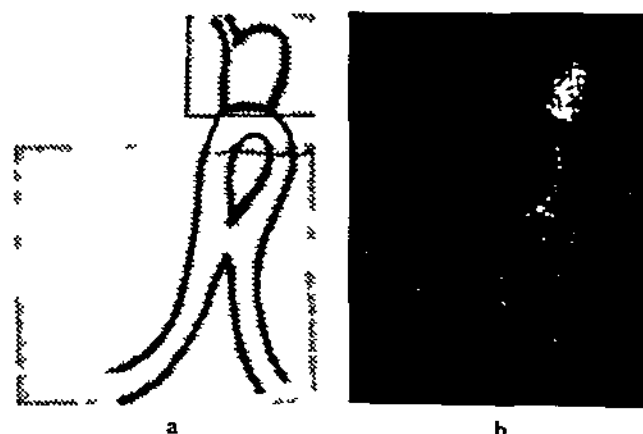


Fig 5 Gastric remnant and adjacent jejunal loops outlined by oral $^{99}Tc^{m}$ tin colloid One electronic window is placed over the gastric remnant one over the small bowel Same patient as in Figs 3 and 4

5 10 15 20

30 40 50 60 min

FATTY MEAL

Fig 6 Cholecystectomized patient Gastric remnant demonstrated already before provocation but after fatty meal considerable increase in gastric activity Scintigraphic evide biliary reflux

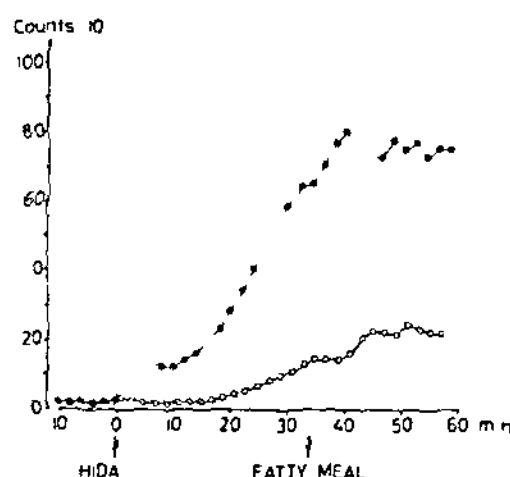


Fig 7 Same patient as in Fig 6 Activity in gastric remnant (O) and small bowel (●) Increase in count rate evident already before fatty meal indicating spontaneous reflux further accentuated after fatty meal

strated The number of counts in the electronic window covering the small bowel window increased (Figs 2 4 7) when the tracer about 15 min after injection appeared in the afferent loop

The presence of biliary reflux was determined as a significant increase in the number of counts registered over the gastric remnant within the image of the residual stomach on the persistence oscil scope of the gamma camera

Provocation of the biliary flow with the fatty m resulted in a strongly accelerated emptying of t biliary ducts and subsequently in an increas *activity in the bowel*

The results were classified in three groups ill strated in Figs 1 to 3 and 4 to 7

The first group (6 patients) had no demonstrat biliary reflux before or after the fatty meal (Figs 1 ?

The second group (9 patients) had biliary ref only after fat provocation (Figs 3–5) This a tm disappeared very slowly

The third group (3 patients) had a spontaneo biliary reflux that was clearly identifiable before t gestion of fat The fatty meal resulted in a furth increase of activity in the gastric remnant The le of activity corresponding to the gastric remnant d not diminish during the recording (1–2 h Figs 6 7)

Discussion

The clinical assessment of patients with symptom after gastric surgery would be facilitated by a no invasive technique for measurement of biliar

reflux The scintigraphic method presented seems to be simple and to provide reliable results Provision of the gamma camera with a computer would have facilitated the settings of the windows and an evaluation of several regions of interest However the mere presence or absence of biliary reflux is the important finding and quantitative estimates should not add significantly to this information

More serious is that at present no indication of the stability of the result is available i e whether a repeat examination of the same patient would give an identical result or not—a problem inevitably inherent in most clinical experimental tests involving ionizing radiation

The sensitivity and specificity of the present test cannot be properly assessed in the absence of a standardized and generally accepted reference technique for evaluation of biliary reflux Only in a large patient material may the method be evaluated in this respect

According to LOHLEIN et coll all patients with gastrojejunostomy have signs of biliary reflux In the present series some patients had no demonstrated reflux neither before nor after fat provocation This discrepancy may be due to different surgical techniques The present patients were all provided with an entero-enteroanastomosis and an antecolic gastro-enteroanastomosis

In order to avoid diversion of all hepatic bile into the gallbladder the present patients were examined in a non fasting state Consequently bile appeared spontaneously in the afferent loop in most patients The presence or absence of spontaneous reflux could then be assessed After provocation by a fatty meal an increased biliary flow was obtained in some patients associated with reflux

It may be concluded that the presented non invasive scintigraphic technique for assessing biliary reflux is simple and specific Further evaluation is needed to settle its role in clinical practice

SUMMARY

A method is described for evaluating biliary reflux into the gastric remnant after subtotal gastrectomy avoiding naso- or orogastric intubation Gamma camera detection and continuous recording of the distribution and possible gastric reflux of $^{99}Tc^{m}$ HIDA after intravenous injection was employed before and after stimulation of bile flow by a fatty meal The technique is simple and specific but further clinical evaluation is needed

REFERENCES

CAPPER W M Factors in the pathogenesis of gastric ulcer Ann roy Coll Surg Engl 40 (1967) 21

— AIRTH G R and KILBY J O A test for pyloric regurgitation Lancet II (1966) 621

DU PLESSIS D J Gastric mucosal changes after operations on the stomach S Afr med J 36 (1962) 471

JAMES A H and PICKERING G W The role of gastric acidity in the pathogenesis of peptic ulcer Clin Sci 8 (1949) 181

LOHLEIN D REICHELT H G HUNDESHAGEN H und PICHLMAYR R Die Anwendung einer neuen Methode zur Bestimmung des duodeno- und jejunogastralen Reflux nach Magenoperationen Chirurg 48 (1977) 588

PAUWELS S STEELS M and PIRET L Clinical evaluation of ^{99m}Tc-diethyl IDA in hepatobiliary disorders J nucl Med 19 (1978) 783

REICHELT H G LANGENBERG G und LÖHLEIN D Hepato-biliare Sequenzszintigraphie in pra und postoperativer Oberbauchs Diagnostik Chirurg 48 (1977) 583

RHODES J BARNADO D E PHILLIPS S F ROVELSTAD S and HOFMANN A F Increased reflux of bile into the stomach in patients with gastric ulcer Gastroenterology 57 (1969) 241

Solco Nuclear Hepato-biliary scintigraphy with $^{99}Tc^{m}$ SOLCO HIDA Solco Nuclear Basle 1978

TOYE D K M and WILLIAMS J A Post gastrectomy bile vomiting Lancet II (1965) 524

Acta Rad olog ca D agnosis ?1 (1980) Fasc 5

FROM THE DEPARTMENT OF DIAGNOSTIC RADIOLOGY AND INTERNAL MEDICINE DIVISION OF RHEUMATOLOGY MALMÖ ALLMANNA SJUKHUS S-71401 MALMÖ SWEDEN

ABNORMAL AXILLARY LYMPH NODES IN RHEUMATOID ARTHRITIS

I ANDERSSON L MARSAL B NILSSON K G SJÖBLOM and F A WOLLHEIM

One of the systemic manifestations of rheumatoid arthritis is lymphadenopathy 50 to 75 per cent of patients having enlarged lymph nodes (BUTLER 1969) At microscopy prominent features are reactive follicular hyperplasia and proliferation of plasma cells (BUTLER)

The finding of abnormal axillary lymph nodes at mammary radiography of a patient without clinical or radiographic evidence of breast carcinoma constitutes a diagnostic difficulty The aim of the present communication is to report the appearance and the frequency of abnormal axillary lymph nodes in a series of patients with rheumatoid arthritis

Material and Methods

The material consisted of 45 patients 40 women and 5 men with classical or definite rheumatoid arthritis according to the ARA criteria (ROPES et coll 1958) Their median age was 60 years (range 26–79 years) The duration of the disease varied between one and 32 years The series also included 4 patients with joint symptoms associated with psoriasis (3 women 1 man) 2 women with systemic lupus erythematosus one woman with scleroderma and 4 women with unspecified arthritis

The 3 standard projections at this institution were used cranio-caudal latero medial and oblique Usually axillary lymph nodes are demonstrated only in the oblique projection (Fig 1) In the males only the oblique projection was used

Normal lymph nodes are usually oval kidney shaped or lobulated with low or moderate attenuation (BJURSTAM 1978 Fig 2) Frequently an area of fatty replacement is observed in the hilum or occupying a larger part of the node (LEBORGNE et coll 1965 BJURSTAM) Small lymph nodes (<10 mm) are frequently rounded without visible fatty replacement The following features were considered to characterize abnormal lymph nodes if present in nodes measuring 10 mm or more high attenuation rounded shape and absence of fatty replacement at least two of the features were required for classifying the node as abnormal

Results

About half of the patients with rheumatoid arthritis had abnormal lymph nodes (Table Fig 3) Abnormal lymph nodes were also found in the patients with psoriasis (Fig 4) lupus erythematosus (Fig 5) and scleroderma

In 10 patients no lymph nodes were found and in 14 normal lymph nodes were demonstrated In the patients with definite abnormal lymph nodes a median of 3 nodes/axilla was demonstrated The corresponding figures for axillae with probably abnormal and normal nodes were 5 and 2 respectively

The single most frequent abnormality was increased attenuation

The largest lymph node exceeded 20 mm in 67 per cent of the axillae with abnormal lymph nodes in 50 per cent of those with probably abnormal and in 4 per cent of the axillae with normal nodes

---

Submitted for publication 30 August 1979




Fig 1 Position of patient for oblique projection

Table

Frequency of abnormal lymph nodes in 56 patients with arthritis Figures within parentheses denote bilateral engagement

No of patients	Diagnosis	Axillary lymph nodes		
		Abnormal	Probably abnormal	Normal or no nodes
45	Rheumatoid arthritis	20 (6)	5 (?)	20
4	Psoriasis + arthritis	1 (1)		3
2	Systemic lupus erythematosus + arthritis	2 (1)		
1	Scleroderma + arthritis	1 (1)		
4	Unspecified arthritis		3 (2)	1
Total 56		24	8	24



Fig 2 Normal axillary lymph nodes

At physical examination which was performed without knowledge of the radiographic result lymph nodes were palpated in 5 of 24 patients with radiographically abnormal nodes and in one of 8 patients with probably abnormal nodes On palpation the nodes were invariably soft

Discussion

Abnormal axillary lymph nodes have not been reported previously but appear to be a frequent finding at mammary radiography of patients with rheumatoid arthritis With the technique used the top of the axilla was not included in the films Furthermore some of the patients had a reduced range of abduction of the shoulder which prohibited optimum positioning for the oblique projection Thus the true frequency of abnormal lymph nodes may have been even higher

In the present series lymph node biopsy was not performed However there was no clinical or laboratory evidence of disease other than the arthritis with 2 exceptions one patient had been operated upon for renal carcinoma 6 months previously and




Fig 3 Abnormal axillary lymph nodes in patients with rheumatoid arthritis The nodes are characterized by a) rounded form b) high attenuation and c) little or no fatty replacement




Fig 4 Abnormal axillary lymph nodes in a man with arthritis associated with psoriasis



Fig 5 Abnormal lymph nodes in a woman with systemic lupus erythematosus

one patient had a clinically occult breast carcinoma None of these 2 patients had abnormal lymph nodes

In the present series the most prominent radiographic features of abnormal lymph nodes were increased attenuation a rounded shape giving the impression of expansion of the node and absence of fatty replacement The same obviously applies to metastatic nodes (LEBORGNE et coll 1963 BJURSTAM) As was pointed out by LEBORGNE et coll the radiographic appearance of the lymph nodes is generally similar whether involved by metastasis or other pathologic processes KALISHER (1975) described a thin irregular pericapsular zone of increased attenuation which he supposed to be characteristic of primary lymphoid hyperplasia and lymphoma This appearance was not observed in the present series

Size cannot per se be used to distinguish between normal and abnormal lymph nodes Nodes measuring 20 to 30 mm in length occasionally occur in healthy patients However such nodes are elongated with moderate attenuation and with a large area of fatty replacement

The practical implications of the present findings are obvious Whether in addition any clinically important correlations with e g severity of disease systemic manifestations or stage of disease can be found remains to be assessed

Conclusion In a patient with rheumatoid arthritis it is highly probable that abnormal axillary lymph nodes represent a manifestation of that disease The present result indicates that the same probably applies to other types of arthritis Thus further diagnostic procedures may be avoided

SUMMARY

Mammary radiography was performed in 56 patients with arthritis predominantly rheumatoid arthritis Definite abnormal axillary lymph nodes were found in 24 and probably abnormal nodes in 8 Abnormal nodes were characterized by increased attenuation rounded shape and absence of fatty replacement

REFERENCES

BURSTAM N G Radiography of the female breast and axilla Acta radiol (1978) Suppl No 357

BUTLER J J Non neoplastic lesions of lymph nodes of man to be differentiated from lymphomas Nat Cancer Inst Monogr 32 (1969) 233

KALISHER L Xeroradiography of axillary lymph node disease Radiology 114 (1975) 67

LEBORGNE R LEBORGNE F JR and LEBORGNE J H Soft tissue radiography of the axilla in cancer of the breast Brit J Radiol 36 (1963) 494

— — — Soft tissue radiography of axillary nodes with fatty infiltration Radiology 84 (1965) 513

ROPES M W BURNETT C A and COBB S Diagnostic criteria for rheumatoid arthritis Bull rheum Dis 9 (1958) 175

ROM THE DEPARTMENTS OF DIAGNOSTIC RADIOLOGY AND OTOLARYNGOLOGY KAROLINSKA SJUKHUSET S 10401 STOCKHOLM SWEDEN

FACIAL BONE SCINTIGRAPHY

VI Practical clinical use in inflammatory disorders of the maxillary sinus

H F BERGSTEDT C CARENFELT and M G LIND

Etiologic diagnosis is a prerequisite for adequate therapy of a sinuitis The sinuitis is either infectious viral or bacterial or non infectious vasomotoric allergic or traumatic By penetrating history and signs a sinuitis with significant bacterial genesis may be distinguished from sinuitis of different origin (CARENFELT et coll 1980) However the different paranasal disorders have many clinical signs in common and further diagnostic measures may be required to decide adequate therapy

Radiography of the nasal sinuses demonstrates the pathologic substitution of air in the sinuses by fluid or soft tissue serous mucous or purulent fluid infectious or non infectious mucosal swelling polypous or neoplastic tissue Severe osteitic reaction or bone destruction are also demonstrable by radiography Radiography detects inflammatory reactions of the sinus with high accuracy but it cannot discriminate the sinuitis of bacterial etiology from the non bacterial form

A significant bacterial infection of the maxillary sinus is characterized by purulence (CARENFELT 1977) Diagnostic aspiration and visual evaluation of the fluid within the sinus is therefore a most reliable method for diagnosing sinuitis of significant bacterial genesis However puncture of the sinus with aspiration is not always performable and a non invasive diagnostic method capable of distinguishing the significant bacterial sinuitis would be a valuable diagnostic adjunct The accumulation of $^{99}Tc^{m}DP$ in bone after intravenous administration has been established as a sensitive indication of malignant engagement as well as osteitic reactions of the bone tissue (SILBERSTEIN et coll 1973 TILDEN et coll 1973 PAPADIMITRIOU et coll 1974 THRALL et coll 1974 GENANT et coll 1974 BELLIVEAU & SPENCER 1975 OSMOND et coll 1975 BERGSTEDT 1975 DE SAULNIERS et coll 1974 KAYE et coll 1975 LETTS et coll 1975 ROSENTHALL & KAYE 1975 WICKENHAUSER & HOLLMANN 1975 GARCIA et coll 1976 LIND & NATHANSON 1977 BERGSTEDT & HAVERLING 1978 WICKENHAUSER 1978) Scintigraphy is also more sensitive than radiography in demonstrating bone tissue engagement by purulent sinuitis (WICKENHAUSER et coll 1978 BERGSTEDT et coll 1979 a) Furthermore in contrast to radiography scintigraphy has the capacity to separate purulent from non purulent maxillary sinus inflammatory lesions (BERGSTEDT et coll 1979 b) In the present report the differential diagnostic capacity of facial bone scintigraphy in practical clinical work concerning inflammatory reaction of the maxillary sinuses will be evaluated

Material and Methods

Fifty-one patients applying for medical treatment of maxillary sinuitis at the out patient department were examined according to a pre set routine during a 6-month period at the ENT clinic at this

Submitted for publication 5 November 1979

hospital Three patients with carcinoma of the ethmoid papilloma durum of the ethmoid and periapical osteitic lesion of an upper premolar tooth were excluded Of the remaining 48 patients 27 were males and 21 females between 17 and 79 years of age The age distribution is presented in Fig 1 No intercurrent disease possibly affecting the skeleton or the paranasal sinuses was present The history and the clinical findings of the patients were carefully explored and registered

Radiography Radiographic examination of the maxillary sinuses was performed in four standard projections occipito frontal occipito mental lateral and axial The radiographic findings were evaluated by a radiologist specialized in ENT radiology without knowledge of the clinical diagnoses The results of the radiographic examinations were classified as follows (1) No affection of the mucosa within the relevant maxillary sinus (2) Mucosal swelling equal to or less than 5 mm thickness (3) Mucosal swelling of more than 5 mm thickness (4) Fluid within or complete filling of the sinus with attenuative material Bony involvement of the facial skeleton could not be distinguished in any of the patients

Scintigraphy Five hours after an intravenous injection of 370 MBq (10 mCi) of Technetium Diphosphonate ($^{99}Tc^{m}$ DP) one a p and two lateral scintigraphic projections were recorded (BERGSTEDT BERGSTEDT & LIND 1978) by a gamma camera (Pho Gamma IV Nuclear Chicago) with a converging collimator on the same day as the radiographic examination The scintigraphic examination results with regard to tracer accumulation to the region of the relevant maxillary sinus were classified (Fig 2) as definitely normal probably normal probably abnormally increased and definitely abnormally increased uptake

Antral aspiration technique The antral content was examined by the antral aspiration technique described by CARENFELT (1980) The occurrence and volume of retained sinus secretion was recorded The character of the secretion purulent or non purulent was determined according to CARENFELT & LUNDBERG (1977) The mucosal thickness the osteal patency and the character of the bony wall were estimated

Classification of patients The patients were classified without considering the radiographic and the scintigraphic results (1) The aspiration findings were used as a basis for classification and the material was divided into A no purulent secretion and D purulent secretion (Table) (2) The patients without purulent secretion at aspiration were further divided into groups—a b and c— according to the evaluation of patient history and clinical signs (Table)

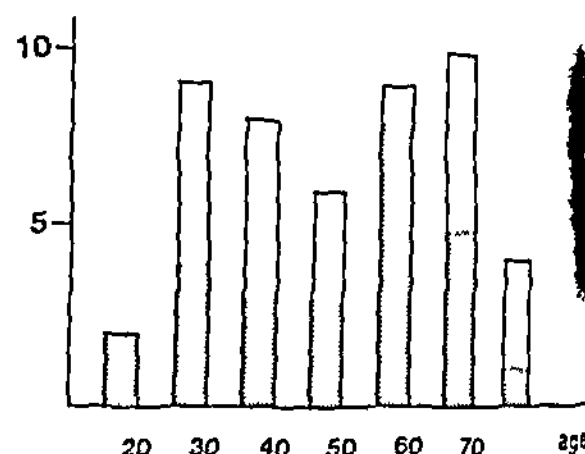


Fig 1 Age and sex distribution of the material 27 males (□) and 21 females (□)

Table

Clinical classification of patients

Group		No of patients		Patient history	Clinical findings
A	a	25	16	NP	NP
	b		8	NP/P	NP/P
	c		1	P	P
D		23			

A=no purulent secretion at aspiration D=purulent secretion at aspiration a=definitely non purulent b=probably non purulent c=probably purulent P=purulent NP=non purulent

If neither aspiration clinical findings nor patient history indicated purulence the sinuitis was classified as definitely non purulent group a If only the patient history or only the clinical findings indicated purulence the sinus affection was classified as group b probably non purulent sinuitis When purulent secretion was found in the nose or in the epipharynx and the patient history indicated purulent secretion as well the sinuitis was classified as group c probably purulent sinuitis By this way of classification the information inherent in clinical evaluation was used in order to differentiate the patients with definitely non purulent sinuitis from those who possibly had had purulent secretion accumulated within the sinus shortly previous to the aspiration



Fig 2 Four patients right maxillary sinus filled with soft tissue or fluid at radiography Scintigraphic classification of these cases a) definitely normal b) probably normal c) probably abnormal d) definitely abnormal

Results

The first classification into A and D based only on findings obtained at aspiration was related to the results of the radiographic examination (Fig 3) as well as to the results of the scintigraphic examination (Fig 4) Findings at scintigraphy correlated better to aspiration results than did the radiographic findings

The second classification a b c and D based both on findings at aspiration and on added clinical information was related to the results of radiographic and scintigraphic examinations respectively (Figs 5 6) The scintigraphic results correlated better also with this classification to aspiration results and to clinical information than did those obtained at radiography Eighteen patients without purulence demonstrated by aspiration had the relevant sinus filled with soft tissue or fluid (10 cases) or a mucosal swelling of more than 5 mm (8 cases) radiographically indicative of maxillary sinuitis Of these 18 patients 13 belonged to group a hence without history or signs of purulent nasal discharge or tenderness of the maxillary sinuses Another 4 patients of these 18 had either a history or signs indicating purulent nasal discharge (group b) but only one of the 18 had both history and signs indicating purulent nasal discharge group c (Fig 5)

Two patients with no pus at aspiration and clinically a probably non purulent sinuitis group b had abnormal scintigraphic findings (Fig 6)

Discussion

Therapeutic considerations in sinuitis are dependent on the etiology of the inflammation Vasomotoric and allergic reactions in the nose and in the paranasal sinuses are treated differently from purulent inflammation The occurrence and the pathogenesis of allergic and viral sinuitis are not well known or defined but mucosal swellings and polyps of the sinus occur frequently in patients with vasomotoric rhinitis These disorders as well as the healing stage following the bacterial sinus affection—possibly representing sterile conditions—should be distinguished from the significant bacterial sinuitis The differential diagnosis is generally based on clinical symptoms and signs and reasonably accurate but in some cases further diagnostic information is desirable especially if surgical intervention is contemplated

A strong correlation exists between the occurrence of purulent sinus secretion and significant growth of pathogenic bacteria (CARENFELT & LUNDBERG 1978 CARENFELT 1980) In acute maxillary sinuitis pathogenic bacteria are found in 90 per cent of purulent secretions (CARENFELT 1979) In chronic maxillary sinuitis bacterial growth in purulent secretion was reported in 88 per cent heavy growth in 72 per cent of cases by KARMA et coll (1979)

Radiography offers information about the distribution of air soft tissue and fluid within the paranasal sinuses but the findings are non specific and it is not possible by means of radiography to separate purulent from non purulent inflammation Bone reactions are demonstrated if extensive enough but early osteitic reactions are not radiographically demonstrable (BERGSTEDT & LIND)

Facial bone scintigraphy is a more sensitive *method than is radiography in detecting early bone* reaction of a paranasal sinus harbouring a purulent inflammation (BERGSTEDT & LIND WICKENHAUSER et coll) It has also been demonstrated that this sensitivity to purulent engagement of bone tissue can be used to distinguish patients with non purulent sinuitis from those with purulent sinus in

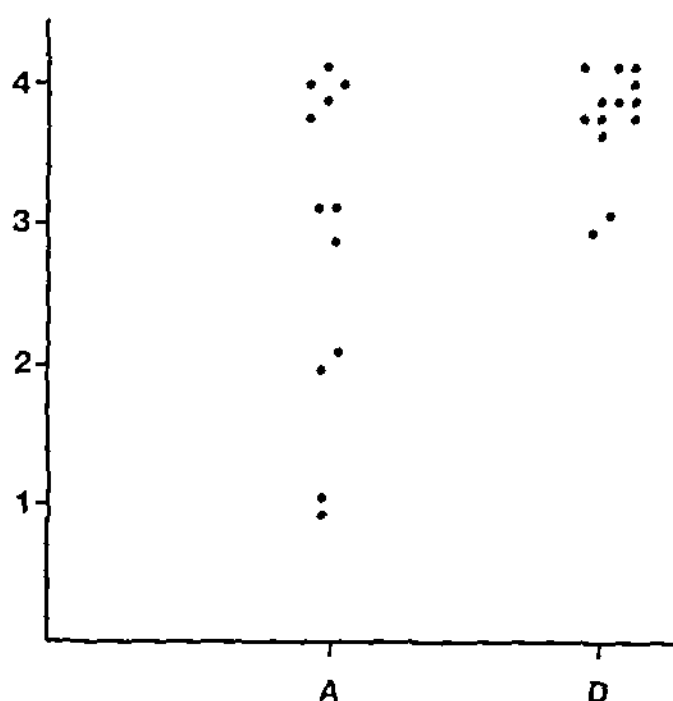


Fig 3 Results of antral aspiration (A=no pus D=pus) related to results of the radiographic examination 1=no mucosal affection 2=mucosal swelling equal to or less than 5 mm 3=mucosal swelling of more than 5 mm 4=fluid within or complete filling of the sinus with attenuative material

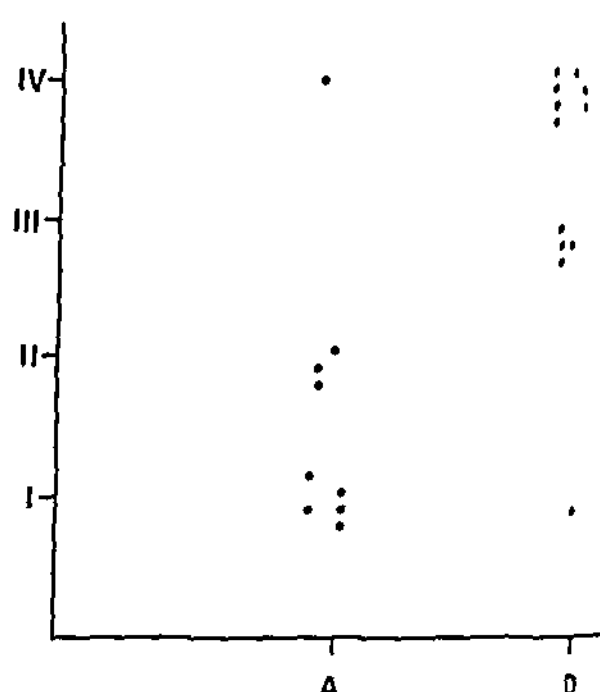


Fig 4 Results of antral aspiration (A=no pus D=pus) related to results of scintigraphic examination I=definitely normal II=probably normal III=probably abnormal IV=definitely abnormal

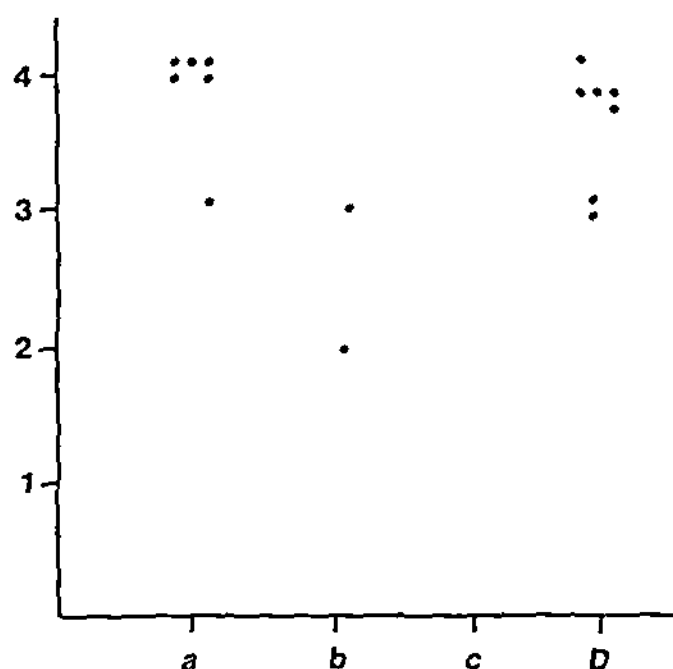


Fig 5 Results of clinical examination and antral aspiration (a=definitely non purulent b=probably non purulent c=probably purulent D=purulent secretion) related to results of radio graphic examination (1–4 as in Fig 3)

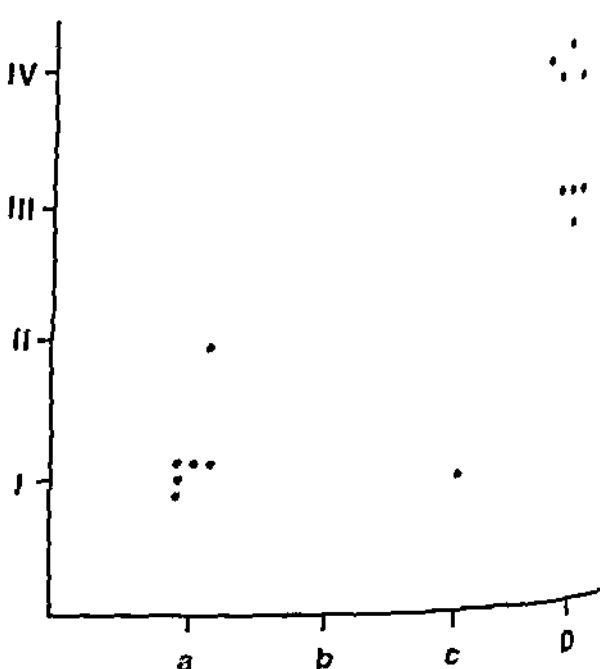


Fig 6 Results of clinical examination and antral aspiration (a b c D as in Fig 5) related to results of scintigraphic examination (I–IV as in Fig 4)

flammation (BERGSTEDT & LIND) The results reported indicated that a strong correlation exists between scintigraphic results and antral purulence However this high sensitivity and differential diagnostic capacity of bone scintigraphy was demonstrated in a series of selected patients Therefore the practical clinical value of facial bone scintigraphy in the diagnosis of inflammatory reactions in the paranasal sinuses remains to be demonstrated

The present series consisted of patients in routine

linical work with equivocal signs of maxillary sinus affection The scintigraphic findings correlated better to antral purulence as evidenced by findings at aspiration than did the radiographic findings Radiography of the maxillary sinuses cannot differentiate purulent secretion from non purulent secretion nor mucosal swellings caused by bacterial infections from those of non bacterial etiology As a consequence both non purulent and purulent maxillary affections are included in the group of patients with radiographic signs of maxillary sinuitis

Further information obtained from clinical history and signs might reveal a previous purulent infection not detectable by the aspiration technique at the time of the examination However in the present series the clinical history and signs were not indicative of such previous purulence On the contrary of 8 patients with no pus demonstrated at aspiration but with radiographic indication of maxillary sinuitis 3 had neither clinical history nor signs indicative of purulence It has also been reported that bone reaction may not be demonstrable by scintigraphy during the first days of an acute bacterial sinuitis Also an additional purulence to an originally non purulent sinuitis may be undetected at scintigraphy for some time because of the delay of bone reaction (BERGSTEDT & LIND) On the other hand a bone reaction causing abnormal scintigraphy may persist even after the period of active purulent engagement

Facial bone scintigraphy is more time consuming than conventional radiography and does not offer comparable anatomic information Radiography is indicated when symptoms and signs are not sufficient for clinical management and when aspiration is not performable Some patients still offer diagnostic difficulties such as patients with allergic nasal polyposis bronchial asthma and possible residual purulent paranasal infections In general vasomotoric or allergic reactions do not indicate radical surgery of the maxillary sinuses but residual or chronic purulent infections sometimes do in order to exclude the infectious focus possibly aggravating bronchial asthmatic reactions In such patients the combination of radiography and facial bone scintigraphy offers diagnostic information beyond radiography alone still by non invasive methods

Normal radiographic findings do not exclude bone tissue reaction as effectively as does scintigraphy Scintigraphy is therefore of special value when inflammatory or neoplastic bone tissue engagement should be excluded

Conclusions Facial bone scintigraphy correlates better to maxillary sinus purulence than does radiography Scintigraphy is more sensitive in detecting the bone tissue reaction around purulent sinus inflammations than is radiography Bone tissue reaction is almost mandatory for the diagnosis of purulent maxillary inflammation

SUMMARY

Facial bone scintigraphy with $^{99}Tc^{m}$ DP was compared with radiographic examination of the maxillary sinuses in a clinical routine series of patients considered to have inflammatory disorders of the maxillary sinus Scintigraphy correlated better to the presence of purulent inflammatory lesion than did radiography Bone tissue reaction is almost mandatory for the diagnosis of purulent maxillary inflammatory disorder

REFERENCES

BELLIVEAU R E and SPENCER R P Incidence and sites of bone lesions detected by ^{99m}Tc polyphosphate scans in patients with tumors Cancer 36 (1975) 359

BERGSTEDT H F Bone scintigraphy of facial skeleton with $^{99}Tc^{m}$ Diphosphonate Acta radiol Diagnosis 16 (1975) 337

— and HAVERLING M Facial bone scintigraphy I Metastatic lesions in the mandible Acta radiol Diagnosis 19 (1978) 859

— and LIND M G Facial bone scintigraphy II Diagnostic potential in neoplastic and inflammatory lesions Acta radiol Diagnosis 19 (1978) 993

— CARENFELT C and LIND M G (a) Facial bone scintigraphy IV Diagnosis of bone involvement by purulent sinuitis Acta radiol Diagnosis 20 (1979) 379

— — — (b) Facial bone scintigraphy V Differentiation of purulent from non purulent inflammation of the maxillary sinus Acta radiol Diagnosis 20 (1979) 458

CARENFELT C Maxillary sinusitis Studies on antral gas environment local immunity and effects of treatment Thesis Stockholm 1977

— Pathogenesis of sinus empyema Ann Otol 88 (1979) 16

— Diagnostic antral aspiration To be published in Acta oto-laryng (1980)

— and LUNDBERG C Purulent and non purulent maxillary sinus secretions with respect to pO pCO and pH Acta oto-laryng 84 (1977) 138

— — The role of local gas composition in pathogenesis of maxillary sinus empyema Acta oto-laryng 85 (1978) 116

— — BERGSTEDT H LIND M G and PEROLS O The discrimination of purulent from non purulent maxillary sinusitis To be published in Ann Otol (1980)

DESAULNIERS M FUKS A HAWKINS D LACORCIERE Y and ROSENTHALL L Radiotechnetium polyphosphate joint imaging J nucl Med 15 (1974) 417

GARCIA D A TOW D E KAPUR K K and WELLS H Relative accretion of ^{99m}Tc polophosphate by forming and resorbing bone systems in rats Its significance in the pathologic basis of bone scanning J nucl Med 17 (1976) 93

GENANT H K BAUTOVICH G J SINGH M LATHROP K A and HARPER P V Bone seeking radionuclides An in vivo study of factors affecting skelettal uptake Radiology 113 (1974) 373

KARMA P JOKIPII L SIPILA P ZUOTONEN J and JOKIPII A Bacteria in chronic maxillary sinusitis Arch oto laryng 105 (1979) 386

KAYE M SILVERTON S and ROSENTHALL L Technetium 99m pyrophosphate Studies in vivo and in vitro J nucl Med 16 (1975) 40

LETTS R M AFIFI A and SUTHERLAND J B Technetium bone scanning as an aid in the diagnosis of atypical acute osteomyelitis in children Surg Gynec Obstet 140 (1975) 899

LIND M G and NATHANSON A ^{99}Tc^{m} DP accumulation in rabbit skull bones after ^{60}Co gamma irradiation Acta radiol Ther Phys Biol 16 (1977) 489

OSMOND J D PENDEGRASS H P and POTSAID M S Accuracy of ^{99m}Tc diphosphonate bone scans and roentgenograms in the detection of prostate breast and lung carcinoma metastases Amer J Roentgenol 125 (1975) 972

PAPADIMITRIOU J VEZERIDIS M CONSTANTINIDIS M CHIOTELIS E CONSTANTINIDIS C and TOUNTAS C The value of Tc^{99m} diphosphonate (HEDSPA) as a skeletal scanning agent Amer J Roentgenol 1[illegible] (1974) 735

ROSENTHALL L and KAYE M Technetium 99m pyrophosphate kinetics and imaging in metabolic bone disease J nucl Med 16 (1975) 33

SILBERSTEIN E B SAENGER E L TOFE A J ALEXANDER JR G W and PARK H M Imaging of bone metastases with ^{99m}Tc Sn EHDP (diphosphonate) [illegible]F and skeletal radiography Radiology 107 (1973) 551

THRALL J H GHAED N GESLIEN G E PINSKY S M and JOHNSON M C Pitfalls in Tc^{99m} polyphosphate skeletal imaging Amer J Roentgenol 1[illegible] (1974) 739

TILDEN R L JACKSON JR J ENNEKING W F DELAND F H and MCVEY J T ^{99m}Tc polyphosphate Histological localization in human femurs by autoradiography J nucl Med 14 (1973) 576

WICKENHAUSER J Die kombinierte rontgenologische nuklearmedizinische Skelettdiagnostik mit besonderer Berucksichtigung des Schadels Wien klin Wschr 90 (1978) Suppl No 95

— und HOLLMANN K Nuklearmedizinische Untersuchungen der Gesichtsschadelregion und ihr differentialdiagnostischer Aussagewert Rontgen Bl 28 (1975) [illegible]

— BRUNNER W und SCHMIEDL R Szintigraphische Untersuchungen bei entzundlichen Nasennebenhohlenerkrankungen Laryng Rhinol 57 (1978) 6?7

FROM THE DEPARTEMENTS OF DIAGNOSTIC RADIOLOGY (DIRECTOR PROF H LODIN) AND ORTHOPEDIC SURGERY (DIRECTOR PROF T HIERTON) AKADEMISKA SJUKHUSET S 750 14 UPPSALA SWEDEN

RADIOGRAPHIC INVESTIGATION OF POPLITEAL CYSTS

P G LINDGREN and W RAUSCHNING

A swelling in the popliteal region in association with effusion in the knee joint was described by DUPUYTREN (1829) and later by ADAMS (1840) ADAMS considered that the swelling was due to an enlargement of the bursa which lies beneath the medial head of the gastrocnemius muscle Furthermore he stated that the bursa communicated with the knee joint by a species of valvular opening BAKER (1877) reported 8 cases of popliteal swelling It was his opinion that this condition arose through herniation of synovial membrane from the knee joint Later (1885) he believed that the popliteal swelling might be caused by distension of a normally occurring bursa In reports of large series of arthrographies cystic popliteal cavities communicating with the knee joint have been described (FICAT 1957 KESSLER & SILBERMAN 1960 DOPPMAN 1965 BRYAN et coll 1967 PALLARDY et coll 1971 REINHARDT 1972 WOLFE & COLOFF 1972) Various names have been given to these cavities for example ganglion hygroma hernia and Baker s cyst In the orthopaedic literature it is often claimed that Baker s cysts communicate with the joint through a narrow pedicle stalk or curved narrow passage which is assumed to constitute the neck of a hernial sac

LINDGREN (1978) demonstrated that communicating popliteal cavities detected accidentally at routine arthrography without exception consisted of the gastrocnemio-semimembranosus bursa and that the frequency of communication of this bursa with the joint increased with age He also clarified the radiographic morphology of these bursae

Several authors have postulated that in all cases of communication between the knee joint and the bursa a valve mechanism is invariably present (ADAMS TAYLOR & RANA 1973)

However pressure measurements and cineradiography have revealed that in the normal communicating gastrocnemio semimembranosus bursa no such mechanism exists and that the passage is hermetically closed when the knee is extended (LINDGREN) This closure mechanism has been examined in detail by serial cryosectioning of fluid filled knee joint specimens frozen at different degrees of flexion (RAUSCHNING 1979a) In some cases of symptomatic popliteal cysts LINDGREN demonstrated that a valve mechanism with total obstruction of fluid flow from the cyst to the joint cavity was unequivocally present

Clinically popliteal cysts besides causing local swelling and tenderness may simulate deep venous thrombosis either due to the size of the cyst which may extend down into the calf or due to rupture of its wall with effusion of synovial fluid Rupture of a popliteal cyst in patients with rheumatoid arthritis often gives rise to fulminant symptoms simulating thrombosis (DIXON & GRANT 1964 GOOD 1964 HALL & SCOTT 1966 JAYSON et coll 1969 HOOPER & BROOKLER 1971 BACON & GERBER 1974) The condition has also been reported in association with Reiter s disease (CSONKA 1966) gout (LEVITIN & KEATS 1975) and arthrosis (STEIGER et coll 1967)

Submitted for publication 19 November 1979

Several authors have pointed out the risk of erroneously considering a cyst rupture as vein thrombosis as treatment with anticoagulants because of the wall rupture will lead to extensive bleeding into the calf (BRYAN et coll MCDONALD & LEOPOLD 1972 GIBBONS et coll 1975)

Arthrography has been performed in a series of dilated symptomatic popliteal cysts in order to determine (a) whether they were caused by synovial herniation or represented a distended communicating bursa (b) their extent and size in relation to symptoms and the underlying knee disorders (c) the flow conditions between the joint and the cyst in order to demonstrate or exclude a valve mechanism and (d) the radiographic morphology in cases where the cysts and cyst rupture simulated deep venous thrombosis

Material

Forty one patients with palpable popliteal cysts giving rise to symptoms were referred for radiographic investigation Before referral the patients had been thoroughly examined by an orthopaedic surgeon with respect to the presence of any underlying knee disorder and the knee joint effusion and popliteal symptoms had been graded In most cases (37 patients) routine arthrography had been performed

Phlebography had been performed in 10 further patients with calf symptoms because of suggested thrombosis with a negative result They were then referred for orthopaedic examination and arthrography

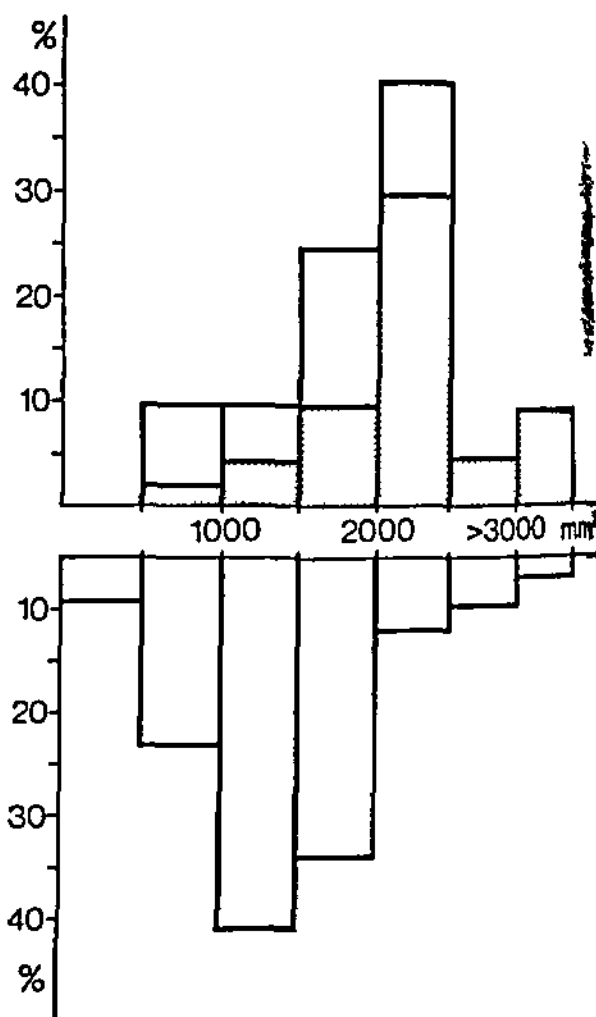


Fig 1 Upper part of figure Radiographic size of 41 popliteal cysts with (shaded bars) and without (unshaded bars) a valvular communication Lower part Radiographic size of 140 communicating gastrocnemio-semimembranosus bursae at routine arthrography (cf LINDGREN 1978)

Methods

Radiography of popliteal cyst With the patient in the prone position and the knee extended local anaesthesia was applied and the cyst was punctured with a coarse-calibre short bevelled needle (ID 1 2 mm) In 16 cases the extent of the cyst had been previously determined by grey scale ultrasound scanning at which the puncture site was marked Practically all fluid was aspirated and was replaced with water soluble contrast medium (Urografin 45% Schering) The viscosity of the aspirated fluid was graded as low if it resembled normal joint fluid viscous if at room temperature it ran slowly along the wall of a sloping test tube and highly viscous if it had a gelatinous character

Still with the knee extended the patient was placed in the lateral position During cineradiography (15 frames per s 35 mm) or fluoroscopy the knee was flexed both passively and actively and during these movements special attention was paid to whether any contrast medium passed over to the knee joint and if so the amount If no contrast medium passed to the joint at these manoeuvres the cyst was manually compressed in an attempt to provoke flow from the cyst to the joint

Conventional films were also exposed in the lateral and a p projections with the knee extended and in the lateral projection with the knee flexed Any impression on the cyst wall and any outpouching was noted The product of the sagittal length and the sagittal width was used as a measure of the size of the cyst as described previously (LINDGREN



Fig 2 Popliteal cyst with diverticular outpouchings in the upper part Impressions from the gastrocnemius (G) and semimembranosus (S) muscle



Fig 3 Popliteal cyst Contrast medium injected directly into the cyst A small amount of contrast medium passed over to the knee joint after manual compression of the cyst Irregularities in the communication caused by membranous septa (→) Confirmed at operation

In 7 patients the described examination was performed about 30 min after conventional arthrography and in the remaining patients at a separate session

In the 10 patients with acute calf symptoms arthrography was performed as follows 15 ml of contrast medium were injected into the knee joint in the conventional manner Under fluoroscopy the knee was then flexed passively and during this movement attention was focused on the flow of contrast medium in the posterior part of the joint Films were exposed in the a p and lateral projections and if deemed necessary also an oblique view was exposed

Results

In all cases the cyst lay in the medial part of the popliteal region All cysts displayed tendon impression typical for the gastrocnemio-semimembranosus bursa (LINDGREN)

In communicating cysts the site of communication was found at the same location as in physiologically communicating gastrocnemio semimembranosus bursae No kinking of the communication channel was observed on flexion of the knee On the other hand it was seen that on knee extension the channel was compressed between the medial femoral condyle and the tendon of the gastrocnemius muscle in the same way as has been demonstrated previously in cases of communication between the gastrocnemio semimembranosus bursa and the joint

The size of the cysts measured on the films compared with that of normal bursae appears in Fig 1 In general the cysts were larger than the asymptomatic communicating bursae detected accidentally at routine arthrography Irregular wall outlines with diverticular outpouchings were more frequent among the cysts than among the asymptomatic bursae (Fig 2)

On injection of contrast medium directly into the cyst spontaneous flow into the knee joint was observed in 16 patients In these patients the joint symptoms were marked and the knee effusion large while the viscosity of the aspirated fluid was low In 7 patients only a small amount of contrast medium could be forced into the joint after manual compression of the cyst (Fig 3) In 18 patients no contrast



Fig 4 Popliteal cyst with dissection and rupture of the wall *Spread of contrast medium to soft tissues of the calf in a fan* shaped fashion The patient had symptoms simulating deep venous thrombosis



Fig 5 Dissecting calf cyst originating from a gastrocnemio semimembranosus bursa *(B)*

medium could be made to pass into the joint even on manipulation (total valve mechanism) These cysts were larger than those in knees in which the flow of fluid was unobstructed in both directions and the viscosity of the cyst fluid was distinctly higher when a valve mechanism was present

In the 10 patients with calf pain suggestive of deep venous thrombosis the circumference of the calf was increased by 4 2 cm at average (2–8 cm) In all cases tenderness on pressure with a maximum over the medial head of the gastrocnemius and a positive Homann test was found At arthrography varying findings were made In 6 patients not only diverticular outpouchings of varying size from the enlarged gastrocnemio semimembranosus bursa were found but also diffuse fan shaped spreading of contrast medium into soft tissues of the calf (Fig 4) In 4 patients well-defined cavities *in the calf* communicated with the bursa (Fig 5) their wall outlines were irregular (dissecting calf cyst)

Discussion

The constantly present gastrocnemio semimembranosus bursa communicates with the knee joint increasingly with age (LINDGREN) Thus a contrast filled gastrocnemio semimembranosus bursa noted by chance at arthrography should not be called a Baker s cyst or a popliteal cyst nor should it be attributed any clinical significance if it is not giving rise to local symptoms only the dilated and symptomatic bursae should be referred to as a Baker s or popliteal cyst

In the present series all cysts were identified as dilated bursae and not one as a synovial hernia Furthermore 20 of the 41 patients were operated upon and it was confirmed that no herniation existed (RAUSCHNING 1979b)

It may be stated with a high degree of certainty that the diverticular outpouchings from the cyst wall are caused by intramural ruptures and subsequent encapsulation of the escaped fluid A rise in pressure sufficient to cause such ruptures occurs at loaded knee flexion e g squatting In the presence of a large effusion in the knee joint for example in rheumatoid arthritis the cyst not infrequently occupies a major portion of the calf compartment forming so called giant cyst

On the basis of pressure measurements JAYSON & DIXON (1970) postulated that a valve mechanism existed in the communication between the joint and the popliteal cyst In the *present series such a valve mechanism* was clearly *demonstrated in 25 of the 41* patients As a rule no underlying joint disease was found in these patients and the cyst fluid was of considerably higher viscosity than in cases without a valve mechanism At operation on some of these patients it could be elucidated that the valve mechanism was caused by a number of membranous septa at the site of communication (RAUSCHNING 1979b)

The present results allow to distinguish two different types of popliteal cysts

Th primary popliteal cyst has a valve mechanism in its connection with the joint cavity it is rarely associated with intraarticular disorders or effusion in o the joint

The secondary popliteal cyst had no valve mechanism at the site of the communication with the joint it is *frequently* associated with an underlying intraarticular disorder which causes effusion into the joint

In clinically doubtful cases the radiographic technique described should reveal whether or not a valve mechanism is present A high viscosity of the cyst fluid is strongly indicative of a valve mechanism which also implies a low probability of an underlying joint disorder

A large popliteal cyst a dissecting cyst or rupture of the cyst with efflux of the fluid simulating a deep venous thrombosis can be diagnosed by a simple arthrographic procedure not aiming at demonstrating intraarticular diseases It is convenient to perform the arthrography immediately after the phlebography if negative The efflux of contrast medium to the soft tissues of the lower leg does not accentuate calf symptoms just as inadvertent ruptures of the bursa at routine arthrography do not cause local symptoms (LINDGREN)

In several cases a passage of contrast medium from the cyst to the calf observed at radiography indicates that recurrent ruptures have taken place which further corroborates the hypothesis that large popliteal and calf cysts are formed by repeated escape and encapsulation of the synovial fluid

SUMMARY

Forty one patients with popliteal cysts were examined radiographically All cysts consisted of a dilated gastrocnemio semimembranosus bursa A valve mechanism at the site of their communication with the joint was demonstrated by a specific radiographic technique in the majority of cases The radiographic findings in popl eal cyst ruptures simulating deep venous thrombosis are described

REFERENCES

ADAMS R Chronic rheumatic arthritis of the knee joint Dublin J med Sci 17 (1840) 520

BACON P A and GERBER N J Popliteal cysts and synovial rupture in osteoarthrosis Rheumatol Rehabil 13 (1974) 98

BAKER W M The formation of synovial cysts in the leg in connection with disease of the knee joint St Bart Hosp Rep 13 (1877) 245

— The formation of abnormal synovial cysts in connection with the joints (second communication) St Bart Hosp Rep 21 (1885) 177

BRYAN R S DI MICHELE J D and FORD G L Popliteal cysts Arthrography as an aid to diagnosis and treatment Clin Orthop 50 (1967) 203

CSONKA G Thrombophlebitis in Reiter s syndrome Brit J vener Dis 42 (1966) 93

DIXON A ST J and GRANT C Acute synovial rupture in rheumatoid arthritis Clinical and experimental observations Lancet I (1964) 742

DOPPMAN J L Baker s cyst and the normal gastro cnemio semimembranosus bursa Amer J Roentgenol 94 (1965) 646

DUPUYTREN G Hydarthrose enorme du genou Anti phlogistiques Purgatifs répetes Guerison La Clinique Hum de Med Univ (Paris) *I (1829) 251*

FICAT P Pathologie synoviale *In* L arthrographie opaque du genou p 197 Masson Paris 1957

FISCHEDICK O Veranderungen des hinteren Anteils der Kniegelenkskapsel im Arthrogramm Chirurg 40 (1969) 408

GIBBONS D PHILLIPS M and PROSSOR I M Ruptured popliteal cyst simulating deep vein thrombosis with false positive radiofibrinogen uptake Postgrad med J 51 (1975) 735

GOOD A E Rheumatoid arthritis Baker s cyst and thrombophlebitis Arthr and Rheum 7 (1964) 56

HALL A P and SCOTT J T Synovial cysts and rupture of the knee joint in rheumatoid arthritis An arthro graphic study Ann rheum Dis 25 (1966) 32

HOOPER J C and BROOKLER M Popliteal cysts and their rupture in the rheumatoid arthritis simulating throm bophlebitis Med J Aust 1 (1971) 1171

JAYSON M I V SWANNELL A J KIRK J A and DIXON A ST J Acute joint rupture Ann phys Med 10 (1969) 175

JAYSON M I V and DIXON A ST J Valvular mechanisms in the formation of synovial cysts Clin Sci 38 (1970) 24

KESSLER I and SILBERMAN Z The development of pop liteal cysts An arthrographic study Clin Orthop 18 (1960) 149

LEVITIN P M and KEATS T E Dissecting popliteal cys of the popliteal space in gout Amer J Roentgenol 12 (1975) 32

LINDGREN P G Gastrocnemio semimembranosus burs and its relation to the knee joint IV Clinical con erations Acta radiol Diagnosis 19 (1978) 609

MCDONALD D G and LEOPOLD G R Ultrasound B scanning in the differentiation of Baker s cyst an thrombophlebitis Brit J Radiol 45 (1972) 720

PALLARDY G FABRE P LEDOUX LEBARD G RENOUL P et DELBARRE F Diagnostic des bursites et kys poplites par arthrographie du genou Rev Rhum 3 (1971) 345

RAUSCHNING W (a) Anatomy and function of the com munication between knee joint and popliteal bursa Ann rheum Dis 38 (1979) 50

— (b) Popliteal cysts and their relation to the gas cnemio-semimembranosus bursa. Studies on the surg cal and functional anatomy Acta orthop scand (197 Suppl No 179

REINHARDT K Popliteazysten und popliteogene Unte schenkelzysten (Bakerzysten) Radiologe 17 (1977) 7

STEIGER U WIESER C und ZINN W M Synovialcyste und rupturen des Kniegelenkes Schweiz med Wschr 97 (1967) 1212

TAYLOR A R and RANA N A A valve An explanatio of the formation of popliteal cysts Ann rheum Dis 3 (1973) 419

WOLFE R D and COLOFF B Popliteal cysts An arthr graphic study and review of the literature J Bone J Surg 54-A (1972) 1057

FROM THE DEPARTMENTS OF DIAGNOSTIC RADIOLOGY AND ORTHOPEDIC SURGERY ÖSTRA SJUKHUSET
UNIVERSITY OF GOTHENBURG S-41685 GOTHENBURG SWEDEN

ULTRASOUND IN THE DIAGNOSIS OF POPLITEAL CYSTS

P J LUKES P HERBERTS and B E ZACHRISSON

A popliteal cyst is a fluid filled mass in the posterior aspect of the knee first described by ADAMS (1840) BAKER (1877) described 10 cases and pointed out the frequent association of the popliteal cyst with intrinsic pathology of the knee The anatomic relationships between the cyst and the knee joint have been the subject of many reports The importance of a valvular mechanism and associated diseases of the knee for development of the chronic distension of the cyst has been emphasized (DOPPMAN 1965 WOLFE & COLLOFF 1972 LINDGREN 1978) The majority of clinically significant cysts is chronically distended gastrocnemio semimembranous bursae which communicate with the knee joint in about 50 per cent of the cases (WILSON et coll 1938 DOPPMAN)

The diagnosis of a popliteal cyst is usually made on the basis of a history of discomfort and pain in the medial part of the popliteal region and on the findings of a palpable mass in the popliteal fossa The symptoms can be accentuated by movements of the knee The cyst may sometimes compress the popliteal vein and produce symptoms suggestive of deep vein thrombosis (GOOD 1964 SWETT et coll 1975) If the cyst communicates with the knee joint the clinical diagnosis can be confirmed by arthrography This may also reveal the etiology of the cyst and the nature of the associated intra articular lesion (LINDBLOM 1948 WOLFE & COLLOF SWETT et coll)

In recent years growing interest has been directed to ultrasound examination as a non invasive method of examining the knee and calf in patients with symptoms and findings related to the popliteal region (MOORE et coll 1975 CARPENTER et coll 1976 KREMER et coll 1977)

The experiences at this hospital with gray scale ultrasound examination in the diagnosis of a popliteal cyst are now reported


Material and Method

The material consisted of 9 patients (3 women and 6 men) aged between 20 and 58 years with a mean age of 32 years In 7 of the patients a tense cystic mass was palpated in the politeal region Ultrasound examinations were performed on a Bruel & Kjaer gray scale system Type 3401 using a 2 MHz 10 cm focused transducer and oil as a coupling medium Images were recorded with a polaroid camera The patients were examined in the prone position Multiple longitudinal and transversal scans of the fossa poplitea were obtained at about 1 cm intervals The scans were compared with those obtained from the opposite knee In 7 patients arthrography was performed a few days later The results of both examinations were evaluated separately and the diagnostic efficacy of ultrasound and arthrography was compared

Results

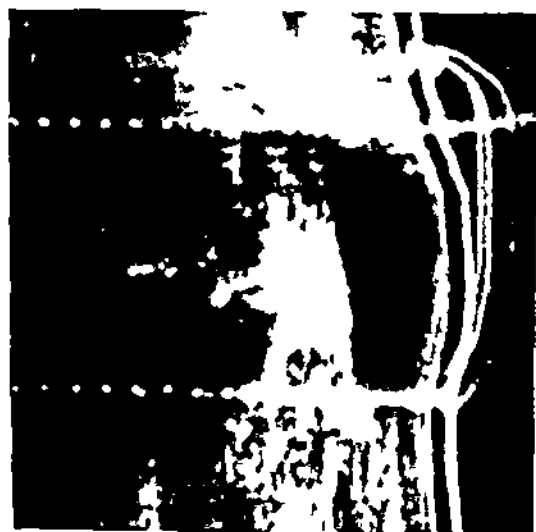
In 5 of the 7 patients with a palpated cystic mass an echo free well-circumscribed mass with smooth walls which transmitted ultrasound well was found in the popliteal fossa (Fig 1) The size of the cyst as

Submitted for publication 26 November 1979




a b

Fig 1 a) Longitudinal b) transversal scan of the fossa poplitea with a popliteal cyst




a b

Fig 2 A popliteal cyst demonstrated at a) ultrasound and b) arthrography

determined by markers displayed on the screen varied between 2 cm ×3 cm ×2 cm and 5 cm ×6 cm ×4 cm The cyst was shown at subsequent arthrography in all 5 patients to be of the same size and shape as that shown at ultrasonography (Fig 2) No intra articular lesions were demonstrated at the arthrography Two of these 5 patients were operated upon and the cyst excised In 2 patients with a palpated mass in the popliteal region no abnormality was found at ultrasonography In one of these patients arthrography was performed one week later No intra articular lesion was found nor any communicating cyst In the 2 patients with a history suggestive of popliteal cyst but without a palpated mass nothing abnormal was found at ultrasonography Arthrography performed in one of these patients revealed no cyst or intrinsic knee disorder

Discussion

Popliteal cysts usually cause only few symptoms Painless swelling and tenderness at the ba k of the

nee are common complaints However when the olume of the fluid in the cyst increases the pain y become severe and may increase with knee otion The chronically distended cyst is easily pal ated

The diagnosis of a popliteal cyst is usually not ifficult to make on the basis of the history and the inding of a palpable mass in the popliteal region but pliteal tumours which may occur should be xcluded A popliteal cyst may disappear spontane sly with remission of underlying joint disease but ecurrence even after local excision sometimes oc urs in adults (PINDER 1973) Because of the fre uent association of intra articular lesions with pop iteal cysts a careful examination including arthro phy has been recommended before surgical treatment (HAGGART 1938 1943 DOPPMAN)

The clinical diagnosis of a popliteal cyst can be confirmed by arthrography and lesions within the knee joint revealed However arthrography may be accompanied by discomfort to the patients and may cause complications Furthermore false positive or false negative results may occur

As pointed out by several authors (MOORE et coll CARPENTER et coll KREMER et coll) and as demonstrated in the present cases ultrasonography appears to be a reliable alternative screening proce dure It is easily performed in out patients and re veals cysts in the popliteal region with high accura cy Moreover ultrasound examination differentiates between cystic and solid tumours When clinical signs and ultrasonography reveal a popliteal cyst further examination of the knee should be made to demonstrate or exclude intrinsic lesions of the knee joint

SUMMARY

Ultrasound examination of 9 patients with suggested popliteal cyst was performed and the results are described and discussed Ultrasonography is a diagnostic alternative which may replace arthrography

REFERENCES

ADAMS R Chronic rheumatoid arthritis of knee joint Dublin J med Sci 17 (1840) 520

BAKER W M The formation of synovial cysts in the leg in connection with disease of the knee joint St Bartholomew s Hosp Rep 13 (1877) 245

CARPENTER J R HATTERY R R HUNDER G G BRYAN R S and MCLEOD R A Ultrasound evaluation of the popliteal space Mayo Clin Proc 51 (1976) 498

DOPPMAN J L Baker s cyst and the normal gastrocnemio semimembranosus bursa Amer J Roentgenol 94 (1965) 646

GOOD A E Rheumatoid arthritis Baker s cysts and thrombophlebitis Arth and Rheum 7 (1964) 56

HAGGART C E Posterior hernia of the knee joint A cause of internal derangement of the knee J Bone Jt Surg 20 (1938) 363

— Synovial cysts of popliteal space Clinical significance and treatment Ann Surg 118 (1943) 438

KREMER H SCHIERL W SCHATTENKIRCHNER M BAUMANN D METZ I und ZÖLLNER N Sonographische Diagnostik von Kniegelenkszysten Munch med Wschr 119 (1977) 1183

LINDBLOM K Arthrography of the knee A roentgenographic and anatomical study Acta radiol (1948) Suppl No 74

LINDGREN P G Gastrocnemio semimembranosus bursa and its relation to the knee joint III Pressure measurements in joint and bursa Acta radiol Diagnosis 19 (1978) 377

MOORE CH P SARTI D A LOUIE J S Ultrasonographic demonstration of popliteal cysts in rheumatoid arthritis Arth and Rheum 18 (1975) 577

PINDER I M Treatment of the popliteal cyst in the rheumatoid knee J Bone Jt Surg 55 B (1973) 119

SWETT H A JAFFE R B and MELF E B Popliteal cysts presentation as thrombophlebitis Radiology 115 (1975) 613

WILSON P D EYRE BROOK A L and FRANCIS J D A clinical and anatomical study of semimembranosus bursa in relation to popliteal cyst J Bone Jt Surg 20 (1938) 963

WOLFE R D and COLLOFF B Popliteal cysts J Bone Jt Surg 54-A (1972) 1057

FROM THE DEPARTMENTS OF DIAGNOSTIC RADIOLOGY II AND OF OBSTETRICS AND GYNECOLOGY
UNIVERSITY HOSPITAL OF UMEÅ S 90185 UMEÅ SWEDEN

PRENATAL RADIOGRAPHIC DIAGNOSIS OF ALPHA FETOPROTEIN POSITIVE MALFORMATIONS IN EARLY PREGNANCY

F P PROBST and J SIGURD

Since the introduction of alpha fetoprotein testing of the maternal serum and amniotic fluid it has become possible to predict several trophoblastic and fetal diseases and defects in an early stage of pregnancy The diseases are either lethal in themselves after birth or gravely incapacitating and include malformations in which fetal organs within the thoracic abdominal and cranial cavities or the contents of the spinal canal have become or have remained uncovered by skin The most common of these malformations are the various forms of somatoschisis such as ruptured omphaloceles anencephaly and myelomeningoceles The exposed tissues and organs pass fetal proteins into the amniotic fluid among these alpha fetoprotein which is identified by the test The test is entirely nonspecific and its sensitivity has not been firmly established (MILUNSKY & ALPERT 1976) False positive as well as false negative results occur and no reliable correlation exists between the concentration of alpha fetoprotein in the amniotic fluid and the type extent and severity of the malformation Hence it would seem inadvisable to recommend abortion without a morphologic confirmation (KJESSLER et coll 1977) Diagnostic methods include ultrasonography fetoscopy and radiologic procedures

The first mentioned method may prove inconclusive and fetoscopy involves a definite risk in early stages of pregnancy Radiologic methods provide an effecuve alternative The present report describes two alpha fetoprotein producing fetal deformities diagnosed in the 17th (Case 1) and the 21st (Case 2) week of gestation thus roughly at fetal ages of 15 and 19 weeks respectively The possibilities of a rational radiographic procedure as well as the diagnosis and prognosis are also discussed

Case reports

Case 1 A 28 year-old female a gravida III para I who had had a spontaneous abortion in the 12th week of pregnancy in 1975 and a normal parturition with a normal child in 1977 No known heredity for malformations An alpha fetoprotein test performed at her own request in the 13th and 14th weeks of pregnancy gave blood values of 140 and 485 kU/l respectively In week 16 a living fetus with a biparietal diameter of 3 4 cm was found at ultrasonography A repeat ultrasound examination in week 17 gave the same result The biparietal diameter was now 3 7 cm No abnormality was discernible At an amniocentesis the alpha fetoprotein content was more than 200 000 kU/l corresponding to blood values of 500 and 410 kU/l Amniography revealed distortions (Figs 1–3) A tentative diagnosis of a ruptured omphalocele with intestine and probably the liver extruded through the defect was made and abortion was induced by extra amnial instillation of Amoglandin The fetus (Fig 4) was 15 cm long and severely malformed with an abdominal wall defect through which most of the intestine and the entire liver had become eventrated and was floating in the amniotic fluid The defect was situated to the right of the insertion of the umbilical cord which was normal containing three vessels and normally separated from the defect No other deformities were evident except for a common mesenterium

Submitted for publication 11 December 1979



Fig 1



Fig 2

Fig 1 Case 1 Amniography Axial transpelvic view shortly after injection of 13 ml Amipaque 170 mg I/ml Positioning perfect Wall of uterus projected closely behind anterior part of pelvic ring Lateral position of fetus Its normal uninterrupted dorsal outline (→) is evident Buttocks (↠) thigh (↔) knee (o→) Because of ineffective evacuation the contents of the large bowel interfere with assessment of anterior body surface of fetus and obscure the eventration of abdominal organs

Fig 2 Amniography 4 h after injection of contrast medium Lateral view of fetus Anterior body outline is readily assessable Eventrated organs cause a sharply delimited filling defect in the contrast enhanced fluid (→) The fetus has swallowed contrast medium and the intra and extraabdominal bowel loops (↠) are demonstrated Anterior border of amniotic cavity (o→) occipital (>→) frontal (>→) bones back outline of fetus (↠)

Fig 3 Amniography 23 h after injection of contrast medium The woman leaned backwards too steeply Anterior wall of uterus (c→) projected too much behind pubic bones and the fetus superimposed over the sacrum Position of fetus unfavourable for prenatal diagnosis Amniotic fluid contrast-enhanced Dystopic location of the bowels well discernible (↠) Outline of fetus (↠) skull bones (→)



Fig 3

Case 2 A 25 year old female para I gravida II Alpha fetoprotein test in weeks 16 and 17 of gestation gave blood values of 375 and 275 kU/l respectively No cranium was demonstrated at ultrasound Amniocentesis in week 21 revealed greatly increased alpha fetoprotein values amounting to 120000 kU/l Conventional radiography demonstrated a fetus of adequate size but no cranium However as the cranial region was projected over the sacrum the finding was not considered sufficiently conclusive to give a reliable diagnosis Amniography (Fig 5) demonstrated the jaw and a skull base covered by a soft tissue mass but no neurocranium The diagnosis of anencephaly was established and abortion was induced by intra amnial instillation of Amoglandin The fetus was anencephalic

Discussion

Radiographic aspects In order to keep the radiation dose as low as possible and to ensure that the pregnancy can proceed should no abnormality be detected or one capable of repair the radiography should be as rational as possible and performed un



Fig 4 Case 1 Fetus with gastroschisis Liver and intestinal loops displaced outside the abdominal cavity



Fig 5 Case Anencephaly Amniography transpelvic projection Skeleton of the fetus as well as its soft tissue outline are well demonstrated No neurocranium The head consists of facial structures and a skull base (o→) covered by the soft tissue of the rudimentary brain (→)

der optimum conditions In addition to a suitable intensifying screen film combination and correct exposure due attention should be paid to the preparation of the woman for examination the projection of the uterus/fetus the choice of the contrast medium to be injected into the amniotic cavity (amniography) and the time interval between the exposures Superposition of gas or fecal bowel contents must be avoided to obtain optimum images of the fetus No films should be exposed without previous appropriate evacuation of the large intestine The younger the fetus the more important it is to achieve a clear image Positioning and projections are dependent on the age of the fetus Generally speaking the fetus should be projected free from the maternal pelvis

Transpelvic (axial) projection Up to a fetal age of about 24 weeks the transpelvic projection results in optimum imaging The woman sits on the table with her body leaning backwards about 45 degrees and supporting herself on backward stretched arms The tilting should be such that the anterior wall of the uterus projects closely behind the pubic bones when the central beam is vertical Most of the uterus and the fetus is then projected within the frame of the lesser pelvis undisturbed by overlying bone structures A steeper body position projects the fetus over the pubic bones a flatter one over the sacrum (Figs 2 3) The semi sitting position allows the uterus as well as the fetus to settle down within the pelvis by virtue of gravity Caudal direction of the beam with the patient supine gives a poorer result

Lateral projection In this view which is used routinely for determination of the fetal age during the last trimester the uterus is compressed from side to side between the plexiglass plates of a compressorium device The image of the fetus will usually be excellent and at these fetal ages the bowel contents are seldom disturbing This view is thus of value if the gestational age is over 24 weeks

For the amniography the non ionized contrast medium metrizamide (Amipaque) would appear to be superior owing to its low osmolality and low toxicity As its concentration within the fetal gut can be expected to be higher than with the osmotically active media the assessment will be facilitated The passage of the contrast medium into the bowels is one of the aims of amniography Apart from excluding an esophageal or upper intestinal obstruction the examination can demonstrate the position of the bowels within or outside the abdominal cavity on late films However the immediate objective of amniography is the outlining of the fetus which stands out in sharp contrast against the enhanced fluid around it

A carefully exposed conventional film gives the most detailed information regarding the condition of the skeleton at any fetal age On the other hand the

demonstration of the skeleton is not much poorer at amniography The examination may thus be commenced with amniography for contour imaging as the first step with the first view exposed shortly after the injection of the contrast medium This may *reduce the number of exposures by one If considered necessary* a film can be exposed after the clearance of the amniotic fluid The second film should then be exposed about 6 to 24 hours later when the contrast medium has presumably accumulated within the small intestine and the fluid around the fetus is still strongly enhanced If the transpelvic projection is used another enema should be given before exposure of that film If no true lateral view of the fetus is obtained a further film may be exposed after the patient has been rolled around on the table to ensure that the contrast medium has become well mixed with the amniotic fluid Should this view also fail to demonstrate clearly the back and abdominal outline of the fetus spot films during fluoroscopically guided correction of the fetal position should be tried Oblique positioning of the woman may be sufficient This latter procedure can also be performed primarily if there is reason to expect a neural tube defect or when such a malformation is to be excluded

In the present cases 13 ml of a metrizamide solution 170 mg I/ml were injected into the amniotic cavity However a higher concentration would have been more appropriate Subsequent experience has shown that 15 ml of a metrizamide solution 270 mg I/ml are appropriate in pregnancies of about 18 to 20 gestational weeks This means about 0 75 ml per gestational week and a doubling of the contrasting effect as compared with that in the present cases (i e 4 05 g iodine as compared with 2 21 g) Larger volumes of more highly concentrated contrast media such as 1 5 ml 75% diatrizoate meglumine (270 mg I/ml) per gestational week (which was used by WEISS et coll 1978) would not seem to be necessary or even desirable

Diagnostic and prognostic aspects The eventration of organs through a cleft in the abdominal wall may be recognized as a filling defect on the ventral side of the fetus The same is true of dorsally protruding myelomeningoceles (NOONAN 1974 WEISS et coll) Although large bulges may be readily recognized whatever position the fetus may have a true lateral view of the fetus is necessary for a correct evaluation false positive findings (MENUTTI et coll 1977 and others) are otherwise unavoidable

Absence of the neurocranium in anencephaly o[r] acrania will also be better recognized with am[nio]graphy when the fetus is small (Fig 5) The fea[tures] of anencephaly as a typical malformation are [well] known and this anomaly is therefore of no con[cern] *in the present context* As the prognosis is hope[less] the benefit to the woman of getting rid of the [non]viable fetus as early as possible is beyond questi[on]

The situation is different and more complicate[d in] the case of malformations such as gastroschisis [and] myelomeningocele In the former surgical rep[air is] possible overall cure rates vary from 84 per c[ent] (RAFFENSPERGER 1975) to about 60 per cent (LE[...] et coll 1973 MAHOUR et coll 1973 GIRVAN et co[ll] 1974 GIULIAN & ALVEAR 1978) Gastroschisis [is] defined as a complete defect of the anterior abdom[i]nal wall with evisceration of matted thickened a[nd] cyanosed intestines including the small bowel par[t] of the colon and the stomach occasionally also the gallbladder adnexa and urinary bladder b[ut] rarely of the liver The complete absence of a cove[r]ing sac and a normal insertion of the umbilical co[rd] at the margin of the defect are other characteris[tic] features which differentiate this condition fro[m] exomphalos (MOORE & STOKES 1953)

Embryologic concepts regarding the morph[o]genesis are conflicting (cf MOORE & STOKE[S] DUHAMEL 1963 COLLINS & SCHUMACHER 19[..] THOMAS & ATWELL 1976) According to the co[n]ventional view two main types of gastroschisis o[c]cur the antenatal type which is believed to occ[ur] early in fetal development and the perinatal o[ne] which is said to occur late in pregnancy supposed[ly] through a rupture of the (weakened) abdominal wa[ll] Such a distinction has not been made consistently [by] authors who have reported the results of operati[ve] repair It is thus not possible to judge whether a[nd] in what way the results were influenced by this mo[r]phogenetic grouping Instances in which the sero[sa] of eviscerated bowel loops is smooth glossy a[nd] seemingly unaffected would appear to belong to t[he] latter category which is apparently very rare [In] most cases the bowel walls are said to be thicken[ed] and the coils covered with a granular fibrogelati[n]ous exudate in other words abnormalities whi[ch] logically considered are due to long standing e[x]posure to the amniotic fluid Although these abno[r]malities have proved to be completely reversible [in] the long run after reposition and repair (THOMAS [&] ATWELL) they are considered to be responsib[le] for the common prolonged intestinal dysfuncti[on]



Fig 6 Male infant nearly 3 months old with omphalocele Liver and some intestinal loops are displaced outside the abdominal cavity Repair successfully performed in stages The boy now 10 years old (1979) is perfectly well

period that occurs postoperatively Another prognostically unfavourable abnormality which is attributable to an occurrence early in pregnancy is that the abdomen and the peritoneal cavity remain underdeveloped and the abdominal walls too small to be able to cover the eviscerated structures Although severe malformations occasionally exist in combination with gastroschisis they are much less frequent than in omphaloceles A failure of rotation of the bowel and a common mesenterium are almost invariably present in gastroschisis

In the literature on gastroschisis it is claimed that the liver is seldom included among the eviscerated organs (RAFFENSPERGER) In the present case the entire liver lay outside the abdomen as well a fact which was predicted by the radiographic appearance since only a part of the filling defect was made up of intestinal loops (cf Fig 2) This would interfere with successful postnatal operative repair As regards the radiologic procedure versus other possible examination methods it may be recalled that in the present case with gastroschisis ultrasound examination had failed to demonstrate the malformation In the case with anencephaly in which the head was not demonstrated at ultrasound this examination gave merely a negative evidence as opposed to the positive demonstration at radiography of the skull base and the rudimentary brain overlying it The radiologic procedure thus provides not only evidence of the malformation but also more detailed information regarding its nature and severity than seems to be possible with ultrasound Radiologic assessment also includes a functional element namely information on the patency or non patency of the upper intestinal canal Small gut atresia has been found in association with gastroschisis in 8 per cent (RAFFENSPERGER & JONA 1974) to 20 per cent of cases (TOULOUKIAN & SPACKMAN 1971) a combination which is usually fatal (MOORE 1963 TOULOUKIAN & SPACKMAN) The demonstration of absence of intestinal passage of the contrast medium at amniography would thus mean a bad prognosis

A distinction between omphalocele and gastroschisis can not be consistently made from the radiographically demonstrated morphology (GROSSMAN et coll 1978) This introduces additional prognostic uncertainty as omphaloceles are known to be associated more frequently than gastroschisis with other often multiple and more serious malformations JONES (1963) found serious co existent malformations of the cardiovascular genito urinary and central nervous system in 77 per cent of the 45 cases under review in 43 per cent of the cases these abnormalities themselves were the ultimate cause of death The size of an omphalocele is also of prognostic significance because the reposition of the incompressible liver is problematic requiring repair in stages (RAFFENSPERGER cf Fig 6) This fact and the usual prematurity of the infants increase the risk of complications Because of the eventration of the liver the present case was assumed to share the bad prognosis of large omphaloceles rather than the relatively good one existing for gastroschisis Thus the prognosis in gastroschisis as well as in exomphalos would seem to depend on a number of factors which may prove difficult to assess adequately even at a thorough radiographic examination The available figures in terms of survival after repair complication rate incurable associated malformations and expected quality of life in hitherto operated cases of exomphalos and gastroschisis have usually been based on diagnoses made at spontaneous deliveries or in exceptional instances shortly before term (GIULIAN & ALVEAR GROSSMAN et coll) No case seems to be known that was diagnosed and treated as early as the present Case 1

The increasing use of alpha fetoprotein testing for screening or on request will result in a considerable demand for prenatal diagnostic procedures in weeks 16 to 20 of the pregnancies Moreover the

nearly 5 per cent risk of a repetition of a neural tube defect in any further pregnancy creates a desire to avoid the birth of another child with such a defect Since about 10 per cent of the myelomeningoceles those that are covered with intact skin do not cause a significant rise in the alpha fetoprotein concentration (LAURENCE et coll 1975) prenatal radiographic procedures are indicated in all women who have given birth to children with such abnormalities

The presence or even the absence (FRIGOLETTO & GRISCOM 1974) of a bulge on the ventral or dorsal side of a fetus can be successfully demonstrated by amniography but this presupposes a rational examination technique

SUMMARY

Early diagnosis of two malformed fetuses with positive alpha fetoprotein test of the amniotic fluid with the aid of amniography is reported Radiographic diagnostic and prognostic aspects are discussed

REFERENCES

COLLINS D L and SCHUMACHER A E Omphalocele ruptured before birth Proc Pediatr Surg Congr Melbourne 1 (1970) 21

DUHAMEL B The embryology of exomphalos and allied malformations Arch Dis Childh 38 (1963) 142

FRIGOLETTO F D and GRISCOM N T Amniography for the detection of fetal myelomeningocele Obstet and Gynecol 44 (1974) 286

GIRVAN D P WEBSTER D M and SHANDLING B The treatment of omphalocele and gastroschisis Surg Gynec Obstet 139 (1974) 222

GILLIAN B B and ALVEAR D T Prenatal ultrasonographic diagnosis of fetal gastroschisis Radiology 129 (1978) 473

GROSSMAN M FISCHERMANN E A and GERMAN J Sonographic findings in gastroschisis J clin Ultrasound 6 (1978) 175

HOLLABAUGH R S and BOLES JR E T The managemen[illegible] of gastroschisis J Pediat Surg 8 (1973) 263

KJESSLER B HEMMINGSSON A NILSSON B A and JOHANSSON S G O Early diagnosis of trophoblas[illegible] disease and fetal maldevelopment by determination of alpha fetoprotein (AFP) human chorionic gonadotro-pin (hcg) and amniography Acta obstet gynec sca[illegible] (1977) Suppl No 69 p 83

JONES P G Exomphalos a review of 45 cases Arch Dis Childh 38 (1963) 180

LAURENCE K M WALKER S M and LLOYD M Equivocal amniotic AFP levels associated with ope[illegible] spina bifida Lancet I (1975) 81

LEWIS JR J E KRAFGER R R and DAVIS R K Gas-troschisis Ten year review Arch Surg 107 (19[illegible]) 218

MAHOUR G H WEITZMAN J J and ROSENKRANTZ J G Omphalocele and gastroschisis Ann Surg 177 (19[illegible]) 478

MENUTTI M T MORANZ J G SCHWARZ R H an[illegible] MELLMAN W J Amniography for the early detectio[illegible] of neural tube defects Obstet and Gynec 49 (19[illegible]) 25

MILUNSKY H and ALPERT E Prenatal diagnosis of neu-al tube defects II Analysis of false positive and fal[illegible] negative AFP results Obstet and Gynec 48 (1976) [illegible]

MOORE T C Gastroschisis with antenatal evisceration [illegible] intestines and urinary bladder Ann Surg 158 (196[illegible]) 263

— and STOKES G E Gastroschisis Surgery 33 (195[illegible]) 112

NOONAN C D Antenatal diagnosis of fetal abnormalitie[illegible] Radiol Clin N Amer 12 (1974) 1

RAFFENSPERGER J G Congenital defects of the gastroin-testinal tract and abdominal wall Amer J Dis Chil[illegible] 129 (1975) 1145

— and JONA J Z Gastroschisis Surg Gynec Obs[illegible] 138 (1974) 230

THOMAS D F M and ATWELL J D The embryology an[illegible] surgical management of gastroschisis Brit J Surg [illegible] (1976) 893

TOULOUKIAN R J and SPACKMAN G J Repair of ga[illegible] troschisis Surg Gynec Obstet 132 (1971) 699

WEISS R R MACRI J N and BALSAM D Amniograph[illegible] in the prenatal diagnosis of neural tube defects Obs[illegible] and Gynec 51 (1978) 299

OM THE DEPARTMENT OF DIAGNOSTIC RADIOLOGY III (DIRECTOR DOCENT CARL GUSTAF HELANDER) SAHLGRENSKA SJUKHUSET S-41132 GOTHENBURG SWEDEN


STORAGE AND DISPLAY OF INFORMATION IN ROENTGEN FILMS

S REICHMANN K G STRID and L LUNDIN


Information storage in roentgen films is based on transformation of silver halide into metallic silver impermeable to light The total quantity of information that can be stored in a given area of a roentgen film is likely to be related to the number of silver halide grains in that area Each time a silver grain is precipitated more information is stored However part of this information may be of a spurious character The diagnostic information about the object is inherent in local exposure variations rather than in the total exposure reaching the image receptor (i e the roentgen film) If the total exposure is large with only small local variations the background exposure may precipitate large amounts of silver without any corresponding useful information about the object being stored in the film On the contrary this process may prevent silver halide grains from being accessible for the storage of the small local exposure variations that give the desired diagnostic information about the object The silver halide grains are the elementary receptors of information and when excessive background exposure impairs the capacity of the roentgen film to record the useful exposure variations the term receptor saturation may be used (DAINTY & SHAW 1974) This process has been analysed experimentally (SELIN & REICHMANN 1977 REICHMANN et coll 1978) as well as theoretically (STRID & REICHMANN 1980) It was found that the diagnostic exposure variations are best recorded when the background density of the film is about 1 3 Although the contrast of the film as expressed by the gamma value did not drop at higher density values the recording of small low-contrast details was found to suffer when the background density was increased

Another mechanism underlying high-density failure may be suggested Within a film emulsion there are large numbers of silver halide grains in several layers on top of each other In order to make possible a rapid processing of the film the gelatin content of the emulsion is minimised leading to dense packing of the grains If each grain is regarded as a storage unit for information there must also be a display function for the information thus stored Imagine so many grains to be present in the emulsion as to make e g ten layers distinguishable If two silver grains are precipitated in different layers but on top of each other in the direction of the penetrating illuminating light one grain will obscure the other Part of the information stored in the film will thus become invisible Just as in the case of receptor saturation this impairment of information display should be expected to be more severe when the film density is high


Submitted for publication 19 December 1979



a



b



c



d

Fig 1 Photomicrographs of a) lowest and b) highest density 0 38 and 1 52 respectively corresponding to 0 76 and 3 04 for a dou ble-emulsioned film c d) The same films after reversal develop ment The latter images display the distribution of the silver halide which was fixed away in (a) and (b) This silver constitutes the total capacity of reaction to increased exposure in terms of further precipitation of silver Magnification ×300

Thus long before a roentgen film is overexposed in the sensitometric sense of the word the recording of small image details of low contrast is increasingly impaired partly due to more and more silver hal ide grains being consumed by the increasing background exposure (receptor saturation storage defect) partly due to a superimposition of pre cipitated silver grains (defective display of informa tion actually stored) The present investigation was designed to yield a qualitative visual impression of how these two factors cooperate in lowering film performance at high density values

Experiments

A conventional roentgen film (Curix RP 1 Agfa Gevaert) was examined It was exposed on one side by means of an intensifying screen (X-Omatic Fine Eastman Kodak) in a stepwise manner making it possible to construct the characteristic curve and derive the gamma value of the film Only the emul sion facing the screen was developed Before de velopment the film was divided longitudinally One of the strips was tank developed and fixed The other strip underwent reversal development so that bright areas in the first strip were rendered dark in the second The reversal development implied to begin with ordinary development exactly as for the first strip This first step however was not followed by fixing instead the silver precipitated was re moved by means of chromic acid The remaining silver halide was exposed to light and a second de velopment was carried out followed by fixing In this way the second strip was made to demonstrate the amount and location of the silver halide removed by fixing from the first strip Thus for each expo-






Fig 2 Summation images obtained from photomicrographs of directly and reversely developed films of identical exposure (cf Fig 1) The density values of the directly developed films are a) 0 38 b) 0 60 c) 1 30 and d) 1 52 The summation images show how much of the silver would have been precipitated on areas where no silver was present provided the film had been given a further maximum exposure This silver (dark spots) displays the number and distribution of sites where the film may both store and display information Increasing background density leads to rapid impairment in this respect The gamma values in (a) and (c) are identical Magnification ×300


sure step this second strip gave an image of the total remaining storage capacity as expressed in the remaining silver halide able to react to further exposure

The density was determined for each exposure level and the characteristic curve was constructed by means of a third degree regression analysis smoothing out errors of measurement From this regression curve the gamma value at each step could be estimated The mean error in the transformation of measured values into the regression curve was 0 03 in density units The reversal development gave rise to slightly lower contrast than did the direct development The difference was however considered insignificant On the basis of densitometric data four different exposure levels were chosen for further analysis Two of these were taken from the low-density range the other two were of high density The density difference in both pairs amounted to 0 22 The gamma value of the directly developed film was 1 14 for the lower density in each pair For the exposure levels thus chosen both the directly and the reversely developed films were photomicrographed eight micrographs thus being produced These were further enlarged onto Curix film which was machine processed the total magnification being 1000 times The Curix film was chosen in order to ensure high contrast so that no grey tones would appear in the films but only black and white The double emulsion of the film did not disturb the reproduction


Fig 1 displays the lowest and the highest density




a



b



c



d

Fig 3 Summation images of the same films as in Fig 2 obtained by an analogous method black spots indicating silver precipitated by a further maximum exposure on sites where silver already was present This silver represents stored information which cannot give rise to any substantial change in image density Thus the information is stored but displayed Magnification ×300

directly developed together with their reversals The highest density was 1 52 which corresponds to 3 04 in a double-emulsioned film At this exposure level the film approaches its maximum blackening Still the reversal film indicated that there were further silver halide grains to be precipitated these grains being evenly spread out over the film surface This means that the information storage capacity was not exhausted even at this high value of the density However the directly developed film indicated that most of the silver precipitated by a further exposure would fall at sites where so much silver was already present as to make the additional silver largely in visible A further exposure would thus have been stored but its display would have been seriously obstructed by the background blackening already present If any further change in density were to take place silver would be precipitated in the small scattered sites where light could still pass the film

The reversal films displayed the amount as well as the location of the silver available for further pre cipitation Therefore it was considered of interest to find out how this silver would be distributed when projected onto the directly developed emulsion By doing so it would be possible to find out how much would be superimposed on silver already precipi tated as compared with the silver giving rise to changes in density

The superimposing of the reversal films on the directly developed ones was carried out in two dif ferent ways One indicated silver falling onto silver the other silver falling onto bright areas First all the eight magnified micrographs were contact-copied onto Curix film These copies transmitted light at the sites of silver in their respective originals In order to find out how much silver would fall onto bright areas in the directly developed films the con tact copy of the reversal film was placed on top

corresponding directly developed film The where both films transmitted light indicated a ical mean for the location of density changing precipitation *The result was recorded by con*)pying of the superimposed films (Fig 2) In images black areas denote the silver that may ise to increased density Increasing back d density drastically reduced the amount of grains which could both store and display the iation inherent in a further exposure

silver falling onto silver was demonstrated by mposing the contact copies of both the direct eloped films and the corresponding reversals *areas in both of these copies implied silver in* iginal films and so contact copying gave rise to image where black areas indicated an average er precipitated on silver (Fig 3) In this case ference was seen between the four films

Discussion

: impairment of film performance at high densi ues may be assumed to arise from either a lack ver halide grains (storage defect) or from the nstance that precipitated silver grains may not nce the transmitted light during inspection ay defect) or from both The present analysis sts that the display defect is of considerable rtance However it must be emphasised that ction of light is a composite process depending oth absorption and scattering If absorption the only factor the present analysis would be oletely correct insofar as light would be able to the *developed emulsion only through the bright* free from silver grains However light may ev n through black areas by means of reflexion or more silver grains this scattering effect more marked when grain size is large and ity high (Callier effect) Thus silver precipi l on silver may still have some informative value)ugh it may be assumed to be small

igh-density failure essentially implies that the ber of silver grains giving rise to a change in ity decreases considerably with increasing background density (Fig 2) These silver grains being only part of the total number of silver grains precipitated (cf Figs 2 3) will represent only a *fraction of the roentgen quanta giving rise to the* exposure increase Furthermore loss of quanta also results from receptor saturation The increased blackening thus caused by comparatively few quan ta will in fact suffer from a high level of quantum mottle which makes small details of low contrast disappear from the image Due to the defective re cording this mottle is not visible in the films it just leads to films lacking in information for no apparent reason

SUMMARY

Roentgen images of high density without actually being overexposed tend to leave small details of low contrast unrecorded Still these details may be reproduced by the same film if the density is lower even if the gamma value is kept constant The present report is concerned with how information is stored in the film and the information stored is displayed to the inspecting eye It appears that films of high density contain information which is invisi ble so that the disappearance of image details to a certain *extent reflects a defect of display*

ACKNOWLEDGEMENT

This investigation was supported by a grant from the Swedish Medical Research Council (project No B80 29X 5360)

REFERENCES

DAINTY J C and SHAW R *Image science Principles* analysis and evaluation of photographic type imaging processes Academic Press London New York and San Francisco 1974

REICHMANN S HELANDER C G and SELIN K Medi chrome film as an alternative to silver free recording systems Acta radiol Diagnosis 19 (1978) 513

SELIN K and REICHMANN S High density failure of radiographic films Acta radiol Diagnosis 18 (1977) 95

STRID K G and REICHMANN S Receptor saturation in roentgen films To be published in Acta radiol Diagnosis 21 (1980)

FROM THE DEPARTMENTS OF DIAGNOSTIC RADIOLOGY AND EXPERIMENTAL RESEARCH MALMO ALLMANNA SJUKHUS S 21401 MALMO SWEDEN

EFFECT OF pH, BUFFER AND OSMOLALITY OF DIFFERENT CONTRAST MEDIA ON AORTIC BLOOD PRESSURE IN THE RABBIT

U NYMAN T ALMEN and M LANDTMAN

Injections of modern ionic monomeric contrast media (iothalamate metrizoate and diatrizoate Fig 1a b c) and other hypertonic solutions into the aorta and peripheral arteries are often painful and produce a decrease in peripheral vascular resistance (LINDGREN & TORNELL 1958 MARSHALL & SHEPHERD 1959 READ et coll 1960 HILAL 1966 LINDGREN et coll 1967 1968 EFSEN & MUNKNER 1968 DELIUS & ERIKSON 1969 OVERBECK & GRECA 1970 CHAHINE & RAIZNER 1976) Both experimental and clinical investigations indicate that such injections of metrizamide a non ionic monomeric contrast medium (Fig 1d) cause less pain and less hemodynamic changes than currently used ionic monomeric media (ALMEN 1973a b ALMEN & TRAGÅRDH 1973 MEVES et coll 1978)

The ionic monomeric contrast media have a ratio of 3/2 (=1 5) for the number of iodine atoms/number of particles in an ideal solution compared with a ratio of 3/1 (=3 0) for metrizamide (Fig 2) At equal iodine concentrations metrizamide has a lower osmolality than an ionic monomeric medium Metrizamide has the drawback of not tolerating autoclaving It is sterilized by filtration and then freeze dried and supplied as a powder which has to be dissolved in water before use Sterile filtration and freeze-drying is more expensive then autoclaving

C29 and ioxaglate are two new contrast media with a ratio of 3 0 (Fig 1e f) C29 is a non ionic monomer and ioxaglate a monoacidic dimer They tolerate autoclaving but the stability of a contrast medium solution during autoclaving may vary with its pH and buffer used The effect on aortic blood pressure following intra aortic injections of different contrast media with variation of pH buffer and ratio of the solutions has been investigated and was compared with that of hypertonic solution of sodium chloride

Material and Methods

Forty male rabbits weighing 3 0 to 4 2 kg were used Following intravenous anesthesia with pentobarbitone the animals were placed supine and fixed with their legs slightly extended A polyethylene catheter (PE 90 Clay Adams) was introduced via a femoral artery and placed with its tip in the abdominal aorta at the level of the third lumbar vertebra The catheter was used both for injection of the solutions and blood pressure measurements It was connected through a 3 way stopcock to a pressure transducer (EMT 34 Siemens Elema) The blood pressure in the abdominal aorta was continuously recorded on a Mingograf (Siemens Elema) for one min before and 3 min after the injections The connection between the catheter and transducer was temporarily switched off for 3 to 5 s while injections of the solutions were

---

Submitted for publication 19 November 1979

performed During this period the blood pressure could not be recorded

Four separate experimental series were carried out In the first 3 (groups 1–3) the effect on aortic blood pressure from variation of pH and buffer in solutions of metrizamide and C29 was analysed and compared with the effect of media with a ratio of 1 5 In the fourth experiment (group 4) the effect of all media with a ratio of 3 0 and one with a ratio of 1 5 was analysed and compared with equiosmolal solutions of sodium chloride (Table)

In each group all solutions were injected only once in each animal The injections were made manually and in random order in a dose of 2 ml at room temperature except for group 4 where the solutions were preheated to 310 K (37°C) The time of injection was about 1 second A time interval of at least 10 min elapsed between each injection The contrast media had a concentration of 0 74 mol/l except for ioxaglate which had a concentration of 0 37 mol/l This gives an iodine concentration for all media of 280 mg/ml At these concentrations the media with a ratio of 1 5 (iothalamate metrizoate and diatrizoate) and sodium chloride 0 75 mol/l have an osmolality of approximately 1 5 mol/kg while the media with a ratio of 3 0 (metrizamide ioxaglate and C29) and sodium chloride 0 25 mol/l have an osmolality of approximately 0 5 mol/kg The statistical analysis was made according to the Wilcoxon s test for paired differences and a p value of 0 05 or less was considered significant

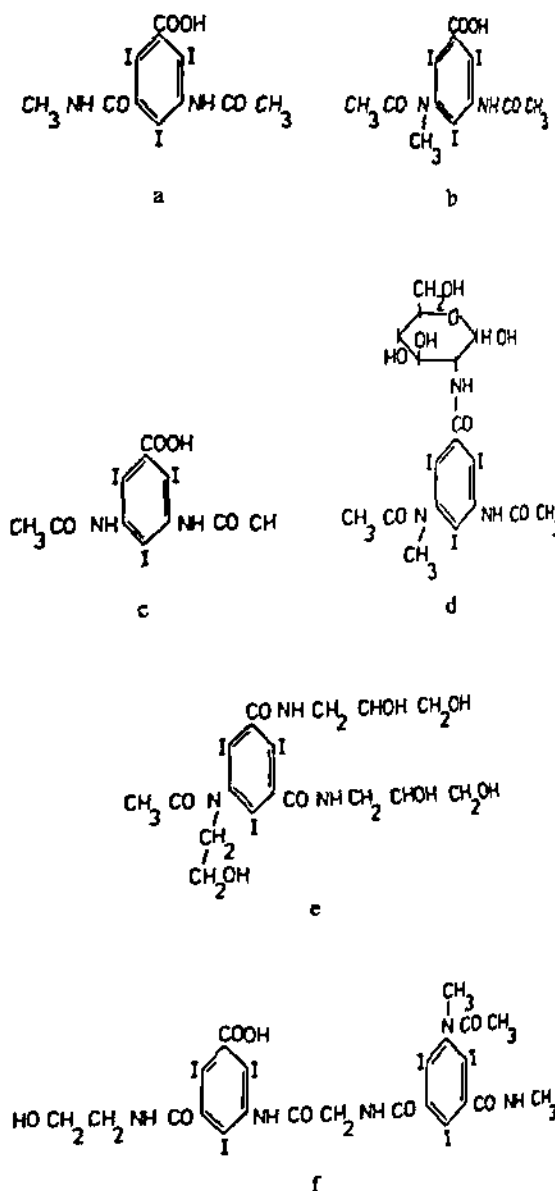


Fig 1 a) Iothalamic acid (Conray Meglumin = meglum iothalamate) b) Metrizoic acid (Isopaque Cerebral = meglum metrizoate/calcium metrizoate 5? 3/1 w/w) c) Diatrizoic a (Urografin 60% = meglumine diatrizoate/sodium diatrizoat 6 6/1 w/w—diluted with water to 280 mg I/ml) d) Metrizam (Amipaque) e) C29 f) Ioxaglic acid (meglumine ioxaglate/sod ioxaglate 2/1 w/w)

Results

The aortic blood pressure varied slightly with respiration but was otherwise stable throughout the experiments and changed only following injection of the test solutions (Fig 3) The results are summarized in the Table

Effect of contrast media (groups 1 to 4) Following injection of the contrast medium solutions both systolic and diastolic blood pressure decreased with the exception for 9 of 88 injections of the ratio 3 0 media at pH 7 3 to 7 4 where no changes occurred The decrease in blood pressure reached a minimum approximately 10 s after the injections and returned to preinjection values within one min Metrizamide and C29 independent of pH and buffer and ioxaglate caused significantly less decrease in aortic blood pressure than the ratio 1 5 media with which they were compared No significant difference existed between metrizamide C29 and ioxagate at pH (group 4) In group 2 no significant difference found between iothalamate and diatrizoate

Effect of non ionic contrast media with differ pH and buffer (groups 1 to 3) Increasing the acid of the non ionic contrast media increased changes in aortic blood pressure Metrizamide at 7 4 caused significantly less fall in aortic blood pr sure than at pH 5 0 (group 1) The same signific difference was noted between C29 at pH 7 3 and (group 2) When metrizamide and C29 were solved in different buffering systems (phosph

	Chemical structure	Ratio	
a	Na+ I−	$\frac{1}{2} = 0\ 5$	
b	Na+ (RCOO, N, I, I, R)	$\frac{2}{2} = 1$	
c	Na+ (COO, I, I, R, R, I)	$\frac{3}{2} = 1\ 5$	Ionic monomeric
d	Na+ (COO, I, I, R, I) – R – (COO, I, I, R, I) Na+	$\frac{6}{3} = 2$	Diacidic dimeric
e	Na+ (R, I, I, R, I) – R – (COO, I, I, R, I)	$\frac{6}{2} = 3$	Monoacidic dimeric
f	(ROH, I, I, HOR, ROH, I)	$\frac{3}{1} = 3$	Non-ionic monomeric
g	(ROH, I, I, HOR, I) – R – (ROH, I, I, ROH, I)	$\frac{6}{1} = 6$	Non ionic dimeric

1. Chemical structure and ratio of clinical or experimental ast media The letter R indicates not specified chemical ure Media in a–e) are ionic solutions while f) and g) are non ionic solutions The development of contrast media from a to g) has meant an increase of the ratio with a factor of 12 with a subsequent decrease in osmolality at equal iodine concentrations

S and bicarbonate) at pH 7 3 to 7 4 no signifi difference in the response (groups 1 and 3) oc ed Unbuffered solutions of metrizamide (hydro acid) at pH 5 0 produced the same decrease lood pressure as buffered solutions of metriza e (phosphate buffer) at the same pH (group 1)

ffect of unbuffered hypertonic solutions of um chloride (group 4) Sodium chloride 0 75 l) produced the same decrease in aortic blood ssure as diatrizoate but the duration of the de ase was significantly shorter (median 16 s) than er diatrizoate (median 25 s) Sodium chloride 0 25 l) caused no significant alteration in aortic blood ssure

Discussion

According to previous comprehensive experimen l and clinical investigations decrease in arterial od pressure following injections of contrast media and hypertonic solutions of sodium chloride into the aorta and peripheral arteries is due to a decrease in peripheral vascular resistance (READ et coll OVERBECK et coll 1961 HILAL EFSEN & MUNKNER DELIUS & ERIKSON CHAHINE & RAIZNER This decrease has been attributed to a local effect on the peripheral vessels of the injected solutions causing vasodilatation

Hypertonicity The vasodilatory properties of ionic monomeric contrast media in current clinical use have to a large extent been related to their hypertonicity relative to plasma The effect is similar to that of other solutions in equiosmolal con centrations such as sodium chloride glucose man nitol and urea (HILAL KLOSTER et coll 1967 LINDGREN et coll 1967) An increase in the ratio of contrast media from 1 5 (ionic monomeric media) to 2 0 (diacidic dimeric media) and further to 3 0 (non ionic monomeric and monoacidic dimeric media)

Table

Decrease in aortic systolic blood pressure following intra aortic injection The figures represent the maximum decrease in systolic pressure after the injection expressed in percentage of the lowest systolic pressure during one min before the injection Median value and range are given

	pH	Decrease
Group 1 (n = 12)		
Meglumine/calcium metrizoate (Isopaque Cerebral)	7 2	18 3 (11 3–24 4)
Metrizamide dissolved in diluted hydrochloric acid	5 0	10 3 (6 1–23 5)
Metrizamide dissolved in sodium phosphate buffer 0 01 mol/l	5 0	11 3 (5 1–25 7)
Metrizamide dissolved in sodium phosphate buffer 0 01 mol/l	5 5	7 3 (2 9–12 0)
Metrizamide dissolved in sodium phosphate buffer 0 01 mol/l	6 2	6 4 (2 8–10 5)
Metrizamide dissolved in sodium phosphate buffer 0 01 mol/l	7 4	5 1 (0 0–13 6)
Metrizamide dissolved in sodium bicarbonate buffer 0 0006 mol/l (Amipaque)	7 4	5 8 (0 0–13 1)
Group 2 (n = 10)		
Meglumine iothalamate (Conray Meglumin)	7 3	19 5 (11 4–29 4)
Meglumine/sodium diatrizoate (Urografin)	7 0	18 0 (13 5–31 4)
C29 dissolved in sodium phosphate buffer 0 01 mol/l	5 0	10 5 (1 3–20 0)
C29 dissolved in sodium phosphate buffer 0 01 mol/l	6 0	6 8 (2 7–18 3)
C29 dissolved in sodium phosphate buffer 0 01 mol/l	7 3	5 0 (0 0–10 5)
Group 3 (n = 8)		
Meglumine/calcium metrizoate (Isopaque Cerebral)	7 3	20 1 (13 9–30 0)
C29 dissolved in sodium phosphate buffer 0 01 mol/l	7 3	7 6 (3 0–10 5)
C29 dissolved in TRIS buffer ($(CH_2OH)_3CNH_2$) 0 01 mol/l	7 4	5 0 (3 1–9 8)
Metrizamide dissolved in sodium bicarb buffer 0 0006 mol/l (Amipaque)	7 4	6 1 (3 0–9 0)
Group 4 (n = 10)		
Meglumine/sodium diatrizoate (Urografin)	7 0	15 8 (7 3–45 1)
C29 dissolved in TRIS buffer 0 01 mol/l	7 4	10 0 (0 0–79 5)
Meglumine/sodium ioxaglate	7 4	9 3 (0 0–28 8)
Metrizamide dissolved in sodium bicarb buffer 0 0006 mol/l (Amipaque	7 4	7 0 (0 0–28 2)
Sodium chloride unbuffered solution 0 75 mol/l	5 5	16 2 (4 6–50 0)
Sodium chloride unbuffered solution 0 25 mol/l	5 5	0 0 (0 0–1 1)

represents a gradual decrease in osmolality of solutions at iodine equivalent concentrations and gradually decreased effect of peripheral vascular resistance (HILAL BJÖRK et coll 1969 ALMÉN & TRÄGÅRDH ALMÉN et coll 1977 NYMAN & ALMÉN 1978) The present results are in accordance with this Furthermore the reproduction of an identical hemodynamic response using contrast medium solutions which differ in regard to cation content chemical structure of the iodinated organic molecule viscosity or other physico chemical properties except for osmolality supports the concept that hypertonicity of the solutions is the main factor causing vasodilatation

Sodium chloride in concentrations equiosmolal with the ratio 3 0 contrast media caused no obvious changes in aortic blood pressure while the media with a ratio of 3 0 did In addition the hypotensive reaction lasted longer following injection of diatrizoate than following equiosmolal solutions of sodium chloride This indicates that factors other than hypertonicity may contribute to vasodilatation and the relative importance of such factors may increase when the osmolality is reduced

Chemotoxicity LINDGREN et coll (1968) demonstrated that acetrizoate a previously used ratio 1 contrast medium was a stronger vasodilator than the ratio 1 5 media used in the present experiments ALMÉN & TRÄGÅRDH reported that the vasodilatory effect of the non ionic metrizamide was less than Compound 17 which was another nonionic medium with an osmolality similar to that of metrizamide This difference in response of equiosmolal contrast medium solutions may result from difference in chemotoxicity of the iodinated organic molecule per se

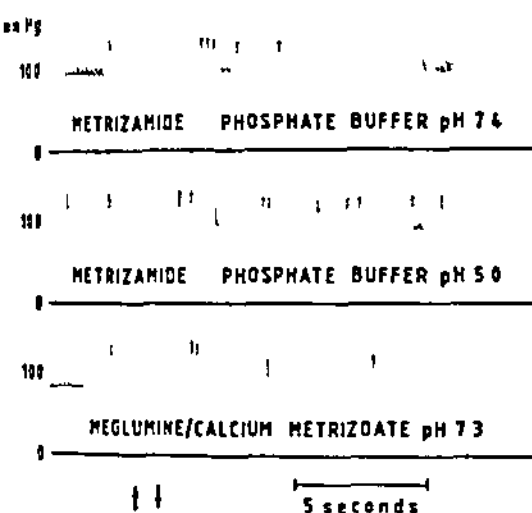


Fig 3 Recordings of aortic blood pressure before and after injection of various contrast media into the aorta Time of injection (1 s) Start (↑) end (↓) of injection

Viscosity Microcirculatory investigations indicate that the high viscosity of contrast media compared with sodium chloride solutions may play some role when evaluating the difference in hemodynamic response (SÖRENSEN & ASANO 1971 EKELAND & LFLACKER 1978) According to these authors intraarterial bolus injections of contrast medium solutions and sodium chloride give a short period of ischemia during their passage through the peripheral vascular bed The duration of the ischemic or passive time was significantly longer for contrast media than for iso and hypertonic solutions of sodium chloride a difference that might be related to the higher viscosity of the contrast medium solutions This would mean an increased application time for the contrast media during which they can exert their osmotic and possible chemotoxic effects In addition the ischemic effect per se of an injected bolus may contribute to the decrease in vascular resistance A reactive hyperemia following the ischemic period would then be more marked after injection of contrast media then after sodium chloride Thus the difference in hypotensive reaction noted in the present experiments between contrast media and equiosmolal solutions of sodium chloride may theoretically be explained by a chemotoxic effect of the iodinated organic molecule or by the higher viscosity of the contrast media

The pH of the solution must also be considered when evaluating the effect on the peripheral vascular resistance It is known that solutions both on the acid and alkaline side of the physiologic pH range have vasodilatory properties (ELLIOTT & JASPER 1949 KESTER et coll 1952 DEAL & GREEN 1954 HADDY et coll 1958) Both the present and previous results (ALMÉN 1973a) indicate that progressive alteration of the pH below 7 4 of non ionic contrast media will increase the fall in aortic blood pressure

According to KESTER et coll injections of buffered acid and alkaline solutions of sodium chloride produce a decrease in peripheral vascular resistance while variation of pH of unbuffered solutions of sodium chloride do not The difference in hypotensive effect between injections of buffered solutions of metrizamide and C29 at pH 5 0 compared with injection of the same solutions at pH 7 3 to 7 4 was therefore expected However metrizamide adjusted to pH 5 0 by adding hydrochloric acid an unbuffered solution produced the same decrease in blood pressure as a buffered solution of metrizamide at the same pH While KESTER et coll injected 1 ml of sodium chloride during 10 s into the femoral artery in dogs 2 ml during 1 s was injected into the aorta in rabbits in the present experiments These differences in methods cannot explain the hypotensive effect of unbuffered solutions of metrizamide at pH 5 0 since injections of unbuffered equiosmolal solutions of sodium chloride at pH 5 5 did not produce any fall in aortic blood pressure One explanation may be that the ability of blood to buffer unbuffered acidic solutions of contrast media may be counteracted by their high viscosity which delays the mixing of blood and contrast media The unbuffered contrast media may thus still possess their acidic properties when reaching the peripheral vascular bed

Injections of metrizamide and C29 at pH 7 3 to 7 4 with the use of phosphate TRIS and bicarbonate as different buffering systems did not cause any difference in hypotensive reaction

Conclusions

Contrast medium solutions for peripheral angiography should have an osmolality and a pH close to that of human plasma in order to minimize the risk of fall in arterial blood pressure The choice of buffer (phosphate TRIS and bicarbonate) in order to give the solutions a proper pH seems to be of minor importance

SUMMARY

Intra aortic injections in rabbits of contrast media with a lower osmolality (metrizamide C29 and ioxaglate) caused significantly less decrease in aortic blood pressure than injections of contrast media with a higher osmolality (diatrizoate metrizoate and iothalamate) at iodine equivalent concentrations Increasing the acidity of metrizamide and C29 form pH 7 4 to 5 0 increased the blood pressure fall Variation of the buffer (phosphate TRIS and bicarbonate) in metrizamide and C29 solutions at physiologic pH did not cause any difference in response

REFERENCES

ALMÉN T (a) Influence of pH of metrizamide on hypotension following intra aortic injection An investigation in rabbits of non ionic and ionic contrast media Acta radiol (1973) Suppl No 335 p 203

— (b) Cardiovascular effects of injection of metrizamide and other contrast media into aortic bulb of cats Acta radiol (1973) Suppl 335 p 209

— and TRAGÅRDH B Effects of non ionic contrast media on the blood flow through the femoral artery in dogs Acta radiol (1973) Suppl No 335 p 197

— BOIJSEN E and LINDELL S E Metrizamide in angiography I Femoral angiography *Acta radiol Diagnosis* 18 (1977) 33

BJÖRK L ERIKSON U and INGELMAN B Clinical experiences with a new type of contrast medium in peripheral arteriography Amer J Roentgenol 106 (1969) 418

CHAHINE R A and RAIZNER A E The mechanism of hypotension following angiography Invest Radiol 11 (1976) 472

DEAL C P and GREEN H D Effects of pH on blood flow and peripheral resistance in muscular and cutaneous vascular beds in the hind limb of the pentobarbitalized dog Circulat Res 2 (1954) 148

DELIUS W and ERIKSON U Effects of contrast medium on blood flow and blood pressure in lower extremities Amer J Roentgenol 107 (1969) 869

EFSEN F and MUNKNER T Influence of abdominal aortography on arterial blood pressure cardiac output and heart rate Invest Radiol 3 (1968) 6

EKELAND A and UFLACKER R Effect of meglumine metrizoate and metrizamide on microcirculation Animal experiments Acta radiol Diagnosis 19 (1978) 969

ELLIOTT K A C and JASPER H H Physiological salt solutions for brain surgery Studies on local pH and pial reactions to buffered and unbuffered isotonic solutions J Neurosurg 6 (1949) 140

HADDY F J EMANUEL D and SCOTT J Influence of local cation concentration variation upon small and large vessels and vessel response to norepinephrine and acetyl beta methylcholine Clin Res Proc [...] (1958) 230

HILAL S Hemodynamic changes associated with intra ar[terial] injection of contrast media New toxicity test[s] and a new experimental contrast medium Radiolog[y] 86 (1966) 615

KESTER N C RICHARDSON A W and GREEN H D Effect of controlled hydrogen ion concentration o[n] peripheral vascular tone and blood flow in innervate[d] hind leg of the dog Amer J Physiol 169 (195?) 678

KLOSTER F E BRISTOW J D PORTER G A JUDKIN[S] M P and GRISWOLD H E Comparative hemo[dynamic] dynamic effect of equiosmolar injections of an[giographic] giographic contrast materials Invest Radiol ? (1967) 353

LINDGREN P and TÖRNELL G Blood circulation durin[g] and after peripheral arteriography Experimental stud[y] of the effects of Triurol (sodium acetrizoate) an[d] Hypaque (sodium diatrizoate) Acta radiol 49 (1958) 425

— SALTZMAN G F and TÖRNELL G Vascular effects [of] metrizoate compounds Isopaque Na and Isopaqu[e] Na/Ca/Mg Acta radiol (1967) Suppl No 270 p 44

— — — Circulatory effects of iothalamate compoun[ds] (Conray) and contrast media of the benzoic acid typ[e] Acta radiol Diagnosis 7 (1968) 48

MARSHALL R J and SHEPHERD J T Effect of injection of hypertonic solutions on blood flow through th[e] *femoral artery of the dog* Amer J Physiol 197 (195[9]) 951

MEVES M HÜTHWOHL B und KRASKA H Die Anwe[n]dung von Metrizamid bei der peripheren Angiographi[e] Eine vergleichende Untersuchung Fortschr Röntge[n]str 128 (1978) 339

NYMAN U and ALMÉN T Arterial and venous bloo[d] pressure and blood flow following femoral angiograph[y] with a new non ionic contrast medium An experime[n]tal investigation in dogs Acta radiol Diagnosis [...] (1978) 1025

OVERBECK H W and GREGA G J Response of the lim[b] vascular bed in man to intrabrachial arterial infusion of hypertonic dextrose and hypertonic sodium chlori[de] solutions Circulat Res 26 (1970) 717

— MOLNAR J I and HADDY F J Resistance to bloo[d] flow through the vascular bed of the dog forelim[b] Local effects of sodium potassium calcium magn[e]sium acetate hypertonicity and hypotonicity Ame[r] J Cardiol 8 (1961) 533

READ R C JOHNSON J A VICK J A and MEYER M W Vascular effects of hypertonic solutions Circulat Re[s] 8 (1960) 538

SÖRENSEN S E and ASANO M Effects of water solub[le] contrast media on the microcirculation in peripher[al] nerves Registration of flow by microphotoelectr[ic] plethysmography Acta radiol Diagnosis 11 (1971) 402

FROM THE DEPARTMENT OF DIAGNOSTIC RADIOLOGY AND THE LABORATORY OF CLINICAL CHEMISTRY SAHLGRENSKA SJUKHUSET S-41345 GOTHENBURG AND THE DEPARTMENT OF EXPERIMENTAL RESEARCH MALMÖ ALLMANNA SJUKHUS S 21401 MALMÖ SWEDEN

LIVER TOXICITY OF DIATRIZOATE AND A NON IONIC CONTRAST MEDIUM (C29)

Coeliac angiography in the rabbit

K MÅRE T ALMÉN and J WALDENSTROM

Metrizamide (Figure) which was the first non ionic water soluble contrast medium on the market has a lower subarachnoid and intravenous toxicity than presently available ionic monomeric media (SALVESEN 1973) Metrizamide does not tolerate autoclaving and is therefore sterilized by filtration and then freeze dried This has two disadvantages Sterile filtration and freeze drying is more expensive than autoclaving and secondly before the use in patients metrizamide powder has to be dissolved in water while autoclaved solutions of contrast media are ready for direct use

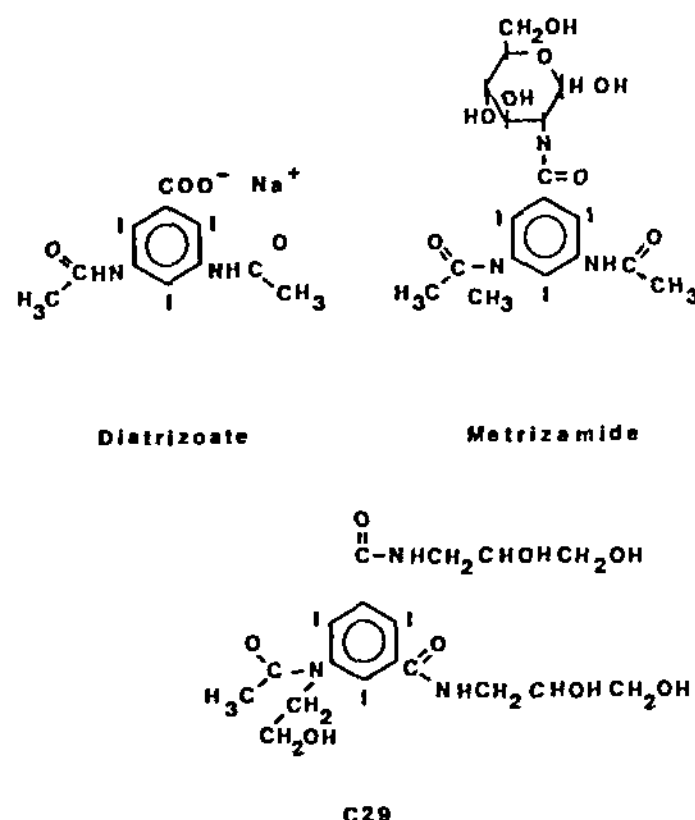
In an effort to find a substance which tolerates autoclaving and has an equal or lower toxicity than that of metrizamide C29 has been syntehsized At an injection rate of 1 2 ml/min (300 mg I/ml) the intravenous LD_{50} in mice is 18 6 g I/kg for metrizamide and 21 9 g I/kg for C29 (SALVESEN 1977) Thus C29 has a low acute intravenous toxicity

Previous animal experiments (MÅRE et coll 1980) indicated that the liver toxicity of C29 is low In those experiments small animals (rats) were used because only small amounts of contrast medium were available The experiments were difficult to evaluate due to the high postoperative mortality following the surgical insertion of a catheter into the gastroduodenal artery followed by infusion through the catheter for more than a week Therefore the present experiments were designed to decrease the mortality by means of a much smaller surgical trauma In rabbits the contrast media C29 and diatrizoate (Urografin 76%) were injected into the coeliac artery and the serum values of ALAT ASAT ALP and bilirubin before and after injection were determined and compared with those following injection of saline

Material and Method

The material consisted of 46 male rabbits (Mollegaard Denmark) weighing 2 4 to 4 1 kg (mean 3 0 kg) The animals had free access to food and water They were anaesthetized with pentobarbitone (Mebumal 60 mg/ml ACO) via an ear vein The tissue surrounding the femoral artery was infiltrated with lidocain (Xylocain 5 mg/ml Astra) and the artery was exposed A few drops of lidocain were dripped on the artery which was ligated distally A catheter (Radicath Cerebral infant from Radiplast OD 1 22 mm) was inserted into the aorta from the femoral artery The catheter was intermittently flushed with saline During fluoroscopy the catheter tip was placed in the coeliac artery This position was so characteristic that no test dose of contrast medium was given to the animals in the saline group

Submitted for publication 7 November 1979



Chemical structure of diatrizoate (Schering) metrizamide (Nyegaard) and C29 (Nyegaard) Urografin 76% is a mixture of sodium diatrizoate and meglumine diatrizoate in weight relation 1/6 6

Table

Mean values in serum of ALAT ASAT and ALP (μkat/l) and bilirubin (μmol/l)

	Before injection	Days after injection			
		1	2	3	7
Saline	(16 animals)				
ALAT	1 1	0 99	1 2	1 0	1 0
ASAT	0 38	0 28	0 40	0 35	0 29
ALP	3 6	2 8	3 0	2 8	3 0
Bilirubin	3 6	2 5	3 6	2 5	3 0
Urografin 76%	(10 animals)				
ALAT	0 79	0 74	0 85	0 76	0 [illegible]
ASAT	0 33	0 32	0.35	0 30	0 27
ALP	3 5	3 0	3 2	3 5	3 0
Bilirubin	2 6	2 6	2 4	2 8	3 0
C29 batch 1	(10 animals)				
ALAT	0 84	0 90	0 87	0 80	0 91
ASAT	0 39	0 31	0 31	0 30	0 29
ALP	3 3	2 6	2 6	2 8	2 7
Bilirubin	3 3	2 5	2 5	2 7	2 4
C29 batch 2	(10 animals)				
ALAT	1 3	1 2	1 2	1 2	1 3
ASAT	0 36	0 30	0 34	0.38	0.39
ALP	3 1	2 6	3 0	3 1	3 0
Bilirubin	4 5	3 0	3 0	3 7	2.5

In all rabbits given contrast media the position of the catheter tip in the coeliac artery was always controlled Care was taken not to occlude the artery Contrast medium was injected manually during fluoroscopy as quickly as the artery was able to receive it without backflow into the aorta Immediately after the injection the catheter was withdrawn and the femoral artery was ligated proximal to the site of the puncture

Injection of contrast medium or saline into the coeliac artery was made in a volume of 5 ml/kg rabbit Both contrast media had a concentration of 370 mg I/ml Total dose of contrast medium to an animal thus became 4 86 mmol/kg rabbit Chemical structures of the contrast media are given in the Figure

Before injection into the coeliac artery a blood sample for analysis was taken from the catheter as soon as it was inserted into the aorta Further blood samples were taken from an ear vein by phlebotomy on day 1 2 3 and 7 after the injection

Blood was centrifuged after coagulation and serum kept at +4 C before analysis which was carried out within 48 hours at the Laboratory of Clinical Chemistry Using an autoanalyser alanine amino transferase (EC2 6 1 2 ALAT) aspartate amino transferase (EC2 6 1 1 ASAT) and alkaline phosphatase (EC3 1 3 1 ALP) were determined according to the recommendations of the committee on enzymes of the Scandinavian Society for clinical chemistry and clinical physiology (1974) The coefficient of variation for the three enzymes was about 2 per cent for each enzyme Bilirubin was determined by a modification of the method described by NOSSLIN (1960) The coefficient of variation was about 6 per cent

Results

No postoperative mortality occurred All rabbits survived the sampling period and were then killed

Following injections of s iline or contrast medium into the coeliac artery no significant increase was found in the serum concentrations of ALAT ASAT ALP or bilirubin The mean values of these concentrations never re iched values which were 10 per cent or more above the mean values before the injections (Table)

Discussion

Serum activities of various enzymes are known to be sensitive parameters of hepatocellular injury (ZIMMERMAN 1964 ZIMMERMAN & SEEF 1970) By injection of 3 ml/kg body weight of metrizamide or metrizoate (350 mg I/ml) into the coeliac artery of rabbits SKALPE et coll (1973) noticed a slight but significant rise in serum activity of ASAT and ALAT as well as a rise in the LDH5 fraction on the following day No changes were demonstrated using conventional microscopic examination of the liver but by using the colcemid method an increase in the mitotic activity was demonstrated As none of the changes occurred after saline injections the authors concluded that a small but transient injury to the liver cells was caused by the contrast media used

The present results agree with those of ENGEVIK (1968) He found in rat experiments that ionic contrast media (acetrizoate diatrizoate iothalamate and metrizoate) given by the intra arterial or intraportal route to the liver did not cause toxic liver injury He concluded that it would be possible to administer large amounts of contrast media to patients with impaired liver function for example after liver resections

In the present series in spite of high doses of contrast medium (in man of 70 kg equal to 350 ml) no significant changes in serum levels of ASAT or ALAT were recorded using diatrizoate or C29 It seems therefore probable to expect C29 to cause no more injury to liver cells than diatrizoate following coeliac angiography in man

SUMMARY

Toxic effect on the liver of diatrizoate and a new non ionic contrast medium (C29) were investigated using coeliac angiography in rabbits The contrast media were injected in doses of 5 ml/kg rabbit with a concentration of 370 mg I/ml Serum levels of ALAT ASAT ALP and bilirubin did not change significantly after the injections

ACKNOWLEDGEMENTS

This investigation was supported by the Swedish Medical Research Council (Project No 3483)

Request for reprints Dr Torsten Almen Department of Diagnostic Radiology Malmo Allmanna Sjukhus S 214 01 Malmo Sweden

REFERENCES

Committee on enzymes of the Scandinavian society for clinical chemistry and clinical physiology Recommended methods for the determination of four enzymes in blood Scand J Clin Lab Invest 33 (1974) 291

ENGEVIK L Influence of angiographic contrast media on the liver Acta chir scand (1968) Suppl No 392

MÅRE K ALMEN T and LINDELL B Liver toxicity of ionic (diatrizoate) and non ionic (C29) contrast medium Effects on serum enzymes after hepatic artery injection in rat Accepted for publ Invest Radiol

NOSSLIN B The direct diazo reaction in bile pigments in serum Scand J Clin Lab Invest 12 (1960) Suppl No 49

SALVESEN S Acute toxicity test of metrizamide Acta radiol (1973) Suppl No 335 p 5

— Personal communication (1977) Data in files of Nyegaard & Co A/s Oslo Norway

SKALPE I EVENSEN A and STRÖMME J Toxicity of metrizamide and metrizoate An experimental study in rabbits Acta radiol (1973) Suppl No 335 p 186

ZIMMERMAN H Serum enzymes in the diagnosis of hepatic disease Gastroenterology 46 (1964) 613

— and SEEF L Enzymes in hepatic disease *In* Diagnostic enzymology p 1 Edited by E Coodley Lea and febiger Philadelphia 1970

A C T A R A D I O L O G I C A

Vol. 21 Fasc 6 DIAGNOSIS 1980

ANGIOGRAPHY OF CHEMODECTOMAS OF THE NECK

JAN BRISMAR

Chemodectomas also known as non chromaffin paragangliomas and as glomus tumours i e tumours of the chemo- and baroreceptor system of the body although comparatively rare may be located at a variety of sites They have long been known to occur at the carotid body (review SCHECHTER & CHUSID 1966) ROSENWASSER (1945) demonstrated that similar tumours could also originate from the jugular bulb and intratympanic structures (recent review COLE 1977) and in 1961 BERK presented the first cases of glomus tumour in association with the cervical part of the vagal nerve (recent review BLACK et coll 1977) Single cases of chemodectomas have also been found at other locations such as intraorbitally (FISHER & HAZARD 1957) at the trachea (MCCALL & KARAM 1958) at the larynx (ANDREWS 1955) and at the aortic arch (LATTES 1950) Although benign in more than 90 per cent of cases (STAATS et coll 1966) chemodectomas because of their growth in topographically critical regions may take a clinically malignant course It is debated particularly in patients with tumours close to the skull base whether radical surgery radiation therapy or a combination should be attempted (HATFIELD et coll 1972 ARTHUR 1977 BLACK et coll COLE) Radiation therapy may control local tumour progression but carries a definite risk of radiation necrosis of brain or medulla (MARUYAMA 1972) Surgery is often technically difficult and dangerous due to the close connection between the tumour and major vessels and nervous structures A detailed angiographic mapping of the arterial supply of the tumour is indispensable before operation a preoperative arterial embolisation may further facilitate surgery by decreasing intraoperative hemorrhage Due to the extreme vascularity of chemodectomas open diagnostic biopsy should be avoided unless resection of the tumour is contemplated (BLACK et coll) Aspiration biopsy is seldom of value (NELSON 1962) and therefore the diagnosis often relies mainly upon angiography A detailed angiography is thus important in chemodectomas both for diagnosis and treatment

Material The material consisted of 17 patients with chemodectoma diagnosed during the period 1965 to 1979 One patient had bilateral tumours The age and sex distribution of the patient material the location of the tumour as well as the extent of the angiographic procedures appear from Table 1

Results and Discussion

The arterial supply of the tumours (Figs 1 2) is presented in Table 2 In patients with carotid body tumours the vascular supply was variable—the ascending pharyngeal artery the superior thyreoidal artery the lingual artery as well as direct branches from the proximal external carotid artery probably corresponding to the artery of the glomus caroticum (Fig 2) most frequently contributed in single cases also minor branches from the facial occipital and sternocleidomastoid arteries This is in concordance with the experiences of DJINDJIAN & MER

From the Section of Neuroradiology Department of Diagnostic Radiology University Hospital S-221 85 Lund Sweden Submitted for publication 10 October 1979

Table 1

Eighteen cases with chemodectoma Age and sex of patients location and size of tumours Extent of angiographic evaluation cca ica eca=common internal external carotid arteries deca=distal external carotid artery (distal to the origins of stha oa la fa and apha) va = vertebral artery stha = superior thyroidal artery oa = occipital artery la=lingual artery fa=facial artery ma=maxillary artery raa=retroauricular artery apha=ascending pharyngeal artery ata=anterior tympanic artery cba=carotid body artery R and L denotes right and left respectively

Case No	Sex age	Tumour location	Tumour size (mm)	Vessels examined selectively
1	M 11	Car body L	70×50×40	ccaL ecaL icaL vaL
2	F 28	Car body L	80×75×65	ccaL icaL
3	M 24	Car body L	70×35×25	ccaL ecaL decaL faL aphaL cbaL icaL
4	F 31	Car body R	40×30×30	ccaR ecaR sthaR
5	M 38	Car body L	60×40×40	ccaL laL faL sthaL aphaL maL icaL
6	F 43	Car body R	65×50×40	ccaR decaR icaR
7	M 62	Vagal body L	80×50×50	ccaL
8	M 33	Glomus jug L	50×30×30	ccaL ecaRL aphaRL icaRL maL raaL ataL
9	F 67	Glomus jug R	50×35×30	ecaRL icaRL oaR aphaR maR vaR
10	F 68	Glomus jug L	40×30×30	ccaL icaL
11	F 63	Glomus jug R	65×35×35	ccaRL ecaRL icaRL vaRL aphaR raaR
12	F 51	Glomus jug R	65×30×30	ccaR
13	F 70	Glomus jug R	30×?0×20	ecaR decaR
14	F 63	Glomus tymp R	diam 20	ecaR decaR oa+aphaR icaR
15	F 64	Glomus tymp R	diam 5	ccaR decaR icaR
16	F 65	Glomus tymp R	15×10×10	ccaRL ecaR icaR
		Glomus tymp L	diam 8	ccaRL ecaR icaR
17	M 49	Glomus tymp L	diam 5	ccaL vaL

LAND (1978) that branches from all adjacent vessels participate In 2 patients the internal carotid artery also took part in the supply of the tumour in one patient (No 2) through a descending branch originating from the internal carotid artery at the skull base in the other (No 6) through a clival artery from the intracavernous portion of the internal carotid artery

The radiologic differentiation between tumours originating in the glomus tympanicum and growing downwards into the jugular region and tumours of the glomus jugulare invading the skull base may be difficult These tumours although of different origin are therefore often treated as one entity (PALACIOS 1970 GAILLARD et coll 1977) In the present series 4 tumours (in 3 patients) were located in the middle ear (Fig 3) In one of these patients the only finding was an accumulation of contrast medium obscuring the external acoustic meatus during the parenchyma phase of the common carotid angiography (MANELFE et coll 1972) in this patient (No 17) no analysis of the vascular supply could be made In a fifth patient (No 14 Fig 4) the intratympanic size of the tumour indicated that the tumour had originated in the tympanic cavity and grown down into the jugular fossa The remaining cases a[...] had the typical radiologic appearance of a glom[...] jugulare tumour The arterial supply in all cases wit[...] a tympanojugular tumour was uniform The ascen[...]ing pharyngeal artery (in 2 cases originating as [...] branch from the occipital artery and in one from th[...] internal carotid artery) and the retroauricular arter[...] constituted the main feeders The anterior tympan[...] artery participated in the supply of 6 tumours—in [...] it originated from the superficial temporal arter[...] (Fig 4) in 3 from the distal external carotid arter[...] proximal to the origin of the superficial tempor[...] artery Minor meningeal branches from the midd[...] meningeal (Fig 4) and occipital arteries contribute[...] to the tumour supply in 2 patients with tumou[...] growth into the posterior fossa In one of these pa[...]tients as well as in another patient with intracrani[...] tumour extension branches from the vertebral a[...]tery (Fig 5) also supplied the tumour The interna[...] carotid artery took part in the supply in two cases [...] one through multiple minor branches at the skul[...] base (Fig 6) in one via the meningohypophysea[...] trunk The arterial supply observed in the presen[...] series is in concordance with that described in pre[...]vious reports (FARELL & HAWKINS 1967 MANELF[...]



Fig 1 Carotid body tumour (case No 5) lateral views a) Injection into eca. Highly vascular tumour at the carotid bifurcation b) apha constitutes the main feeder but also c) la through d) a proximal branch (→) and e) fa as well as f) stha through small branches (⇸) contribute to the supply of the tumour (↠)

et coll HEKSTER et coll 1973 LACOUR et coll 1975 CASTAN et coll 1978)

In the patient (No 7) with a vagal body tumour only common carotid angiography was performed making it difficult to evaluate in detail the arterial supply of the tumour Both the ascending pharyngeal and sternocleidomastoid arteries as well as direct branches from the external carotid appeared to participate

Opinions differ regarding how extensive the angiographic evaluation of a chemodectoma should be A detailed mapping of the external carotid artery supply as needed both for preoperative embolisation and for surgery often requires superselective external carotid artery procedures on the side of the tumour or at least one proximal and one or two more distal injections into the external carotid artery The internal carotid artery supply to these tumours is usually of minor surgical importance an internal carotid artery injection with cross carotid



Fig 2 Carotid body tumour (case No 3) lateral views a) Injection into eca Slight spill over to ica (→) vascular tumour at the carotid bifurcation b) Selective injection into artery of the carotid body constituting the main feeder of the tumour

Table 2

Arterial supply in 18 chemodectomas The location of the tumours appears from Table 1 The arterial supply was classified as +++=major feeders ++=significant contribution to arterial supply +=minor contribution eca = proximal direct external carotid artery branches stha = superior thyroidal artery la = lingual artery fa = facial artery oa = occipital artery apha = ascending pharyngeal artery scla = sternocleidomastoid artery raa = retroauricular artery ata = anterior tympanic artery sta = superficial temporal artery mma = middle meningeal artery ica = internal carotid artery va = vertebral artery

Case No	eca	stha	la	fa	oa	apha	scla	raa	ata	sta	mma	ica	va
1						+++							
2	+++	++	++		++	++						+	
3	+++		++				+[1]						
4	++	+++											
5		++	++	+		+++							
6						+++						+	
7	++					+++	+++						
8						+++		++	+				
9						+++		++				+	+
10						+++[2]		+++	++			+	
11						+++[3]		+	+		+		+
12				++		+++		+++					
13						+++		++		+[4]			
14					+	+++[2]		++		+	+		
15						++		+		+			
16R						+++		++					
16L						+++		++					

[1] branch of apha [2] branch of oa [3] branch of ica [4] probably identical with ata




Fig. 3 Tympanojugular tumour (case No 16 R) a) Lateral b c) ap views Small tumour (→) supplied from apha (↔) as well as fm (↦)

compression is nevertheless required in order to evaluate the patency of the anterior communicating and anterior cerebral arteries in case a carotid ligation should be needed at surgery Most authors claim that the carotid artery of the contralateral asymptomatic side should also always be examined (EL GAMMAL 1971 HEKSTER et coll LACOUR et coll DUNCAN et coll 1979) While this seems indisputably warranted in patients with a family history of chemodectoma in which case the risk of bilateral tumours amounts to 26 per cent (RUSH 1963) it is less obvious in patients without such a history and at a risk of bilateral tumours of only 2 8 per cent The vertebral artery is known to participate in the supply of chemodectomas with an intracranial growth It therefore seems logical to apply vertebral angiography in patients with a clinical symptomatology or findings on skull films indicating such ingrowth



Fig. 4 Jugular body tumour (case No 14) lateral views a) Injection into eca demonstrates highly vascular tumour in tympanojugular region b) Injection into common stem for apha and oa discloses apha as main feeder (→) c) Injection into deca demonstrates supply from raa (↔) ata (↦) and mma (↦) to upper part of tumour (↦)




Fig 5a



Fig 5b




Fig 6

Fig 5 Jugular body tumour (case No 10) a) A p b) lateral views Small direct branches from ica participate in supply of tumour (→)

Fig 6 Jugular body tumour (case No 9) lateral view S muscular branches (↔) from va contribute in supply of tu (→)

(FARRELL & HAWKINS PALACIOS) It is less evident that an evaluation of the vertebral artery (EL GAMMAL HEKSTER et coll CASTAN et coll DUNCAN et coll) and perhaps also the subclavian artery should be performed as a routine also in patients without such symptoms or findings in order to evaluate possible tumour supply from minor muscular branches

In the present material (Fig 7) the injection of contrast medium was performed manually usually during 1 to 2 s Depending on the site of injection (common carotid artery external carotid artery or a branch to the external carotid artery) 8 to 4 ml of contrast medium was injected The duration of the arterial phase was approximately the same (mean 1 2 s) The tissue accumulation in all cases began less than 1 5 s after the medium has reached the supplying arteries and had a duration of 1 5 to 6 s (mean 3 8 s) Contrast medium could be identified in extratumoural veins at an average of 2 0 s after the medium had reached the supplying arteries (range 1 0–3 0 s) PROBST (1971) in 4 patients achieved similar results when the injection time was about 1 s the arterial phase did not exceed 1 5 s and the parenchymatous phase amounted to about 4 s

Accumulation of contrast medium in the tumour was invariably homogeneous although often somewhat granular in 15 of 16 cases it was classified as heavy in the remaining case (No 11) moderate In 2 cases with a small intratympanic tumour (Nos 15 and 17) the findings were too subtle to be classifiable

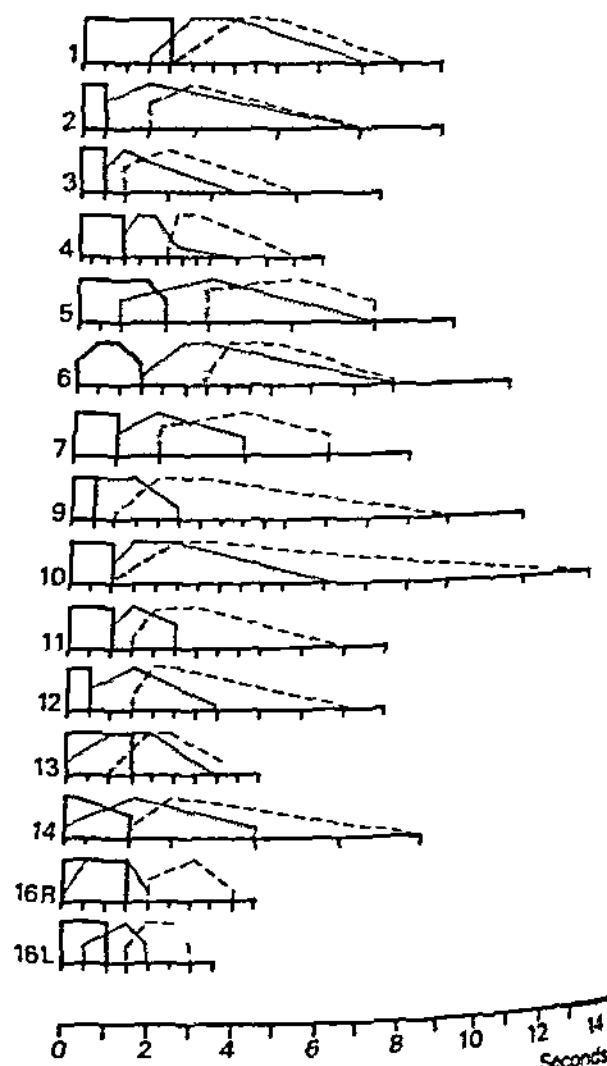


Fig 7 Circulation dynamics in 15 chemodectomas Thick solid line = duration and intensity of arterial phase hatched area = parenchymatous phase interrupted line = venous phase Time in seconds

Conclusions

Evaluation of the arterial supply of chemodectomas in the neck requires selective external carotid artery angiography often superselective procedures are also required for a detailed preoperative and pre-embolisation mapping of the tumour vascularity An ipsilateral internal carotid angiography during contralateral carotid compression should also be included as it gives information not only on the internal carotid supply of the tumour but also on the patency of the circle of Willis In cases without symptoms or signs indicating intracranial growth vertebral angiography can probably be dispensed with as well as contralateral carotid angiography in patients without a family history of chemodectoma

The angiographic features of chemodectomas seem to be relatively constant Carotid body tumours may be supplied from any of the external carotid artery branches that pass in the vicinity of the tumour and often also by minor primary proximal external carotid branches probably identical with the arteries of the glomus caroticum Tympanojugular tumours are regularly supplied from both the retroauricular and the ascending pharyngeal arteries often also from the anterior tympanic artery Other arteries contribute only to a minor extent All chemodectomas in the neck have the same tumour circulation characteristics a short arterial phase a parenchymatous phase of comparatively long duration and early filling of extratumoural veins

SUMMARY

In 18 chemodectomas of the neck (6 carotid body tumours 1 vagal body tumour and 11 tympanojugular tumours) the arterial supply and circulatory characteristics were evaluated at angiography The arterial supply of the carotid body tumours was derived from all adjacent vessels including direct carotid body branches of the proximal external carotid artery The arterial supply in tympanojugular tumours constantly came from both the ascending pharyngeal and retroauricular arteries and often also from the anterior tympanic artery Other branches contributed less constantly and only to a minor degree except for the vertebral artery in cases with tumour extension intracranially The circulatory characteristics were constant in the series a short arterial phase was rapidly followed by a phase of relatively long duration with marked somewhat granular accumulation of contrast medium and also by an early filling of draining veins The planning of the angiographic procedure in cases of chemodectoma is discussed

REFERENCES

ANDREWS JR A H Glomus tumor (non-chromaffin paraganglioma) of larynx Arch Otolaryng Soc Trans 61 (1955) 716

ARTHUR K Radiotherapy in chemodectoma of the glomus jugulare Clin Radiol 28 (1977) 415

BERK M E Chemodectoma of glomus intravagale Case report and review Clin Radiol 12 (1961) 219

BLACK F O MYERS E N and PARNES S M Surgical management of vagal chemodectomas Laryngoscope 87 (1977) 1259

CASTAN PH TARBOURIECH E et BOUZIGE J C Tumeurs glomiques tympano-jugulaires (chemodectomes) Bilan angiographique de quatorze cas Arteriographie et jugulographie Ann Radiol 21 (1978) 571

COLE J M Glomus jugulare tumor Laryngoscope 87 (1977) 1244

DJINDJIAN R and MERLAND J J Superselective arteriography of the external carotid artery Springer Verlag Berlin 1978

DUNCAN A W LACK E E and DECK M F Radiological evaluation of paragangliomas of the head and neck Radiology 132 (1979) 99

EL GAMMAL T The blood supply of chemodectomas of the head and neck Report of two cases Brit J Radiol 44 (1971) 515

FARRELL V J and HAWKINS T D Glomus jugulare tumours with special reference to their radiological features Brit J Surg 54 (1967) 789

FISHER E R and HAZARD J B Nonchromaffin paraganglioma of the orbit Cancer 5 (1952) 521

GAILLARD J HAGUENAUER J P et ROMANET PH Chemodectomes de la tete et du cou J franç Oto-rhino-laryng 26 (1977) 765

HATFIELD PH M JAMES A E and SCHULZ M D Chemodectomas of the glomus jugulare Cancer 30 (1972) 1164

HEKSTER R E M LUYENDIJK W and MATRICALI B Transfemoral catheter embolisation A method of treatment of glomus jugulare tumors Neuroradiology 5 (1973) 208

LACOUR P DOYON D MANELFE C PICARD L SALISACHS P et SCHWAAB G L embolisation arterielle therapeutique dans les chemodectomes (tumeurs glomiques) J Neuroradiol 2 (1975) 275

LATTES R Nonchromaffin paraganglioma of the ganglion nodosum carotid body and aortic arch bodies Cancer 3 (1950) 667

MANELFE C ROULLEAU J JULIAN A and GUIDICELLI G Glomus tympanicum tumours Early diagnosis by arteriography Neuroradiology 4 (1972) 226

MARUYAMA Y Radiotherapy of tympanojugular chemodectomas Radiology 105 (1972) 659

MCCALL J W and KARAM K K Chemodectoma of the trachea Arch Otolaryng 67 (1958) 372

NELSON W K Carotid body tumors Surgery 51 (1962) 326

PALACIOS E Chemodectomas of the head and neck Amer J Roentgenol 110 (1970) 129

PROBST F P Chemodectomas of the neck Report of six

cases with a review of the literature Radiologe 11 (1971) 15
ROSENWASSER H Carotid body tumor of the middle ear and mastoid Arch Otolaryng 41 (1945) 64
RUSH JR B F Familiar bilateral carotid body tumors Ann Surg 157 (1963) 633
SCHECHTER M M and CHUSID J G Chemodectomas of the carotid bifurcation Acta radiol Diagnosis 5 (1966) 488
STAATS E F BROWN R L and SMITH R R Carotid body tumors benign and malignant Laryngoscope 76 (1966) 907

FROM THE DEPARTMENTS OF RADIOLOGY AND OTORHINOLARYNGOLOGY UNIVERSITY OF CALIFORNIA DAVIS CALIFORNIA 95616 USA

CEREBRAL BLOOD FLOW DETERMINATION BY VIDEO DILUTION TECHNIQUE IN A PATIENT WITH MALIGNANT CHEMODECTOMA

B M T LANTZ A B DUBLIN P J DONALD
D P LINK and J P MCGAHAN

Blood flow determination by video dilution technique was performed on the extracranial cerebral circulation in a patient with malignant chemodectoma The recently introduced technique (LANTZ 1974 1975 LINK et coll 1979 LANTZ et coll 1979 1980 b c d) has proven to be highly accurate and is easily applied in a clinical setting in connection with routine angiography The blood flow determination will give valuable information about hemodynamics which may be of great importance for the surgical treatment of the patient

Case report

A [illegible]9-year-old white male was admitted to this ENT clinic with complaints of hoarseness since 6 months and left shoulder weakness mild dysphagia and an irritating cough since about 4 months He had no complaints of hearing loss tinnitus or facial weakness Physical examination revealed a healthy appearing young man with a hoarse breathy voice in no distress atrophy and paralysis of the left side of the tongue a flaccid paralysis of the left vocal cord and atrophy with total immobility of the left trapezius and sternocleidomastoid muscles However his soft palate elevated in the midline and a normal gag response was elicited bilaterally indicating an incomplete paralysis of the IX and X cranial nerves No masses were palpable in the neck Otologic examination was entirely normal hearing was excellent in both ears and facial nerve function was symmetric A diagnosis of jugular foramen syndrome was made and a tumor at the base of the skull was suggested

Radiology Computed tomography of the head revealed a mass anterior and to the left of C1 displacing the internal carotid artery anteriorly (Fig 1) At subsequent angiography a vascular tumor was found supplied mainly by the left ascending pharyngeal artery without invasion of the internal carotid artery and with compression of the internal jugular vein (Fig 2)

Blood flow was determined by video dilution technique during angiography in the common external and internal carotid arteries bilaterally as a percentage of the cardiac output (Fig 3) Normal flow rates (LANTZ et coll 1980a) were obtained in both common carotid arteries (9 5 and 9 4% respectively) with normal distribution to the internal (5 6%) and external (3 9%) carotid arteries on the right side However on the left side where the vascular tumor was supplied by a branch of the external carotid artery the distribution of flow to the internal (3 0%) and external (6 4%) carotid arteries was severely altered The internal flow was reduced almost 50 per cent compared with the right side

Embolization The patient was re admitted for embolization of the left ascending pharyngeal artery supplying the majority of the tumor because of the high flow rate to the external carotid artery (Fig 4) Multiple occlusions by Ivalon pellets were accomplished with a subsequent decrease in blood flow in the ascending pharyngeal artery by 33 per cent Further embolization was not attempted due to a severe coughing spell the latter possibly secondary to irritation of the glossopharyngeal nerve

Operation A 4 cm × 2 cm hard mass was found at the base of the skull arising from the jugular vein and invading cranial nerves IX X XI and XII The jugular vein was

---

Submitted for publication 6 June 1980

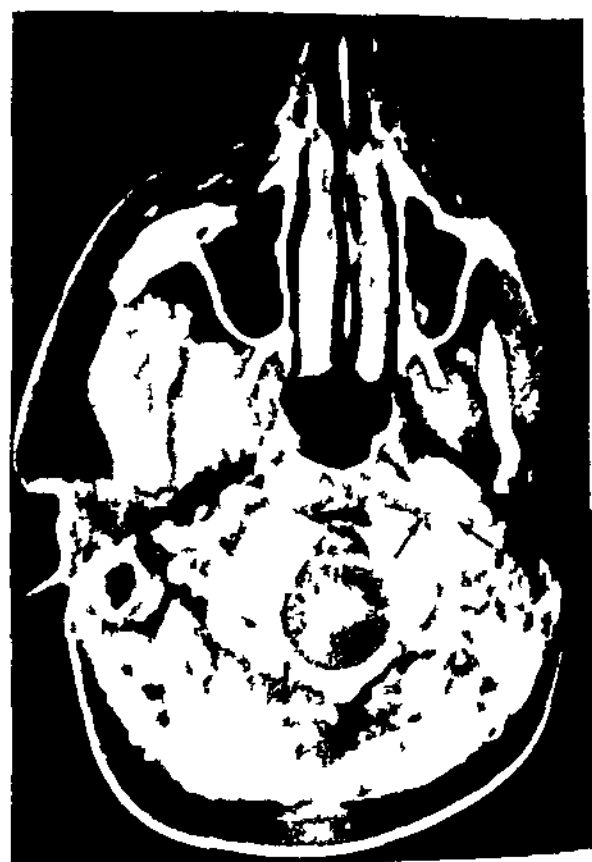
ligated in the neck well below the tumor and the neoplasm carefully dissected from the internal carotid artery Using the method described by MISCHKE & BALKANY (1980) a mastoidectomy was performed and an approach to the jugular bulb was made through the retrofacial air cells The lateral half of the jugular canal was excised with a burr under microscopy and the infratemporal portion of the tumor removed following transsection and obliteration of the sigmoid sinus The superior aspect of the tumor was attached to the dura in the posterior fossa The resection of the uppermost portion of the neoplasm resulted in an opening into the posterior cranial fossa This was plugged with a bolus of Oxycel cotton and the wound closed The pathologic diagnosis was malignant chemodectoma The tumor was metastatic to adjacent lymph nodes and the stylohyoid muscle

Postoperative course The patient was discharged on the fifth postoperative day but had to be re admitted 3 days later when he developed a profuse CSF leak through the postauricular incision This stopped uneventfully with in 36 hours and the patient was discharged 5 days later The patient underwent a full course of radiation therapy and is doing well

Video dilution technique

Video dilution technique utilizes contrast medium as an indicator for obtaining dilution curves re corded on a video cassette during fluoroscopy The technique has been developed in a hydrodynamic flow model (LANTZ 1974 1975) and thoroughly tested in animal experiments and compared with electromagnetic flow readings (LANTZ et coll 1979 1980b c d LINK et coll) In the present patient blood flow determination was performed on stand ard angiographic equipment during fluoroscopy with fixed kV and mA A 3 phase generator and a cesium iodide image intensifier (6 10" 15 cm 25 cm) were used The fluoroscopic images were re corded on a ¾ (1 9 cm) Sony Umatic video cassette recorder

After injection of contrast medium at 2 different sites (LANTZ 1974 1975) of the circulation den sitometric dilution curves of the injections may be obtained at any site distal to the injections The densitometric curves were retrieved by a videoden sitometer (T Strand Siemens Elema Sweden) with an output voltage proportional to the logarithm of the incident radiation The curves were obtained by replaying the video tape after the angiography was performed Integration of the area A under the curves was done by planimetry The integrated den sitometric areas (A_1 A_2) recorded at the same




a



b

Fig 1 CT of the superior and mid-cervical regions (Courtesy of Dr B Steed Calgary General Hospital Canada) a) An iso-at tenuating mass (→) anterior and to the left of the body of C1 b) Contrast enhancement The mass (→) is more evident displacing the internal carotid artery (↔) anteriorly



g. ? Angiographic procedures of the left neck (subtraction) a) gular phlebography (lateral view) Compression of the internal gular vein from the level of the jugular bulb caudally towards e level of the mandibular angle (→) External jugular collaterals) (Courtesy of Dr B Steed Calgary General Hospital Canada) b) Common carotid angiography (lateral view) Anterior bowing without invasion of the internal carotid artery (→) early filling of tumor vessels (↔) c) External carotid angiography (lateral view) Prominent ascending pharyngeal artery (→) supplying the majority of the tumor

wnstream site are inversely proportional to the ws at the site of injections If the injected amount contrast medium (M_1 M_2) is known the flows at e site of injection (Q_1 Q_2) can be calculated according to LANTZ (1974 1975)

$$\frac{Q_1}{Q_2}=\frac{M_1 \times A}{M_2 \times A_1}$$

Three recording positions are required to compare e relative flow as a fraction of the cardiac output in e carotid arteries bilaterally In each position the uoroscopic field has to be constant regarding the osition of the patient and the image intensifier lso the incident radiation has to be locked

Position 1 The tip of the cerebral catheter (5 5 rench without side holes) was placed under uoroscopic control in the ascending aorta The image intensifier was centered in the midline covering he origin of the innominate artery and the left common carotid artery (Figs 5 6) The image intensifier as locked using the 10" (25 cm) input

Step 1 During constant fluoroscopy and with the atient holding his breath 30 ml of Conray 60 was njected through the catheter into the ascending aorta and the video image was recorded on video tape

Step 2 The catheter was placed with the tip in the left common carotid artery (Fig 5 B) Injection of 1 ml contrast medium was now recorded in the same way on video tape

Step 3 The tip of the catheter was placed in the right common carotid artery (Fig 6 B) Another injection of 1 ml medium was performed and recorded on tape

Position 2 The image intensifier (6 15 cm input) was centered and locked over the right common carotid artery now including the internal and external carotid arteries (Fig 7)

Step 1 With the catheter already in the right common carotid artery injection of 1 ml contrast medium was performed and recorded (Fig 7 A)

Step 2 The tip of the catheter was now placed well within the external carotid artery One ml of medium was injected and recorded (Fig 7 B)

Position 3 The catheter was placed with the tip in the left common carotid artery The image intensifier was centered and locked over the left common carotid artery with the fluoroscopic field including the external and internal carotid arteries as in position 2 (Fig 8)

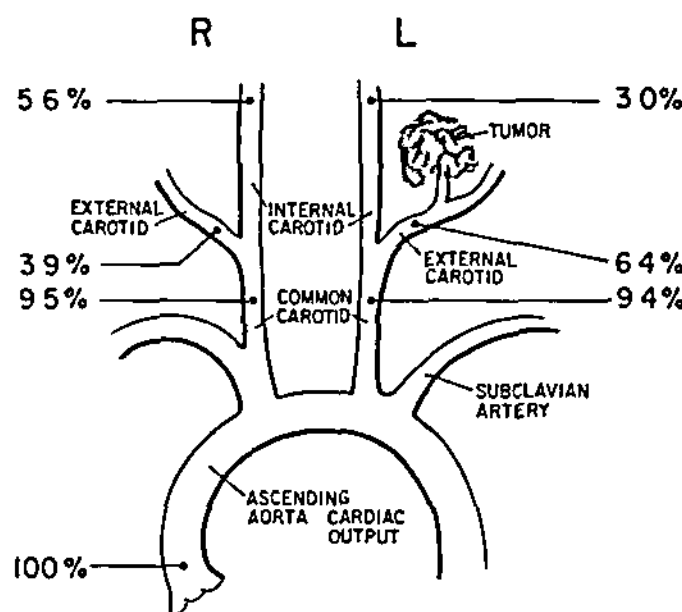


Fig 3 Distribution of blood flow in the extracranial cerebral circulation determined by video dilution technique




Fig 4 Selective left ascending pharyngeal angiography (subtraction) a) Before embolization Late arterial phase (lateral view) Prominent feeding vessels to the tumor b) After embolization Late arterial phase Multiple occlusions by Ivalon pellets of the feeding vessels (→) to the tumor

Step 1 One ml of contrast medium was injected and recorded (Fig 8 A)

Step 2 The tip of the catheter was placed well within the left external carotid Another 1 ml of medium was injected and recorded (Fig 8 B)

The blood flow in the carotid arteries as a fraction of the cardiac output was determined by replaying the video tape and positioning of the videodensitometric window over the carotid arteries bilaterally

Left common carotid flow While replaying the tape the videodensitometric window was placed over a cross section of the left common carotid artery The aortic injection of 30 ml was recorded and the integrated densitometric area (A=110) in arbitrary units was obtained (Fig 5 A) With the videodensitometric window in the same position the injection of 1 ml of contrast medium into the left common carotid artery was recorded giving another integrated densitometric area (A=39 Fig 5 B) According to the equation the flow ratio of the left common carotid Q_{LC} as a fraction of the cardiac output CO would then be

$$\frac{Q_{LC}}{Q_{CO}} = \frac{M_{LC} \times A_{CO}}{M_{CO} \times A_{LC}}$$

or

$$\frac{Q_{LC}}{Q_{CO}} = \frac{1 \times 110}{30 \times 39} = 0\ 094 \text{ or } 9\ 4 \text{ per cent}$$

Right common carotid flow Similarly the videodensitometric window was positioned over a cross section of the right common carotid artery

The blood flow in the right common carotid artery was determined comparing the integrated densitometric area from the injection of 30 ml into the ascending aorta (Fig 6 A) with the corresponding

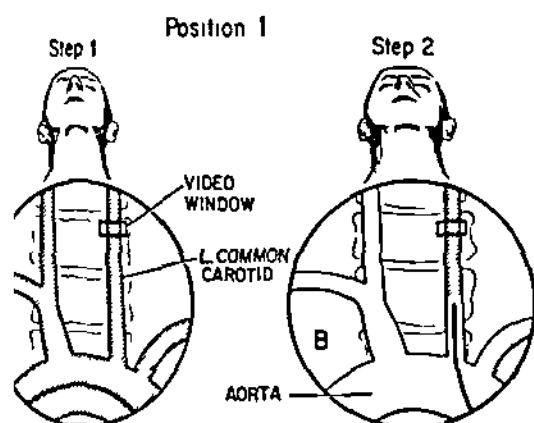
---

Fig 5 Densitometric recording over the left common carotid artery after injection of 30 ml of contrast medium into the ascending aorta (Step 1) and 1 ml into the common carotid artery (Step 2) The integrated densitometric area from the aortic injection (A) was 110 arbitrary units and from the selective injection of the left common carotid artery (B) 39 The blood flow in the common carotid artery was 9 4 per cent of the cardiac output

Fig 6 Determination of blood flow in right common carotid artery compared with cardiac output The integrated area under the densitometric curve from aortic injection of 30 ml (A) recorded over the common carotid artery was 143 in arbitrary units (Step 1) Corresponding integrated area from selective injection of 1 ml (B) into the right common carotid artery was 50 (Step 3) Blood flow in the right common carotid artery was 9 5 per cent of the cardiac output

Fig 7 The integrated area under the densitometric curve (A) after injection of 1 ml contrast medium into the common carotid artery was 31 in arbitrary units (Step 1) The corresponding area (B) after injection of 1 ml into the right external carotid artery was 75 (Step 2) Blood flow in the right external carotid artery as a fraction of the right common carotid artery flow was 41 3 per cent

Fig 8 The integrated area under the densitometric curve after injection of 1 ml (A) into the left common carotid artery was 77 in arbitrary units (Step 1) The corresponding area after the same amount injected into the left external carotid artery (B) was 113 (Step 2) Blood flow in the left external carotid artery was 68 per cent of the flow in the left common carotid artery



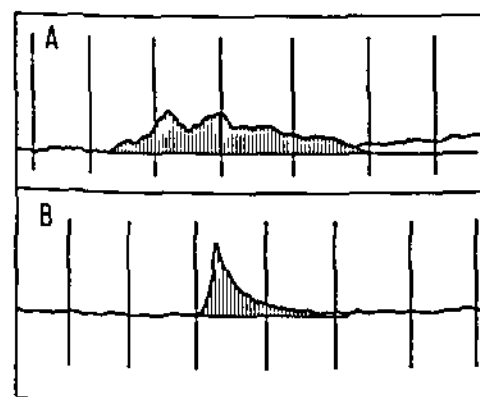


Fig 5

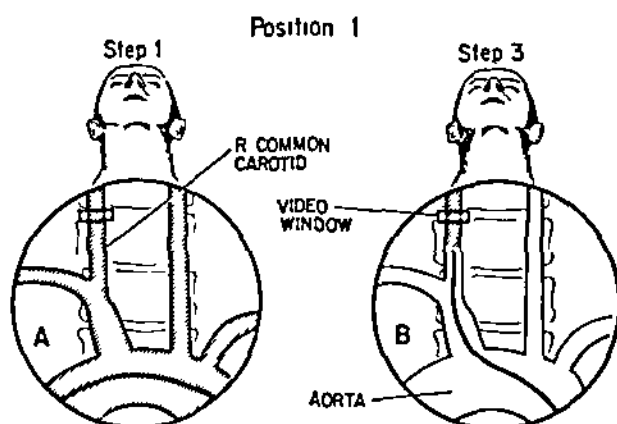
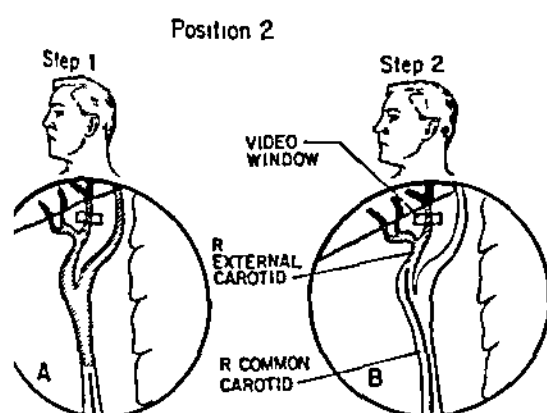




Fig 6



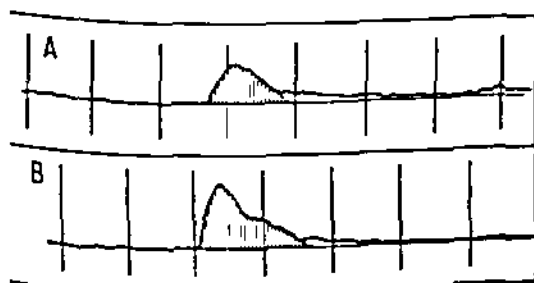
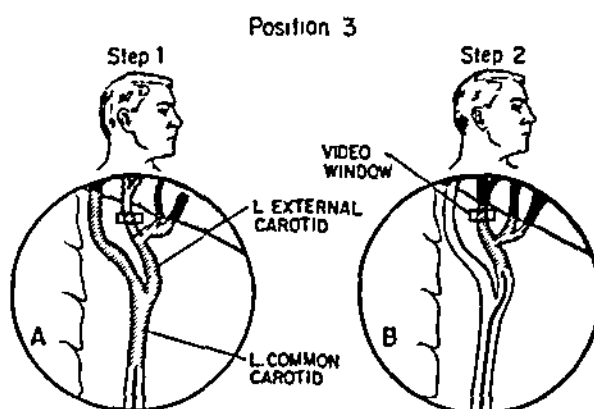


Fig 7



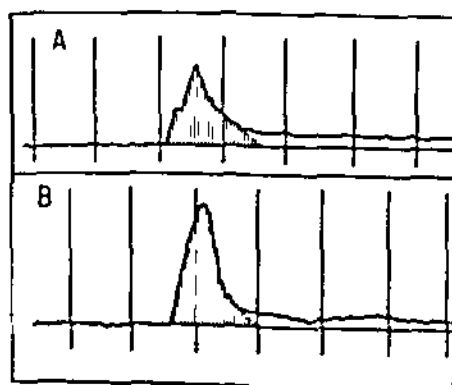


Fig 8

legends see opposite page)

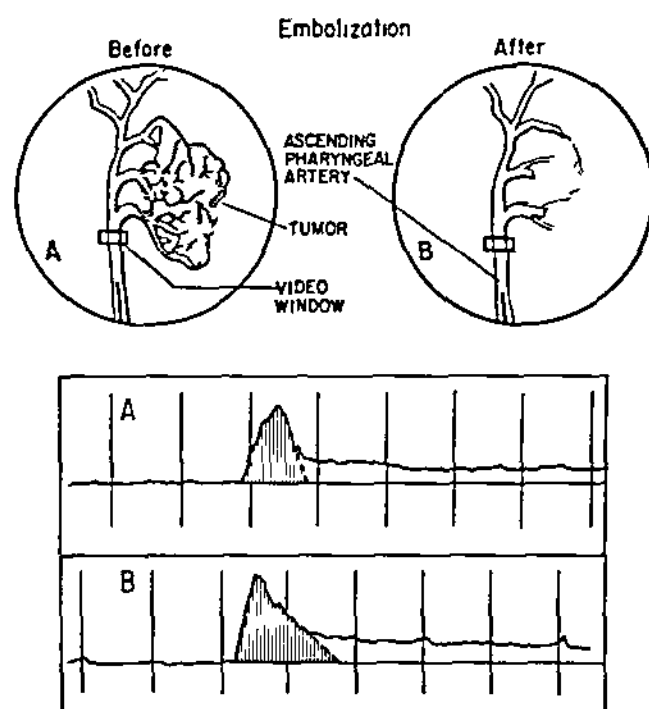


Fig 9 Selective catheterization of the left ascending pharyngeal artery One ml contrast medium before embolization (A) gave an integrated area under the densitometric curve of 62 in arbitrary units After partial embolization (B) with Ivalon pellets a repeat injection of 1 ml gave an integrated area of 92 corresponding to a decrease of flow by 33 per cent compared with the baseline flow

integrated area from the selective injection of 1 ml into the right common carotid artery (Fig 6 B)

$$\frac{Q_{RC}}{Q_{CO}}=\frac{1\times143}{30\times50}=0\ 095 \text{ or } 9\ 5 \text{ per cent}$$

Thus the blood flow in the right common carotid artery was 9 5 per cent of the cardiac output (flow in ascending aorta)

Right external carotid flow The densitometric areas obtained in position 2 is a comparison of the flow in the right common carotid artery (Fig 7 A) with the flow in the right external carotid artery (Fig 7 B)

$$\frac{Q_{RE}}{Q_{RC}}=\frac{1\times31}{1\times75}=0\ 413 \text{ or } 41\ 3 \text{ per cent}$$

Using similar calculations the flow in the external carotid artery corresponds to 3 9 per cent of the cardiac output (41 3/100×9 5)

Left external carotid flow The integrated areas from injections into the left common carotid artery (Fig 8 A) and the left external carotid artery (Fig 8 B) revealed the following flow ratio between the external and common carotid

$$\frac{Q_{LE}}{Q_{LC}}=\frac{1\times77}{1\times113}=0\ 681 \text{ or } 68 \text{ per cent}$$

Again calculating the left external carotid flow co responds to 6 4 per cent of the cardiac output (6 100×9 4)

Embolization effect One ml contrast medium w injected selectively into the left ascend pharyngeal artery before (Fig 9 A) and after (Fig B) embolization The ratio of the flow after/befo embolization was

$$\frac{Q_A}{Q_B}=\frac{1\times62}{1\times92}=0\ 67 \text{ or } 67 \text{ per cent}$$

Thus the embolization procedure caused a decre of flow in the ascending pharyngeal artery by 33 cent compared with the baseline flow

Discussion

Chemodectomas (non chromaffin paraga liomas) are generally benign tumors involvin variety of structures from the carotid body to jugular bulb (NEWTON 1974) Occasionally they malignant with regional invasive metastases Che dectomas arising from the carotid body classic displace internal and external carotid arteries w out direct invasion Arteriovenous shunting is quently present This latter fact coincides with results of flow determinations Invasion or displ ment of venous structures particularly wh n neoplasm involves the jugular region is freq (Fig 2 a) Intracranial extension of glomus jugu tumors may occur In the present case such ex sion was only slight probably explaining the tively intact osseous structures of the jugular as evidenced on conventional skull films and CT

Besides the localization character and exten the tumor obtained from the radiologic exam tions blood flow determination by video dilu technique performed in connection with the an graphy added valuable information for the treatm of the patient First the increased flow to the tu could be quantified Secondly the effect of the bolization was determined and thirdly the through the contralateral internal carotid artery considered normal This latter fact was espec

important in the event a complete excision of the ipsilateral internal carotid artery had to be undertaken. The increase of flow to the external carotid artery was expected as a highly vascular tumor with arteriovenous shunting decreases the peripheral resistance considerably. However, the corresponding decrease of flow in the left internal carotid artery together with normal flow in the common carotid artery was a surprise. An increase of the common carotid artery flow would have been expected as in cases with peripheral arteriovenous fistulae (LANTZ et coll. 1979). Displacement and compression of the left internal carotid artery by the tumor might partially explain the decreased blood flow in this vessel. However, to some extent the altered distribution of flow from the internal to the external carotid artery seems to be a steal by the highly vascular tumor.

Video dilution technique for determination of relative blood flow in single arteries is easy to perform, fast and highly accurate. The technique has been developed in a hydrodynamic flow model and thoroughly tested in more than 600 individual experiments in 40 dogs and compared with electromagnetic flow readings (r=0.99, mean error <2%).

Standard angiographic equipment is used with the addition of a videodensitometer, a video tape recorder and a photographic recorder for documentation of the dilution curves. A 3 phase generator is preferable to avoid single phase ripple on the densitometer curves. The generator should also provide a key to lock the fluoroscopic radiation intensity during recordings.

Video dilution technique does not add any significant risks or costs to the patient. The blood flow determination does not usually prolong the catheterization time as it can be performed while the examiner is waiting for the serial films to be developed. The additional radiation exposure and contrast medium required to conduct the flow determination is also neglectable. In the present case less than 70 seconds of fluoroscopy was used for the video dilution technique giving a total absorbed dose of 11 mGy (bone marrow=0.11 mGy/70 s). Only ½ ml of Conray 60 was used which is a small fraction of the recommended maximum. All recordings were performed within 10 min.

The disadvantage of the technique seems to be limited to the patient's ability to cooperate, i.e. to lie still on the angiographic table. A detailed analysis of different aspects of the application of video dilution technique has previously been published (LANTZ et coll. 1979, 1980b, c, d, LINK et coll.). However, some practical advise from clinical experience with regard to the technique will be briefly mentioned here.

The position of the patient and the image intensifier has to be stationary during 2 consecutive recordings for comparison. It is an advantage if the patient can hold his breath during the injection of contrast medium to avoid respiratory fluctuations of the densitometric baseline. The accuracy of the amount of injected contrast medium is critical. Before each injection the catheter has to be filled with contrast medium. It is also important that the pressure injector used for the aortic injection is delivering the programmed amount correctly. Also great care has to be taken to ensure that the manual injection of one ml is delivered adequately. A one ml tuberculin syringe was successfully used in both animal model and in humans.

The effect of ionic iodine contrast media on the circulation is well known. Increase of regional blood flow after the first injection has to be considered. Baseline flow is usually re-established within 2 min. It is recommended to wait at least this period of time before the second injection and also after each filling of the catheter. A complete mixing of contrast medium with the blood is not anticipated with the selective injections. This does not seem to be of great importance since the window measures the total amount of contrast medium over an arterial cross section rather than local concentrations of medium within the vessel. However, it is advisable to keep a distance of at least 2 cm between the tip of the catheter and the recording video window to give the contrast medium a chance to mix with the blood. When comparing 2 flows in relative measure, the videodensitometric window has to be in the same position over the same arterial cross section. The size of the window and the densitometer gains have to be unchanged during the two consecutive recordings.

Video dilution technique is now employed on almost all patients referred to this radiologic department for angiography. An evaluation of normal flow rates is continuing, and significant deviations are correlated to different pathologic conditions. It is anticipated that video dilution will give valuable information of hemodynamics in most areas of the circulation which is not presently availably by any other means.

SUMMARY

Cerebral angiography performed on a patient with a preliminary diagnosis of jugular foramen syndrome revealed a highly vascular malignant chemodectoma supplied mainly by the left ascending pharyngeal artery Blood flow was determined during angiography in the extracranial branches of the carotid arteries by video dilution technique The decrease of blood flow after partial embolization of the left ascending pharyngeal artery was also quantified The application and value of video dilution technique in blood flow determination together with the angiographic findings are discussed

REFERENCES

LANTZ B M T A methodologic investigation of roentgen videodensitometric measurement of relative flow University of California Press Davis 1974

— Relative flow measured by roentgen videodensitometry in hydrodynamic model Acta radiol Diagnosis 16 (1975) 503

— DUBLIN A B MCGAHAN J P and LINK D P (a) Assessment of cerebral blood flow in man by video dilution technique A preliminary report Invest Radiol (in press)

— — FOERSTER J M LINK D P and HOLCROFT J W (b) Angiographic determination of cerebral blood flow Acta radiol Diagnosis 21 (1980) 147

— — — — (c) Determination of relative blood flow in single arteries New video dilution technique Amer J Roentgenol 134 (1980) 1161

— LINK D P FOERSTER J M and HOLCROFT J W (d) Angiographic determination of splanchnic blood flow Acta radiol Diagnosis 21 (1980) 3

— HOLCROFT J W FOERSTER J M LINK D P and REID M H Determination of blood flow through arteriovenous fistulae and shunts Acta radiol Diagnosis 20 (1979) 727

LINK D P LANTZ B M T FOERSTER J M HOLCROFT J W and REID M H New videodensitometric method for measuring renal artery blood flow at routine arteriography Validation in the canine model Invest Radiol 14 (1979) 465

MISCHKE R E and BALKANY T J Skull base approach of glomus jugulare Laryngoscope 90 (1980) 89

NEWTON T H Abnormal external carotid artery *In* Radiology of the skull and brain Volume 2 book ? p 1275 Edited by T H Newton and D G Potts C V Mosby Company St Louis 1974

FROM THE DEPARTMENTS OF DIAGNOSTIC RADIOLOGY, UNIVERSITY HOSPITAL, S-221 85 LUND, SWEDEN, AND UNIVERSITY HOSPITAL HAUKELAND SYKEHUS, N-5016 BERGEN, NORWAY

ASCENDING LUMBAR VEINS

Catheterization technique and radiographic anatomy

L. FORSBERG and J. GÖTHLIN

Features of the ascending lumbar vein (ALV) system have been reported by DUX et coll. (1968 b) and DUX (1975). In 1971 BUCHELER described normal and pathologic aspects of ascending lumbar phlebography. These authors evaluated the ascending lumbar veins in patients with wide spread malignant disease. The present investigation was performed in order to elucidate the normal anatomy (Figs 1–2) and possible diagnostic use of ALV phlebography. The examinations were performed as recommended by DUX et coll. (1968 a).

Material and Methods

Thirty nine men and two women, aged 16 to 84 years, were examined on possible paravertebral or retroperitoneal involvement by malignant disease. No such involvement was found at autopsy, operation or in the clinical course. A further 15 patients were found to have intra abdominal or intra thoracic tumour growth that could not be related to findings in the ALV system.

The femoral veins were catheterized percutaneously using catheters with ID/OD=1.14/1.58 mm, length 60 cm. Different curves of the tip were tested, the optimum shapes proving to be as in Fig. 3. End holes only, or 1 to 4 side holes close to the tip were used. Test injections by hand served to establish the position of the catheter tip and the gross venous anatomy. For the phlebography the injection rate varied between 8 and 20 ml/s and the amount of contrast medium (Isopaque Coronar, Nyegaard A/S, Norway) was between 15 and 40 ml. Using an AOT film changer, 8 films were exposed per 8 seconds with the patient supine and during Valsalva's manoeuvre to decrease the flow of contrast medium into the inferior vena cava. A.p. projections were obtained in all patients and additional lateral projections in 30 cases.

In most patients the left ALV was first catheterized at its origin from the common iliac vein. If the attempt was not successful, veins originating from the internal iliac veins were catheterized or lumbar veins from the inferior vena cava (Fig. 6). A few times veins in the presacral plexus were catheterized. In 7 patients adequate filling was obtained of both ALV at catheterization of the left ALV but in most cases the right ALV also had to be catheterized directly (Fig. 4) or, fairly often, from an ileo-lumbar vein.

The tip of the catheter was positioned at varying heights in the ALV to find an optimum position, preferably above a wide lumbar vein originating from the trunk.

Results

The optimum amount of contrast medium proved to be 40 ml injected at a rate of 5 to 8 ml/s. In 48

Submitted for publication 27 September 1979.

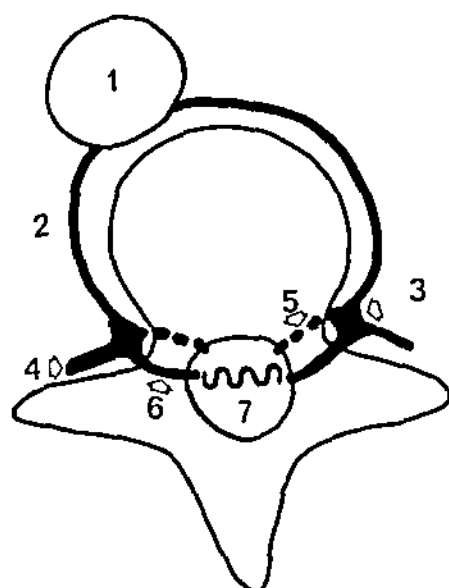


Fig 1 Normal anatomy 1=inferior vena cava 2=Lumbar vein 3=Ascending lumbar vein 4=Distal part of lumbar vein 5=Infrapedicular vein 6=Suprapedicular vein 7=Epidural vein

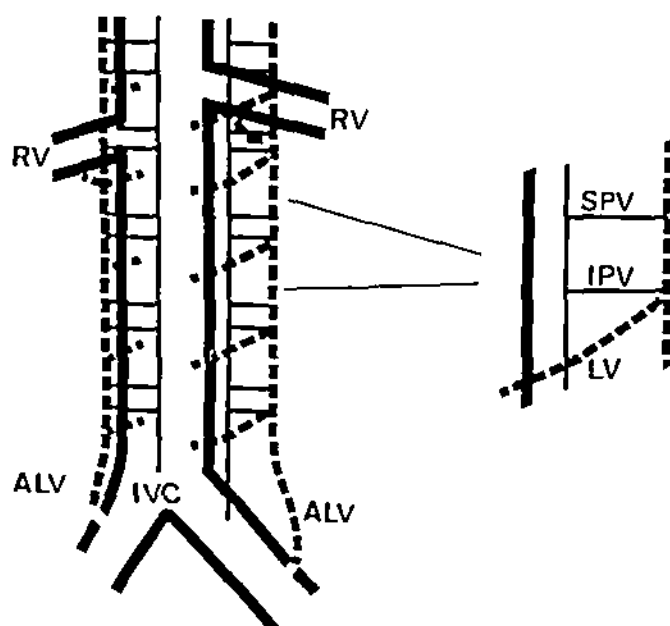


Fig 2 Normal anatomy IVC=Inferior vena cava ALV=Ascending lumbar vein RV=Renal vein LV=Lumbar vein (corresponds to the lumbar arteries) SPV=Suprapedicular vein IPV=Infrapedicular vein

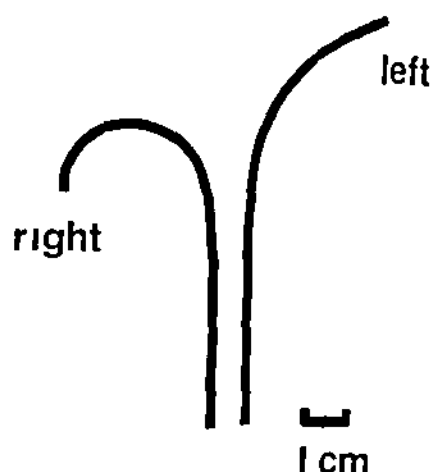


Fig 3 Catheters bended for catheterization of right an ascending lumbar veins

Table 1

Catheterized veins and vein combinations in 56 patient

		Left	Right	Bilat
ALV only		[illegible]	3	17
Lumbar veins only	[illegible]			
ALV+lumbar vein	11			
Azygos vein	1			

Two lumbar veins catheterized in one patient

Table 2

Number of levels of interrupted or inadequately filled ALV in 41 patients examined with acceptable technique

	Left ALV	Right ALV
One level	14	9
Two levels	5	12
Three levels	5	7
≥Four levels	1	8

patients the left ALV was catheterized and in 27 the right Directly from the inferior vena cava 14 lumbar veins were catheterized The veins or combinations of veins catheterized are presented in Table 1 In 27 patients only one catheter was introduced in 22 two catheters and in 6 further patients catheters were placed in three different positions

Adequate filling of ALV bilaterally at injection of the left ALV was obtained in 7 patients No fillir ALV on one side was obtained in 7 of 56 patie mainly due to catheterization difficulties

The filling of the ALV or parts of it was alv improved when contrast medium was injected the lumbar veins

Of 41 patients with optimum catheterization c ditions a continuous ALV trunk existed on the



Fig 4 Normal ascending lumbar phlebography with continuous trunk on left side Catheterization of both ascending lumbar veins with simultaneous injection

side in 15 on the right side in 4 and bilaterally in 2 patients Some or marked narrowing or interruption of venous trunks was found at the level of the lumbar veins in 92 sites (Fig 7) at the level of the suprapedicular vein in 45 sites and at the infrapedicular vein in 41 Collaterals always filled between right and left ALV and epidural veins as well as presacral plexus Numerous interrupted or inadequately filled veins on each side were found in these 41 patients (Table 2) Anastomosis between the ascending lumbar vein and the renal vein on the left side was found in 14 of 41 patients One patient had bilateral anastomoses Lumbar veins were demonstrated in 43 of 47 patients

In 8 of 43 patients lumbar veins had an aberrant course (Fig 5) The vein in 2 cases also anastomosed with the lumbar vein at the adjacent level (Fig 5 b c) where the veins emptied at one level above or below the expexted one Five veins were directed upwards and 3 downwards All 8 veins originated from the left ALV

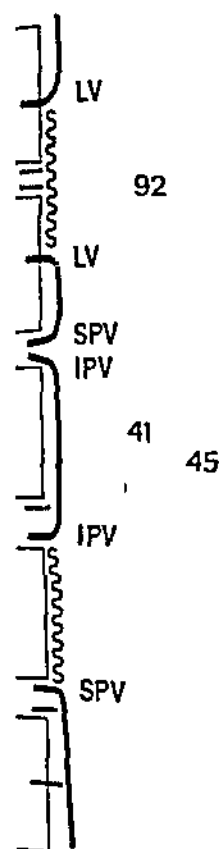
No difference was encountered in the phlebographic result whether catheters with end holes only or side holes were used

a b c

Fig 5 Lumbar veins with aberrant course in two patients Contrast medium injected into right ascending lumbar vein Aberrant course in a) level L3 to L4 in b) and c) level L3 to L2 Anastomosis to left renal vein in (a)

a b c

Fig 6 Improved filling of ascending lumbar veins with injection of contrast medium into different lumbar veins as well Small extravasation in (a) at L5 Numerous interruptions and plexus formations as well as displacement of veins due to spondylosis



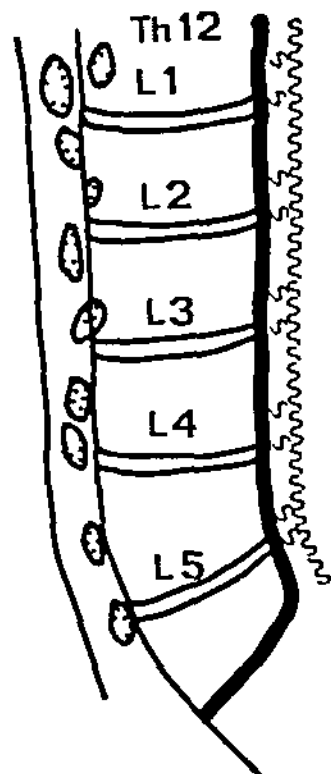


Fig 7 Fig 8

Fig 7 Different localizations of interruptions at level of lumbar and pedicular veins

Fig 8 Paraaortic lymph nodes in relation to inferior vena cava and paravertebral venous system

Extravasation occurred in 3 patients In 2 of these the catheter was placed in the left ALV with the tip at L5 and in one the tip of the catheter was placed in a left lumbar vein at L3

Discussion

In the present series 40 ml of contrast medium was found to be sufficient for filling the ALV system Larger amounts did not increase the information 30 to 40 ml were used by DUX et coll (1968b) BOCZON (1976) and GERSHATER & HOLGATE (1976)

The optimum rate of injection was found to be 5 to 8 ml/s which is in accordance with the recommendations of BOUCZON and GERSHATER & HOLGATE Higher injection rates only forced the contrast medium out into the inferior vena cava giving less information of the ALV system

Contrary to the findings of BUCHELER in the present series only rarely was good bilateral filling of both ALV obtained when injecting the left side (7 of 56 patients) The reason for this is not clear Increasing the injection rate only tended to divert contrast medium into the inferior vena cava

It was difficult to obtain an adequate degree of filling of the ALV if the tip of the catheter was not at least as high as L5 on the right side and L4 on the left mainly due to a steal phenomenon by large lumbar veins

In case of suboptimum filling or at apparent interruptions of the ALV trunk selective catheterization of a corresponding lumbar vein always enhanced the filling The increased local pressure caused by the injection of contrast medium could surpass the normal haemodynamics and fill parts of the ALV system fed from collaterals when blood was diverted from the vein

Interrupted filling of venous trunks without a plexus formation in the ALV was not uncommon This can be due to diversion of contrast medium into collaterals but anatomic discontinuity could not be excluded in these cases Continuous ALV trunks were surprisingly uncommon (16 of 41 patients) In Table 2 the frequency of interrupted filling at various levels is specified

Most lumbar vein openings were fairly easy to catheterize directly from the inferior vena cava They arose at the level of the lower or intermediate part of the vertebral body on the dorsal wall of the vena cava These veins also tended to form plexus which might enhance the risk of extravasation when catheterized Selective catheterization enhanced the filling of not only the ALV but also that of the epidural plexus which may be of benefit in diagnosing disc herniations spinal stenoses etc

This investigation was partly performed to find out whether ascending lumbar phlebography could add any information in patients with malignant disease as has been suggested by DUX and BUCHELER The main bulk of abdominal lymph nodes is situated ventral to the psoas musculature while the ALV are embedded deep in the musculature (Fig 8) Metastases in the lymph nodes or primary neoplasms in the retroperitoneum have to grow through the musculature before compression of the ALV is to be expected Thus the lesions must be large before they can affect the vein On the right side impressions in the vena cava may occur at an earlier stage The region of interest in diagnosing growth from a neoplasm in the stomach or pancreas is the region of Th12 to L1 Of 41 patients without involvement of ALV at autopsy non filling of ALV

trunks was obtained in this region in 15 patients on the right side and in 6 on the left. Furthermore plexiform vessels normally encountered in this region can sometimes be erroneously considered as collaterals due to obstruction.

The abundant anatomic variations and inconsistent results of phlebography renders the possibility of diagnosing malignant lesions too small to justify the use of ascending lumbar phlebography with the technique described for determining the extent of expanding lesions originating in the abdomen or retroperitoneal region.

SUMMARY

The normal anatomy of the ascending lumbar veins and a catheterization technique used to demonstrate these veins at phlebography are reported. The use of this examination when dealing with malignant disease in the abdomen and retroperitoneal region is not warranted on account of the wide range of anatomic and phlebographic variation.

REFERENCES

BOCZON S. Phlebography of lumbar spine area. Technique of investigations and anatomy. (In Polish with English summary.) Pol Przegl radiol 40 (19 6) 171.

BUCHELER E. Die direkte Angiographie des Vertebralplexus der lumbalen Venen und des Azygosvenensystems. *In* Ergebnisse der medizinischen Radiologie Band III, p. 1. Edited by E. Bucheler, D. Puppe and H. Schreyer. Georg Thieme, Stuttgart 1971.

— DUX A. und SOBBE A. Die reno lumbale Anastomose im direkten retroperitonealen Veno- und selektiven Azygogrammen. Fortschr Rontgenstr 109 (1968) 71.

DUX A. Cavography and retroperitoneal venography in the preoperative diagnosis of pancreatic disease. *In* Efficiency and limits of radiologic examination of the pancreas, p. 124. Edited by H. Anacker. Georg Thieme, Stuttgart 1975.

— BUCHELER E. und SOBBE A. (a) Die kombinierte retroperitoneale Veno- und Cavographie. Methode, Indikation und Ergebnisse. Rontgenblatter 21 (1968) 495.

— — BARTSCH W. und SOBBE A. (b) Die direkte lumbale Venographie bei Magentumoren. Fortschr Rontgenstr 109 (1968) 1.

GERSHATER R. and HOLGATE R. C. Lumbar epidural venography in the diagnosis of disc herniations. Amer J Roentgenol 126 (1976) 992.

ROLAND J., LARDE D., MASSON J. P. et PICARD L. Les veines lombaires epidurales. J Radiol Electrol (1977) 35.

FROM THE DEPARTMENT OF DIAGNOSTIC RADIOLOGY UNIVERSITY HOSPITAL S 22185 LUND AND THE DIVISION OF ORGANIC CHEMISTRY I CHEMICAL CENTER UNIVERSITY OF LUND S 22007 LUND SWEDEN

ELECTROLYTIC DESTRUCTION OF LUNG TISSUE

Electrochemical aspects

L. SAMUELSSON and L. JÖNSSON

Destructive lesions have been made in the lungs of rabbits (SAMUELSSON & OLIN 1977) and pigs (SAMUELSSON & JÖNSSON 1981) by electrolysis at small platinum electrodes inserted percutaneously. The purpose has been to create a method for percutaneous destruction of lung metastases in humans. An electrochemical analysis of the process has now been made to provide a basis for further development of the method. Evidence is presented in support of the assumption that chlorine is the principal destructive agent liberated at the anode during tissue electrolysis. The chlorine yield at the anode has been determined in physiologic saline solution at various current densities and the anodic potential measured at various currents through the solution (anodic voltammogram). Analyses have also been made to explain the colour of the electrolytic lung lesions, and an attempt made to explain the cause of conductivity problems that often arise during electrolysis in animal lungs. In addition palladium has been tested as an alternative to platinum as the electrode material. Platinum compound allergy is known and could limit the use of the method while the risk with palladium is much smaller (SAX 1975).

Material and Method

Direct current has been used in all experiments. The electrolytic dose is expressed in Coulomb (C).

Determinations of organically bound chlorine (covalently bonded chlorine) were made by the Schöniger elementary analysis in samples of normal tissue and electrolytic lesions from pig lungs. Inorganic chlorine is washed out during this procedure. The material is then burnt and chlorine determined as chloride (SKOOG & WEST 1969).

The electrolytic process was analysed in model experiments. Direct current was passed between bullet shaped platinum electrodes (surface area 80 mm²) placed about 20 mm apart in a Petri dish containing fresh human blood. In a number of similar experiments platinum and palladium foil electrodes were used.

After electrolysis in blood, material was taken from the vicinity of the anode and cathode and analysed to determine the origin of the changes in the colour of the blood. The black and brown materials were digested by papain at 60°C. The mixture was filtered and the residue was dissolved in pyridine 0.1 mol/l sodium hydroxide solution (1:3). Following reduction by the addition of sodium dithionite, the spectrum of this solution was recorded in the range 500 to 600 nm (GARDELL 1980).

The yield of chlorine evolved from anodic oxidation in physiologic saline solution was determined at various current densities in a gas tight cell with platinum foil electrodes (Fig. 1). The charge applied to the solution was 100 C. The chlorine liberated was forced out of the anodic compartment by nitrogen gas and passed through potassium iodide solution. The iodine formed through oxidation by

Submitted for publication 10 March 1980

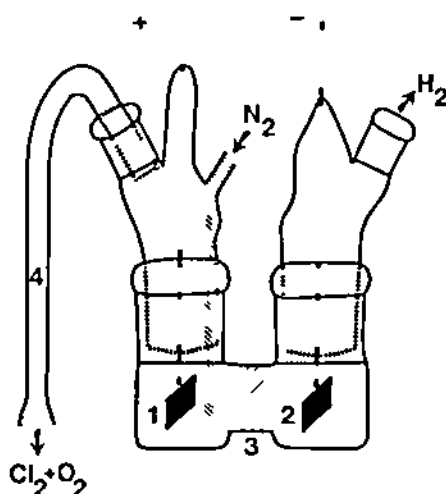


Fig 1 Gas tight cell with platinum foil electrodes (1 and 2) for determination of the chlorine yield at various current densities during electrolysis in physiologic saline solution Anode area 204 mm² A glass frit (3) separated the anodic and cathodic compartments A nitrogen gas stream through the anodic compartment brought the liberated chlorine through a glass tube (4) to a bottle with potassium iodide solution

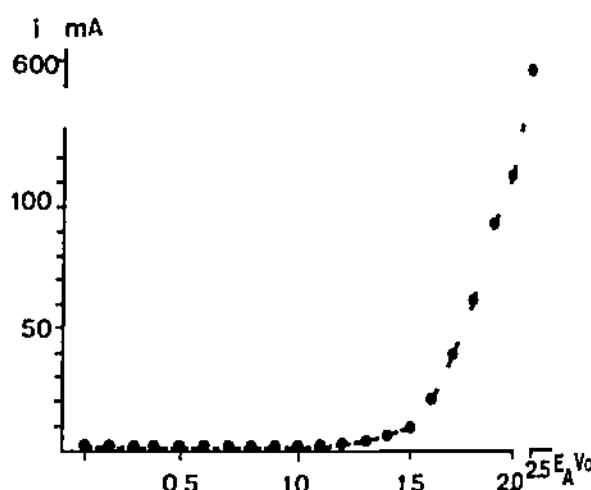


Fig 2 Anodic voltammogram i=current in mA E_A=potential V at the anodic surface At an anodic potential of about 1 5 current started to pass through the physiologic saline soluti between the platinum electrodes When the potential was rais further the current swiftly became stronger

chlorine was then determined by iodometrical titration

The anodic voltammogram (the current/anode potential curve) was based on measurements made in physiologic saline at a platinum foil electrode by a calomel reference electrode (Radiometer Copenhagen) coupled to an ordinary potentiostate (Amel 552) The potential between anode and electrolyte was slowly elevated until current started to pass through the solution The reference electrode was placed very close to the anodic surface to measure the potential step there which is an important electrochemical parameter (DAVIES 1968)

Results

The determinations of organically bound chlorine showed that the chlorine content was elevated in fresh lesions as compared with fresh tissue (Table 1) No such difference was found in a lung with a lesion that was 4 weeks old Lesions made with the anode well separated from the cathode had a higher chlorine content than those made with the anode and cathode close together The chlorine yield from electrolysis in physiologic saline reached a maximum of 50 per cent at a current density of 40 mA/cm (Table 2) At higher current densities the yield gradually became smaller Current started to pass through physiologic saline solution at an anodic potential of about 1 5 V (Fig 2)

During electrolysis in fresh human blood bubbling of hydrogen was evident at the cathode whe sodium hydroxide was formed and the colour of tl blood changed to brown At the anode only fai liberation of gas occurred and the blood there b came black The pH reaction was strongly acid the anode and strongly alkaline at the cathode

Conductivity between the electrodes was regula ly impaired after 5 to 10 min of electrolysis at current of 20 mA It was observed that the blac

Table 1

Organically bound chlorine in the lungs of pigs following electrolysis expressed as a percentage of dry tissue weight Samples were taken from the electrolytic lesions and from normal tissue

Pig No	Lesion sample (per cent)	Normal sample (per cent)
1	6 0	0 7
2	2 5	1 3
3	5 0	1 1
4	2 8	0 4
5	2 1	0 7
6	0 6	0 7
7	7 0	1 0

Pigs 1 3 and 7 Lesions made with the anode 30 mm from the cathode
Pigs 2 4 5 and 6 Anode and cathode close together in a double electrode
4 week-old lesion made with double electrode

Table 2

Chlorine yield at different current densities i e percentage of current used to produce chlorine according to Faraday s law

Current density (mA/cm²)	Chlorine yield (per cent)
5	40
10	43
0	44
30	44
40	50
50	45
60	46
70	43
80	40
90	40
100	40
110	39
120	39
130	37

ened blood around the anode became quite dry and sticky and that the current could not then pass Good contact could immediately be restored by moistening the anode with a drop of physiologic saline solution No sign was found that conductivity was impaired around the cathode which always was well moistened A pole changer was tried to improve conductivity but in vain

Papain digestion of the material from the vicinity of the anode yielded a black residue insoluble in water It was dissolved in pyridine/sodium hydroxide solution and after reduction with sodium dithionite gave a red solution This solution showed the typical visible spectrum of haem with absorption maxima at 525 nm and an absorption minimum at 539 nm These results indicate that the black residue from the papain degradation was haematin and consequently that the black material from the anode surroundings contained methaemoglobin Material from the vicinity of the cathode gave no insoluble residue after papain digestion

Palladium electrodes performed similarly to those of platinum the blood around the anode turned black and the effect was about the same

Discussion

A clear rise in organically bound chlorine occurred in acute electrolytic lesions as compared with normal lung tissue In a 4 week old lesion this difference had disappeared These observations strongly suggest that chlorine which is a powerful oxidant is the main agent responsible for tissue destruction

When the anode and the cathode are built together in a double electrode conductivity problems are reduced but the destructive effect is much smaller In a pig lung administration of 800 C through a separate anode makes a 30 mm lesion whilst with a double electrode as much as 2000 C must be given to create a lesion 25 mm in diameter (SAMUELSSON & JÖNSSON) It is therefore significant that the chlorine content of lesions made with the electrodes placed well apart (pigs 1 3 7) is about twice as high as that in lesions made with a double electrode (pigs 2 4 5) If the cathode and anode processes mix as they do at a double electrode sodium hypochlorite is formed which chlorinates the tissue more slowly than pure chlorine

During anode electrolysis in physiologic saline 50 per cent of the current is used for chlorine production at the density of 40 mA/cm² In the body the yield is probably less for other reactions such as the oxidation of haemoglobin compete at the anode The chlorine yield is a factor worth considering when constructing electrodes They should not be too small and a surface area of at least 100 mm² is suggested for use with a current of 60 to 70 mA

Analysis of material taken from the vicinity of the anode after electrolysis in blood indicates that the black pigment is methaemoglobin The analytic principle is as follows methaemoglobin is separated into haematin and globin by papain and haematin is reduced by sodium dithionite to haem which can be identified spectrophotometrically Oxidation of haemoglobin to methaemoglobin at the anode is mainly performed by chlorine At the cathode sodium hydroxide transforms haemoglobin to haemochromogens which are black The formation of methaemoglobin and haemochromogens presumably explains the colour of anodic and cathodic electrolytic lesions in lung tissue (SAMUELSSON et coll 1980) as most of the pigmentation of the lung before electrolysis must be due to the presence of haemoglobin in the pulmonary vessels

During electrolysis water has a tendency to collect around the cathode (electro-endosmosis DIXON & SCHAFER 1966) This process may explain the observations in blood The cathode remains moist while the anode becomes dry hindering passage of

the current In experiments on animal lungs using a platinum electrode with a surface area of 80 mm^2 conductivity problems arose regularly with currents greater than 20 mA (SAMUELSSON & JÓNSSON) This was of no importance for the end result of electrolysis as normally contact was soon restored and the process could continue However the resultant changes of potential in the lung evoked muscle twitching This is disturbing in animal experiments and obviously cannot be tolerated if the method is to be used in humans Conductivity is better with the less effective double electrode and the problem can probably be overcome with more sophisticated electrode constructions Experimental results in rabbits (SAMUELSSON et coll) pigs (SAMUELSSON & JONSSON) and rats (SAMUELSSON 1981) indicate that electrolysis has a fair chance of becoming a clinically applicable method in the treatment of lung tumours Preliminary trials in humans of an almost identical method have given promising results (NORDENSTRÖM 1978)

SUMMARY

The electrochemical basis for tissue destruction by electrolysis was analysed Electrolytic lesions from pig lungs had a higher content of organically bound chlorine than normal tissue and it is suggested that chlorine liberated at the anode is the principal agent in the electrolytic destruction of tissue The electrode systems that were most effective in destroying tissue produced the lesions with the highest content of chlorine Experiments in physiologic saline established that a current density of 40 mA/cm^2 gave the best yield of chlorine

ACKNOWLEDGEMENTS

This investigation was supported by a grant from the Medical Research Council (Project No B7 8 14X-605-1? and No B79 14X-605 13A) The authors wish to thank Professor Lennart Eberson and Professor Sven Gardell Chemical Center University of Lund for generous help

REFERENCES

DAVIES C W Principles of electrolysis Second edition p 9 The Chemical Society London 1968

DIXON R J and SCHAFER F W Electro-osmosis as a demonstration experiment J chem Educat 43 (1966) 380

GARDELL S Personal communication (1980)

NORDENSTRÖM B *Preliminary clinical trials of electrophoretic ionization in the treatment of malignant tumors* IRCS Med Sci 6 (1978) 537

SAMUELSSON L Electrolysis and surgery in experimental tumours in the rat To be published in Acta radiol Diagnosis (1981)

— and JÓNSSON L Electrolytic destruction of tissue in the normal lung of the pig To be published in Acta radiol Diagnosis (1981)

— och OLIN T Elektrolytisk destruktion av lungvävnad (In Swedish) Hygiea 86 (1977) 345

— — and BERG N O Electrolytic destruction of lung tissue in the rabbit Acta radiol *Diagnosis* 21 (1980) 447

SAX I N Dangerous properties of industrial materials Fourth edition p 991 van Nostrand Reinhold Co New York 1975

SKOOG D A and WEST D M Fundamentals of analytical chemistry Second edition p 763 Holt International Edition London 1969

FROM THE DEPARTMENTS OF DIAGNOSTIC RADIOLOGY, SURGERY AND RESEARCH CENTER LABORATORY, ANIMAL DIVISION, HUDDINGE SJUKHUS, S-141 86 HUDDINGE, SWEDEN

BLOOD INFLOW AND COAGULATION IN VASCULAR CATHETERS

Comparison of the effect of polysaccharide solutions, saline and contrast medium

M. DAHLBORN, R. CRONESTRAND, G. KLINTMALM and S. SUNDELIUS

In clinical practice intraarterial catheters are intermittently injected with isotonic saline solution in order to avoid blood inflow and clot formation in the catheter lumen. In spite of this precaution clots may appear in the catheter during intraarterial catheterization with a risk for embolization (HAWKINS & HERBERT 1974, JAKOBSSON et coll. 1969). Previously it has been shown that the escape of saline and contrast medium from the catheter lumen is mainly dependent on the density of the fluid and that the inflow of blood may be substantial (DAHLBORN et coll. 1978, DAHLBORN & SÖDERLUND 1979, DAHLBORN & SUNDELIUS 1980). The influence of a number of polysaccharide fluids on blood inflow into vascular catheters was analysed in order to find one which could reduce blood inflow and coagulation to as small an extent as possible.

Material and Methods

Experiments were carried out on 19 mongrel dogs weighing between 16 and 40 kg. The animals were anaesthetized with phenobarbital and treated with neuroleptanalgesia, pancuron bromide and atropine. They were intubated and ventilated with an O_2/N_2O mixture in an AGA respirator and placed on the right side during the experiments.

In 14 dogs a catheter was inserted into a plastic tube replacing a part of the abdominal aorta and in the remaining 5 catheters were placed into the intact aorta through the femoral arteries. The tube of translucent plastic material which replaced the aorta immediately distal of the renal arteries had a length of 6 to 7 cm (Figs. 1, 2).

A straight translucent polyethylene catheter (ID 1.15 mm) was attached to the interior surface of the tube, glued and painted white on the outer surface in order to obtain a suitable background when measuring the blood inflow into the catheter. Around the aorta, proximal to the renal arteries or distal to the plastic tube, a probe for blood flow registration was placed (Nycotron, Nyegaard & Co, Norway). The intraarterial blood pressure was measured continuously. During the experiments the catheter was placed in 4 different positions, directed 5° upwards and 5° downwards, downstream and upstream. The catheter invariably retained its position during each period of 5 min experiment which was repeated 3 to 7 times. In 13 dogs the length of the blood inflow into the catheter was measured at 0, 15, 30 s and 1, 1½, 2, 3, 4 and 5 min following a single injection. The following catheter flush fluids were tested: isotonic

Submitted for publication 27 March 1980.

Table

Density and viscosity of human blood dog blood and flush fluids

	Density (20–22°C)	Viscosity (37–38°C) cP
Human blood	1 056	4 7
Dog blood	1 052	4 7
Isotonic saline solution	1 002	0 7
Isopaque Cerebral	1 310	4 0
Polysaccharide		
A	1 038	3 6
B	1 052	3 7
C	1 072	4 2
D	1 038	4 4
E	1 053	4 3
F	1 074	5 3
G	1 037	5 9
H	1 047	6 2
I	1 071	6 8
K	1 043	5 1
L	1 045	4 3
M	1 043	3 4
N	1 012	1 3
O	1 016	5 1
P	1 048	1 4
R	1 103	1 7
S	1 103	4 3




Fig 1 Abdominal aorta is replaced by a plastic tube containing a translucent polyethylene catheter Proximal to the tube a probe for blood flow registration is placed around the aorta

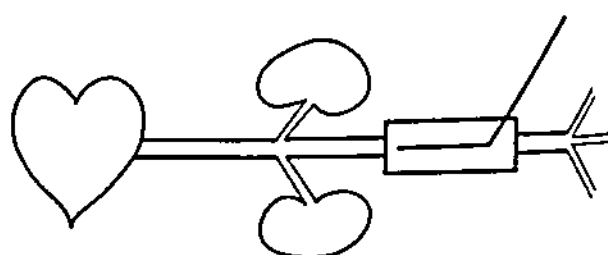


Fig 2 Drawing of Fig 1

saline solution contrast medium (Isopaque Cerebral meglumine/calcium metrizoate 280 mg I/ml) and 17 polysaccharide fluids named A to S of different densities and viscosities (Nyegaard & Co Oslo Norway Table)

In one dog the effect of continuous injection of 3 fluids was tested saline with the catheter directed upwards Isopaque Cerebral downwards and polysaccharide fluid E horizontally An automatic syringe pump with adjustable injection speed was connected to the catheter Each flush fluid was tested three times with a 20 ml syringe and at injection speeds of 0 20 to 14 ml/min In a separate series the fluids were injected via a 1 ml syringe at speeds of 0 03 to 0 7 ml/min with and without 0 1 ml air contained in the syringe The intraarterial blood pressure was recorded continuously (100–140/80–90 mm Hg) blood flow was not recorded

The density and viscosity of the saline and contrast medium were determined by the manufacturers (Pharmacia Uppsala Sweden Nyegaard & Co Norway) From HANDBOOK OF BIOLOGICAL DATA the density and viscosity of dog blood (1 052 and 4 7 cP at 38°C) and human blood (1 056 and 4 7 cP at 38°C) were specified (Table) The figures are almost identical to the mean value of the density of the blood (1 054 SD 0 007) of 10 of the animals Around these figures different densities and viscosities were given to the 17 polysaccharide flush fluids (Fig 3 Table)

Five dogs were used for prolonged registration of blood inflow and clot formation in polyethylene catheters after single flush fluid injections Saline Isopaque Cerebral and polysaccharide fluid E with out and with 100 IU heparin/ml were tested The catheters were inserted surgically through the femoral arteries and placed in the abdominal aorta By tilting the table with the dog the catheters became directed approximately 5° upwards in experiments with saline and 5 downwards using contrast medium and in either direction using the polysaccharide fluid E Each experiment was repeated 4 to 8 times The catheters were withdrawn 10 20 30 and 45 min after the flush fluid injection and the length of the blood inflow was measured through the translucent catheter The rate of appearance of clots was

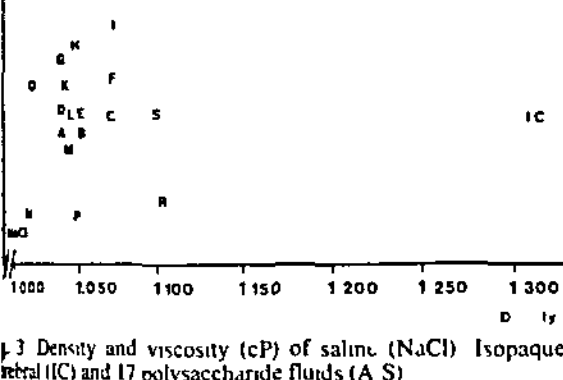


Fig 3 Density and viscosity (cP) of saline (NaCl) Isopaque Cerebral (IC) and 17 polysaccharide fluids (A S)

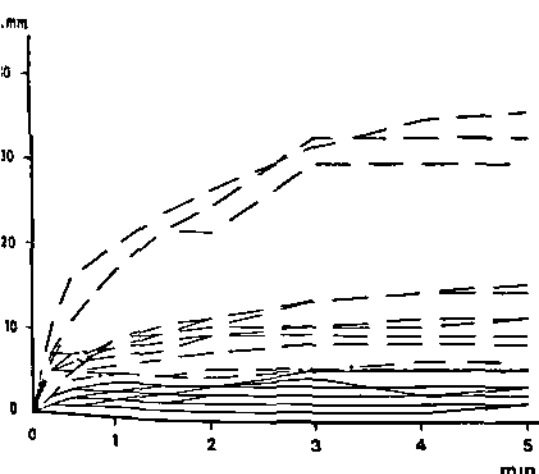


Fig 4 Blood inflow into the catheter after injection of saline with catheter directed upwards (– –) and downwards (—) L= length of inflow

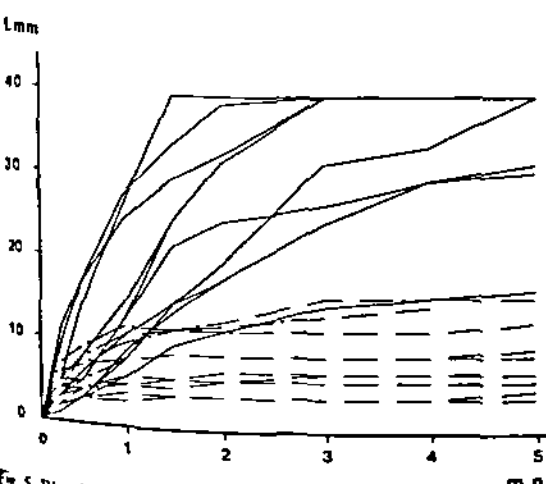


Fig 5 Blood inflow into the catheter after injection of Isopaque Cerebral with catheter directed upwards (– –) and downwards (—) L length of inflow

noted and their lengths measured The systolic blood pressure was recorded continuously (120–180 mm Hg) but no blood flow registrations were performed

Results

At the end of each fluid injection the catheter lumen was completely filled with the flush fluid A few seconds later the flush fluid invariably became partially replaced by blood forming a layer Similar to what was noted previously (DAHLBORN et coll DAHLBORN & SÖDERLUND DAHLBORN & SUNDELIUS) no difference in extent of inflow was observed between catheters placed upstream and downstream (Figs 4 5)

Saline always leaked out of the catheter lumen at a higher speed when the catheter was directed upwards compared with the downward direction One min after a single injection the average length of blood inflow was 10 mm and 2 mm respectively (Fig 4) The corresponding values regarding contrast medium were 7 mm and 16 mm i e this fluid leaked out more rapidly when the catheter was directed downwards (Fig 5)

Polysaccharide fluids of densities lower (1 012–1 043) than that of blood (1 052) always caused more blood inflow into catheters directed upwards while the reverse was true with fluids of higher densities (1 071–1 103 Fig 6)

However when fluids of densities 1 043–1 053 i e close to that of blood were used the mean blood inflow was always less than 3 mm Small differences were recorded with catheters directed upwards and downwards

No differences regarding blood inflow were noted between polysaccharide flush fluids of high viscosity (5–7 cP) and those of low viscosity (1–2 cP) when fluids of the same density were compared (Fig 7)

In the series of polysaccharide flush fluids fluid E (density 1 053 viscosity 4 3 cP) was considered to be the most suitable one This fluid had the least mean blood inflow with a mean value of 1 5 mm after 5 min The extent of inflow varied only to a small degree with the direction of the catheter The blood flow measured by the probe varied between 20 and 400 ml/min and was related to the position of the probe around the aorta with respect to the level of the renal arteries and to the condition of the animal The intraarterial blood pressure varied between 170/140 and 70/60 mm Hg Large differences in blood flow and blood pressure recorded in otherwise unchanged experimental conditions did not influence blood inflow into the catheters On continuous flush fluid injection no differences between contrast medium and fluid E occurred No blood inflow into

the catheter lumen was observed when the flow of the flush fluids exceeded 4 0 ml/min (Fig 8a b)

However at flow velocities of 0 6 to 4 0 ml/min blood passed into the catheter in each systole only to disappear in diastole The corresponding flow velocities in the two groups regarding saline were 14 0 5 5 to 14 0 ml/min respectively (Fig 8c) If lower flow velocities were used the catheter tip consistently contained some amount of blood Using the small syringe and contrast medium or fluid E no blood inflow occurred into the catheter lumen even at an extremely low flow velocity (0 03 ml/min) The corresponding flow velocity regarding saline was higher (0 35 ml/min) However if 0 1 ml air was added to the fluid and contained in the syringe throughout the injection blood appeared in the catheter even at the low flow velocities

A rapid and continuous blood inflow into the catheters inserted into the abdominal aorta was observed following single isolated injections of saline and contrast medium (Fig 9)

The mean length of the blood inflow was about 100 mm with both fluids after 20 min during the *following 25 min no further inflow of blood was* observed Following a single injection of fluid E blood inflow into the catheter was only very slight with a mean length of 7 mm of the column after 20 min and no further inflow during the following 25 min (Fig 9) The frequency of clots in the catheter lumen after injection of saline gradually increased to 80 per cent during the first 30 min after which no further increase was observed (Fig 10)

Clots were found in almost all experiments after injection of contrast medium and in 50 to 70 per cent when fluid E without heparin was used With fluid E to which heparin had been added no clots were observed at 10 min but appeared successively during the following 35 min when clots were registered in 60 per cent of the experiments

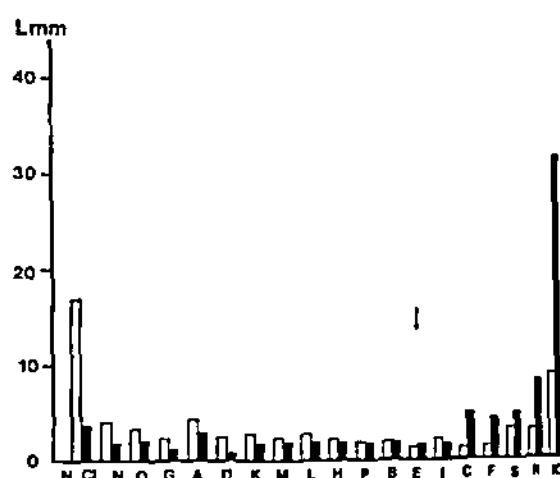


Fig 6 Blood inflow into the catheter 5 min after injection o saline (NaCl) Isopaque Cerebral (IC) and 17 polysaccharide fluids (A S) The catheters were directed upwards (□) an downwards (■) Placement is made according to the densities o the fluids from saline (1 007) to Isopaque Cerebral (1 310) Arrow points at polysaccharide fluid E

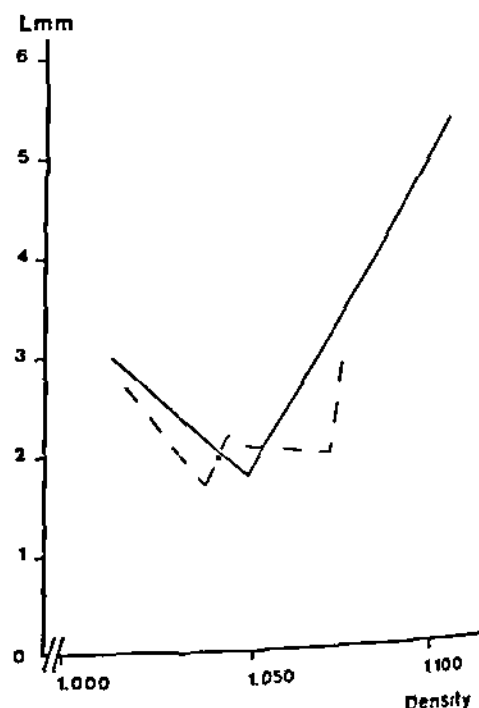
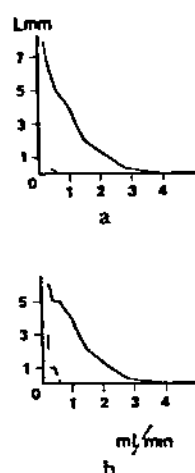


Fig 7 Blood inflow into the catheter 5 min after injection of polysaccharide fluids with high viscosity (▶—▶) and low viscosity (—) L=length of inflow

Discussion

Thromboembolism is a well known complication of intraarterial catheterization (LANG 1963) In clinical routine saline is used as a flush fluid and following injection of contrast medium during angiography the catheters are filled with the medium However neither saline nor contrast medium prevents passage of blood into the catheters The extent of blood inflow has been shown mainly to depend on the relative densities of the fluids and blood and is thus gravity dependent (DAHLBORN & SÖDERLUND) The present results obtained in vivo agree with those achieved previously in an artificial blood circulation model (DAHLBORN & SÖDERLUND) However the blood inflow was generally larger in the model in which higher amplitudes of pressure and a larger blood flow were generated In both investigations fluctuations in the haemodynamic parameters had



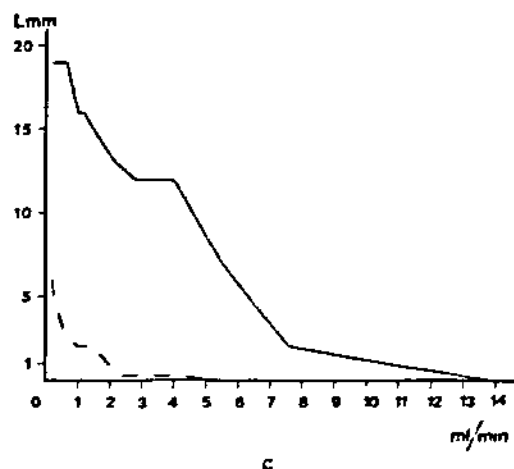


Fig 8 Blood inflow into the catheter during continuous fluid injection with a) polysaccharide fluid E b) Isopaque Cerebral and c) saline The upper curves (——) represent mean blood inflow during systole and the lower curves (– –) during diastole

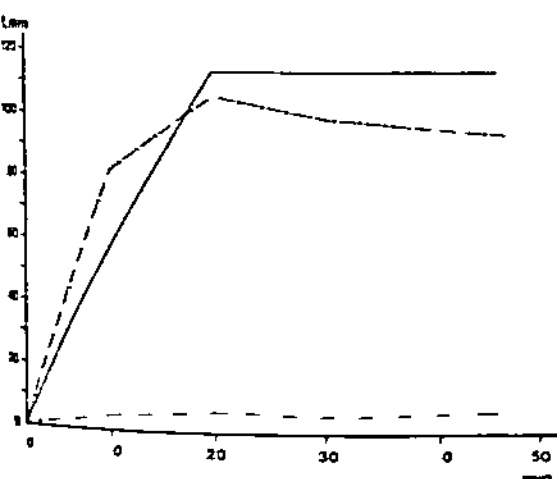


Fig 9 Mean blood inflow into the catheter after injection of saline with catheter directed upwards (—) Isopaque Cerebral downwards (●—●) and polysaccharide fluid E with either direction ♦—♦

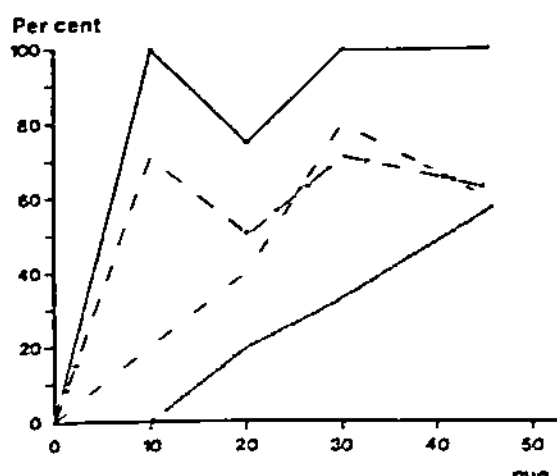


Fig 10 Per cent of clots in the catheter lumen after injection of saline (– – –) Isopaque Cerebral (—) polysaccharide fluid E without (—▶▶) and with heparin (●●—●●)

no appreciable influence on the relative extent of the blood inflow when related to the two catheter directions The same applied as regards the direction of the blood stream around the catheter In addition no differences were observed in the rate of passage of blood into catheters moving freely in the animal aorta and filled with contrast medium (DAHLBORN et al.) and the catheter attached to the wall of the plastic tube in the present experiments This implies that the positioning of the catheter whether centrally or peripherally in the blood stream should be of minor significance It is inferred that this may be valid also for saline and other flush fluids

In an attempt to analyse the influence of the density and viscosity of the flush fluids in more detail and with the ultimate goal of reducing the passage of blood into the catheters a series of polysaccharide fluids of different densities and viscosities were examined The fluids essentially behaved like saline and contrast medium A fluid of a density lower than that of blood leaked out of the catheter more rapidly when it was directed upwards the one of a higher density escaped more easily with an opposite catheter direction As expected the fluid with the density almost identical to that of the blood caused the least inflow irrespective of the direction of the catheter These results are in conformity with previous ones (DAHLBORN & SÖDERLUND) in which saline of a density close to that of blood was shown to leave the catheter at a lower speed than physiologic saline The same results were obtained with contrast medium provided that the catheter was directed

downwards Thus it is evident that the passage of blood into a catheter following a single injection of flush fluid is highly dependent on its density

Previously it has been demonstrated that the viscosity of a flush fluid has some influence on blood inflow e g a fluid of high viscosity will leak out of the catheter at a slower rate than does one of low viscosity (DAHLBORN & SUNDELIUS) In the present experiments this effect was demonstrated at continuous flush with fluid E and contrast medium which both blocked the entrance of blood at considerably lower injection rates than did saline the latter having a lower viscosity than fluid E and contrast medium This accords with previous results i e the injection rates of saline and contrast medium necessary for keeping the catheter free of blood were of the same magnitude and moreover were independent of the direction of the catheter (DAHLBORN & SÖDERLUND) Thus at continuous injection the viscosity of the fluid will be more significant than the density In contrast following isolated single injections differences in blood inflow due to differing viscosities of the polysaccharide fluids were not observed Fluids of higher viscosity than those examined might have caused a decrease in blood inflow but such fluids should be difficult to inject and therefore would not be of advantage for clinical purpose

Continuous injection requires a large volume of fluid to keep the catheter free of blood and is therefore of limited utility However if a small syringe is used the injection rate can be reduced considerably irrespective of the fluid chosen It is surmised that this depends on the favourable dimension of the fluid system and the absence of air bubbles Elimination of air from the fluid system is important to avoid air emboli and to *reduce the speed of continuous* injection in keeping the catheter free of blood

The passage of blood into catheters filled with saline contrast medium or polysaccharide fluid E ceased within 20 min after a single injection It is not clear whether further inflow was prevented by clot formation or whether other factors might have operated as well since the addition of heparin to fluid E did not alter the time of inflow In any event as noted in the experiments lasting 5 min the column of blood was considerably larger in catheters filled with saline or contrast medium compared with those with fluid E The influence of this fluid on the blood coagulation system will be communicated in a separate report (DAHLBORN & NYMAN to be published)

SUMMARY

Inflow of blood into intraarterial catheters in dogs following single and continuous injections of saline contrast *medium and polysaccharide fluids* were analysed with special reference to the influence of their density and viscosity Clot formation was also analysed and the favourable properties of one variant of the polysaccharide fluids were demonstrated

ACKNOWLEDGEMENTS

The authors are indebted to A Kallner Hudding Sjukhus and to O Thulesius and E Berlin at the Labor*tory of Clinical Physiology* Vaxjo who gave generous advice and aided in the determination of density and viscosity of blood and tested fluids

REFERENCES

DAHLBORN M and NYMAN D The effect of catheter flush fluids on blood coagulation and aggregation of platelets To be published in Acta radiol Diagnosis

— SÖDERLUND U Blood inflow into vascular catheters following *injection of saline solution* and contrast medium Model experiments Acta radiol Diagnosis (1979) 439

— SUNDELIUS S Blood flow into vascular catheters of different size and number of sideholes Model experiments with flush fluid injections Acta radiol Diagnosis 21 (1980) 469

— CALISSENDORFF B and CRONESTRAND R Blood inflow into intra arterial catheters following injection of contrast medium Acta radiol Diagnosis 19 (1978) 81

HANDBOOK OF BIOLOGICAL DATA Edited by W S Spector W B Sanders Philadelphia and London 1956

HAWKINS I F and HERBERT L Contrast material used as a catheter flushing agent A method to reduce clot formation during angiography Radiology 110 (1974) 351

JAKOBSSON B BERGENTZ S E and LJUNGQVIST U Platelet adhesion and thrombus formation on vascular catheters in dogs Acta radiol Diagnosis 8 (1969) 221

LANG E K A survey of the complications of percutaneous retrograde arteriography Radiology 81 (1963) 25

FROM THE DEPARTMENT OF DIAGNOSTIC RADIOLOGY AND THE DATA PROCESSING DEPARTMENT HAUKELAND UNIVERSITY HOSPITAL N 5016 BERGEN NORWAY

IDIOPATHIC HYPERTROPHIC SUBAORTIC STENOSIS

V Analysis of the shape of the left ventricular cavity at the end of diastole

G KVAM D RANGNES and J GÖTHLIN

The angiographic appearance of the left ventricle in idiopathic hypertrophic subaortic stenosis (IHSS) is characteristic (BRAUNWALD et coll 1964 KVAM 1980 Part I) In the present communication the shape of the apical and middle parts of the IHSS left ventricular cavity is analysed by means of a geometric model

Most angiographic volumetric approaches imply envisaging the normally configurated left ventricular cavity as an ellipsoid (KASSER & KENNEDY 1969 DODGE 1971) However the septal surface of IHSS resembles a catenoid surface convex longitudinally and concave transversely towards the left ventricle (HUTCHINS & BULKLEY 1978) (A catenoid surface is formed by a catenary curve rotated around an axis parallel to the tangent in the apex of the catenary) This septal protrusion is the main difference between the normally shaped and the IHSS left ventricular cavity Accordingly the IHSS left ventricular cavity may be envisaged as what remains when part of an ellipsoid is cut away by a catenoid surface

This geometric situation is illustrated in the model's sagittal plane when the catenary k has an axis of revolution A parallel to the longest axis of the ellipsoid (Fig 1 a) Fig 1 b is a transverse section corresponding to the half axes R is the smallest radius of revolution for the catenary around the axis A Fig 1 c is a drawing in perspective of such a model The horizontal and transverse planes of the ellipsoid are shown the model s equator is the ellipse where the horizontal plane (approximately parallel to the overall septal plane) meets the ellipsoid surface Fig 1 d illustrates what remains when the part above the catenoid surface is removed On either side a part of the ellipse below its equator is removed This remaining part of the ellipsoid projected down on a plane parallel to its horizontal plane thereby obtains the shape shown in Fig 1 e an elliptic structure with an indentation on either side

In this way the indentations of the IHSS left ventricular cavity in the 30° RAO projection are accounted for The indentation on the right side is however regularly further caudally and larger than the indentation on the left side (Fig 2) Therefore in a geometric sense it is not possible to demonstrate the axis of revolution A parallel to the longest axis of the ellipse

An attempt was made to determine an outer ellipsoid an axis of revolution A a smallest radius of revolution R and the curve of the catenary from individual patients with IHSS From these parameters a model was constructed by use of projective geometry The ellipse and the catenoid were positioned in a relationship giving a resemblance to the IHSS left ventricular cavity when projected on to the planes corresponding to the 30° RAO and the

---

Submitted for publication 31 August 1979

60° RPO projection The catenary curve was adjusted with the same means in mind

Materials and Methods

The biplane cine left ventriculograms previously described from 4 patients with IHSS were further analysed An end diastolic frame from the 30° RAO and the 60° RPO projections as well as the enlargement factor were defined as described (KVAM 1980 Parts I II)

The cavity outline was drawn from the 30° RAO end diastolic frame (Fig 3) The posterior papillary muscle was not excluded from the cavity outline The outermost contour was drawn across the indentations following the direction of the rest of the cavity outline on both sides (Fig 3 broken line) The outermost contour was continued across the lowest protrusion by the mitral valve following a smooth curve to the diameter of the aortic ring (Fig 3) The deepest indentations on the right and left side respectively were measured along the lines I_r and I_l drawn at right angles to the outermost contour *These lines define one point each on the cavity outline* A line L_1 was drawn through these points Another line L_2 was drawn parallel to L_1 through the point where the cavity outline fuses with the outermost contour on the right apical side The distance d_1 between L_1 and L_2 was measured A third line L_3 was drawn at right angles to L_1 and L_2 forming the angle α with a line parallel to the long axis of the examination table The apico midaortic axis was also drawn forming the angle β with the long axis of the patient

The area A inside the outermost contour (heavy broken and solid lines in Fig 3) was measured and the outer width w_0 was calculated as $4A/\pi L$ according to the ellipse formula L is the apico midaortic length

From the 60° RPO end diastolic frame the cavity outline was drawn A line was drawn through the two end points of the anterior convexity of the outline The distance d between these points was measured (Fig 4) A second line was drawn parallel to the first tangential to the anterior curve and the distance h_1 between these lines measured The dorsal contour of the most protruding part of the septum was defined A third line parallel to the others was drawn tangentially to the dorsally protruding septum The distance h between this latter line and the most anterior (secondly drawn) line was also meas-

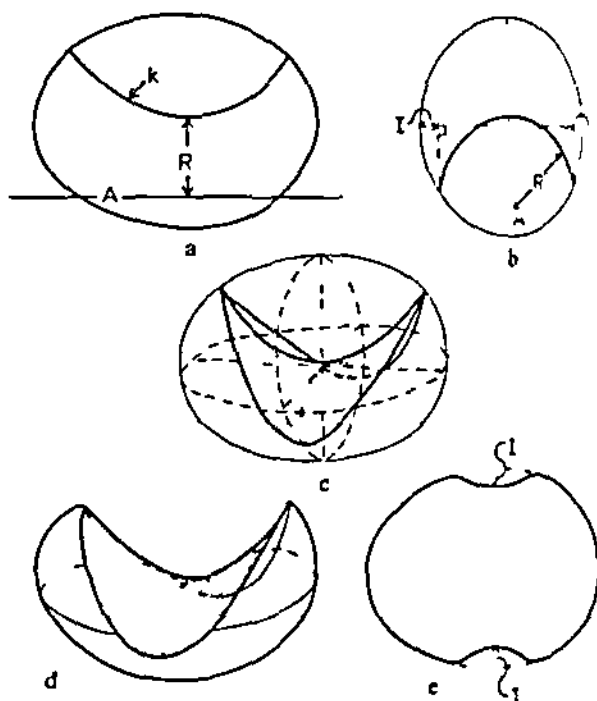
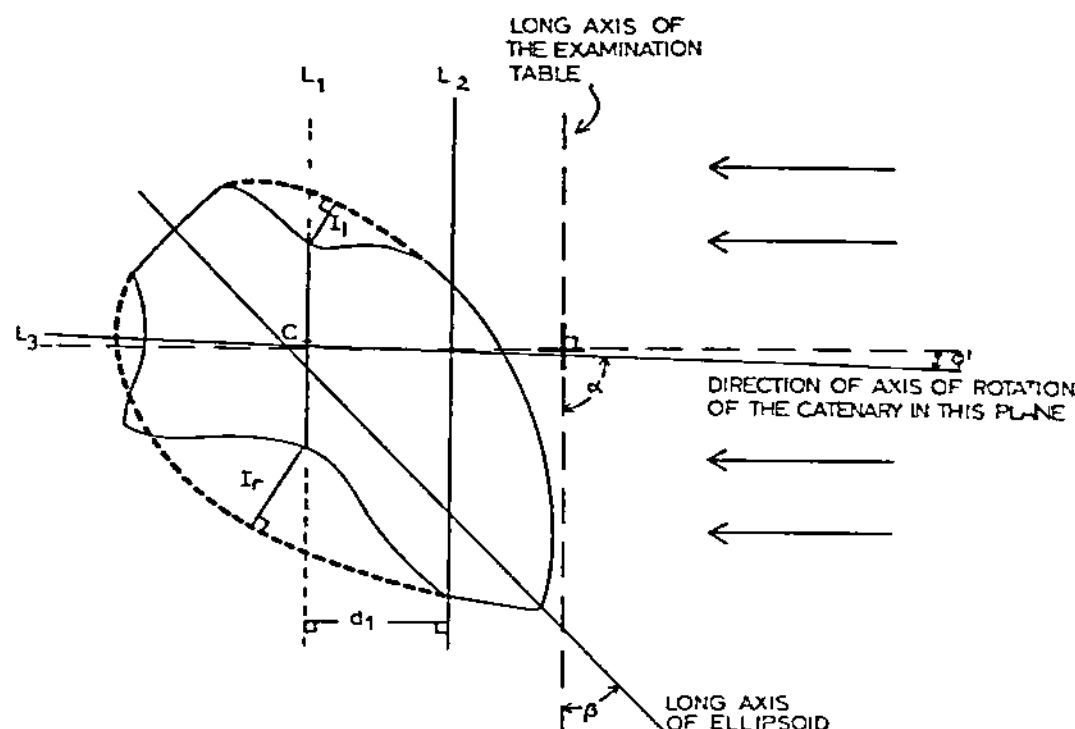


Fig 1 An ellipsoid transectioned by a catenoid The axes of th ellipsoid and of the catenoid are parallel a) Sagittal section k Catenary A Axis of rotation for the catenary R Shortest radii of rotation for the catenary b) Transverse section R and A as i (a) I The large indentation projected onto the horizontal plan c) Perspective drawing The circumference and axes of th horizontal and transverse planes (---) The circumference of th part of the catenoid which lies inside the ellipsoid plus the cate nary curve corresponding to the one in (a —) The arc of rotation of the apex of the catenary ( ) d) The part of the ellipsoi above the catenoid is removed e) Projection of (d) onto th horizontal plane Only the circumference is shown



Fig 2 End diastolic frame from one of the IHSS patients in the 30° RAO oblique projection The waist of the cavity is shown with a larger dextro-caudal and a smaller sinistro-cranial indentation



3 The 30° RAO end diastolic left ventricular cavity outline from one of the patients (solid contour) with the outermost con (broken contour) Vertical broken line long axis of the examination table and horizontal broken line at right angles to the vertical line The indentational lines I and I_l drawn from the points of maximum indentation on the right and left sides respectively at right angles to the outermost contour The line L joins the points of maximum indentation on either side L is drawn parallel to L through the apical end point of the right indentation and L_3 i drawn at right angles to L and L The angle α is formed between L_3 and the long axis of the examination table the angle β between the projected apico-midaortic length and the long axis of the examination table and the angle φ between L_3 and a line at right angles to the long table axis Thus α plus φ equals 90° The 60° RPO projection is formed when the cavity is viewed in the paper plane along the long arrows from the right

The angle δ between these lines and the long the table top was also measured

The model was designed as an ellipsoid with equal verse axes obliquely transectioned by a cate surface

The ellipsoid of the model was given the same as the apico-midaortic cavity length L of the and the transverse axes were both given the as defined In the 30° RAO projection the longest model ellipsoid axis forms the angle β with the long axis of the table top and the ellipsoid equator (as defined in the introduction) lies in a plane parallel to the 30° RAO film plane

The axis A of the model catenoid forms the angle with the long axis of the patient in the 30° RAO projection

When the left ventricle (Fig 3) is observed along the long arrows in the paper plane then the ventricle appears as in Fig 4b

The direction of the catenary axis of rotation A is considered parallel to L_3 when observed in the 30° RAO plane and parallel to the three lines in Fig 4b when observed in the 60° RPO plane The smallest angle between the axis A and the 30° RAO paper plane was calculated as demonstrated in Fig 5a

The anterior curve is a representative of the radius of rotation of the catenary which together with d_2 forms a circular segment Its height h_1 is regarded as representative However the cathetus d is a slight foreshortening of the real cathetus length d d_2 is a projection of d which forms the angle (90−α) with the long axis of the table top in the 30° RAO plane In the 60° RPO plane the corresponding angle is (90−δ) The calculation of d appears in Fig 5b

The radius R of the anterior circular segment was calculated according to the Pythagorean theorem (Fig 5c) The smallest radius of rotation of the catenary R was calculated by subtracting h_2 from the radius of the segmental arc

The distance d_1 is regarded as a real distance d_1 running in a direction parallel to the catenary axis A therefore d_1 is $d_1/\sin\varphi$ In an isosceles triangle with one side equal $2\times d_1$ and the height to the oppos



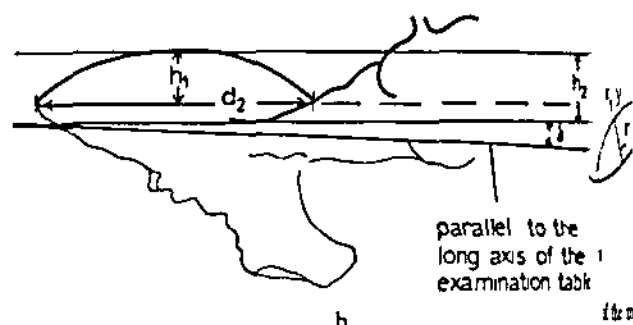


Fig 4 a) End diastolic 60° RPO frame from one of the patients b) Line d_2 is drawn between the end points of the anterior curvature Anterior to this line a straight line as drawn tangential to the anterior curvature and dorsally another is drawn tangential to the dorsally protruding septum also parallel to the first line h_2 the distance between these two lines and h_1 the distance between the first two lines δ is the angle between these three parallel lines and the long axis of the examination table

ing corner equal to h_2 (Fig 5 d) the interrelationship between the corners is defined The formula for the catenary was adapted to make the curve run through three such interrelated points the opposing corner corresponding to the catenary apex

The following model parameters were then known (1) The shape and size of the outer ellipsoid (2) the shape and size of the catenoid (3) the indentations I and I_1 and (4) the direction of the axes and their appearance in the 30° RAO and in the 60° RPO projections

The maximum indentations on the left and right sides were located at a distance I_l and I_r respectively from the outermost ellipsoid of the model The actual coordinates (x y_2 z_2 and x_1 y_1 z_1 respectively) were deliberately chosen to make the model resemble the 30° RAO projection of the IHSS left ventricular cavity The principles of the calculation for defining the model were as described in Fig 6

When testing the model it was detected that the arc of the catenary curve was too straight to give good resemblance and the curvature was therefore increased to produce such a resemblance

Results and Discussion

The calculated parameters for the 4 patients appear in the Table as well as the corrected values for the catenary curve

A drawing of the 30° RAO cavity outlines with the outermost ellipsoids for the 4 patients (I a–IV a) is demonstrated in Fig 7 In Fig 7 b the cavities of the

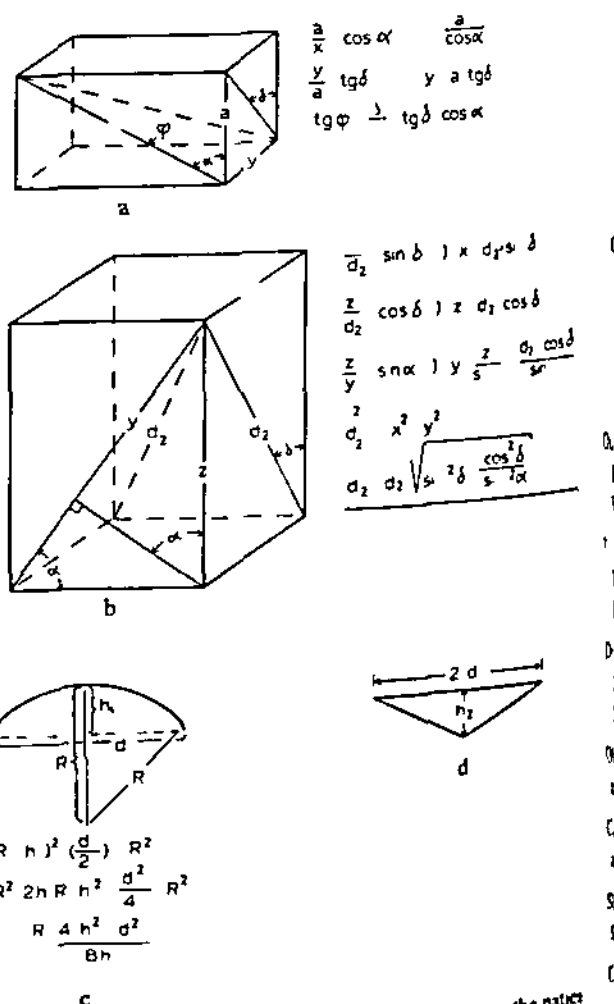


Fig 5 Various calculation principles for determining the patient parameters a) smallest angle φ between the axis A and the 30° RAO paper plane b) Non foreshortened cathetus d_2 of the anterior curvature of which d_1 is a small foreshortened version c) Radius R of the anterior curvature d) Triangle defining the catenary curve (d_1 equals d /sin φ)

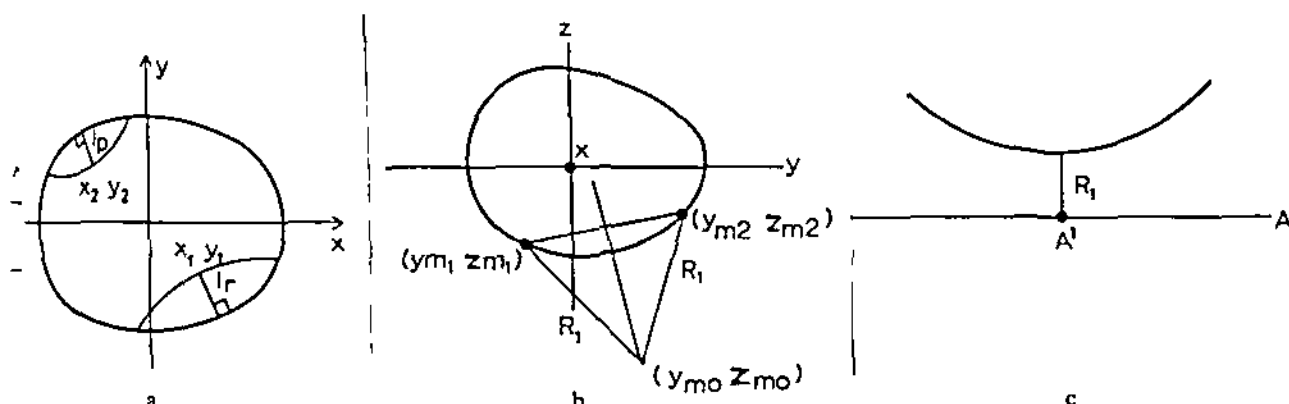


Fig 6 Principles of the model calculations The x y axes correspond to the 30 RAO paper plane the x axis corresponds to the apico-midaortic line The z axis is perpendicular to these other two a) The coordinates of the maximum right and left indentations are $x\ y_1$ and x_2y_2 They were deliberately chosen to make the distances from the outer model ellipsoid equal to l_r and l and to make the model resemble the 30 RAO projection of the IHSS cavity b) The coordinates of the maximum indentation on the two sides were transformed into the coordinates of a system with x axis parallel to the catenoid axis of rotation A $(x_1\ y_1\ z\ ) \rightarrow (x_{m1}\ y_{m1}\ z_{m1})$ and $(x\ y_2\ z_2) \rightarrow (x_m\ y_m\ z_m\ )$ In the figure the model ellipsoid is viewed along the catenoid axis of rotation (therefore as the point $y_{mo}\ z_{mo}$) c) R is the shortest radius of rotation for the catenary With $x_m = x_{m1}$ (an acceptable approximation) the point A (c) is defined The direction of the catenoid axis was calculated as previously described Thus the relevant model was defined

Table

Calculated parameters for the 4 patients and corrected values for the catenary curve

	Patient No			
	I	II	III	IV
Outermost ellipsoid				
Length L	12 4	11 8	10 3	11 5
Width w (=depth)	7 0	6 6	7 3	7 0
Indentations				
Right I	? ?4	2 17	1 97	1 87
Left I_l	1 04	0 66	0 65	0 72
Direction axes 30° RAO proj				
Rotat axis catenoid	88 5	83 3	60	64 0°
Long axis ellipsoid	45 0°	30 5	44 0°	35 0°
Obliquity 60° RPO proj (neg val upwards in an anterior direction)	−5 3	+1 5	+23 0°	+4 8°
Calculated direction catenoid axis rel to 30° RAO plane	−0 14	+0 18°	+11 9°	+2 11
Shortest radius of rotation for catenoid R	3 37	4 16	4 39	[illegible] 93
Catenary arc				
Calculated				
h	1 67	1 55	1 69	1 54
d	3 97	3 [illegible] 5	3 80	4 40
Corrected				
h_2	1 67	1 55	1 69	1 54
d	? 50	? 00	? 40	? 70

respective geometric models as viewed in the corresponding projection are drawn actually the outermost ellipsoid with broken lines where the indentations are found The similarity is obvious

The outermost ellipsoid of the model for one of the patients appears in Fig 8 That part of the catenoid surface which lies inside the ellipsoid is also illustrated In Fig 8a the ellipsoid is viewed along the 30° RAO paper plane at right angles to the longest ellipsoid axis The catenoid then looks like a twisted propeller In Fig 8b the ellipsoid is viewed along the 30° RAO paper plane but corresponding to the 60° RPO projection

The model cavity below the catenoid does not much resemble the ventricle in the 60° RPO cine projection The sector adjacent to the mitral valve of the model is highly inappropriate however The ventricular inflow tract corresponding to the oblique lines of Fig 8c is not an anteriorly lying structure in the 60° RPO projection it lies posteriorly This part can therefore be excluded from the model The inflow is instead drawn below the outermost ellipsoid as shown in Fig 8d in which also from the dorsally protruding septum the outflow tract into the aorta is drawn directly

Below the septum the cavity is viewed semi axially Semi axial superimposition of contrast medium makes this part more dense (Fig 8d oblique lines) Together with the outflow tract it forms the anterior boundary of the inverted cone sign (COHEN et coll 1964) The dorsal boundary is the posterior mitral leaflet and the gush of blood not containing contrast medium

The anterior curve of the cavity is not situated as anteriorly as the anterior curve of the model It lies at the distance h_2 anterior to the dorsally protruding septum and it has a somewhat longer radius than the arc of the dorsally protruding septum Such an anterior arc is drawn in an appropriate manner in Fig 8d This means that the longitudinal convexity of the catenary straightens out towards the lateral side in the direction of the catenary axis The maximum thickness of the IHSS septum may be found at the aortic end or in the mid portion (BALTAXE et coll 1976) thereafter it may straighten out A longitudinal section published by FARRER BROWN (1977) shows the longitudinal convexity to stop a little before the apex During operation often a rather definite hypertrophic ridge may be felt the convexity not being very long (SEGERDAL 1979) Even though the catenary convexity straightens out

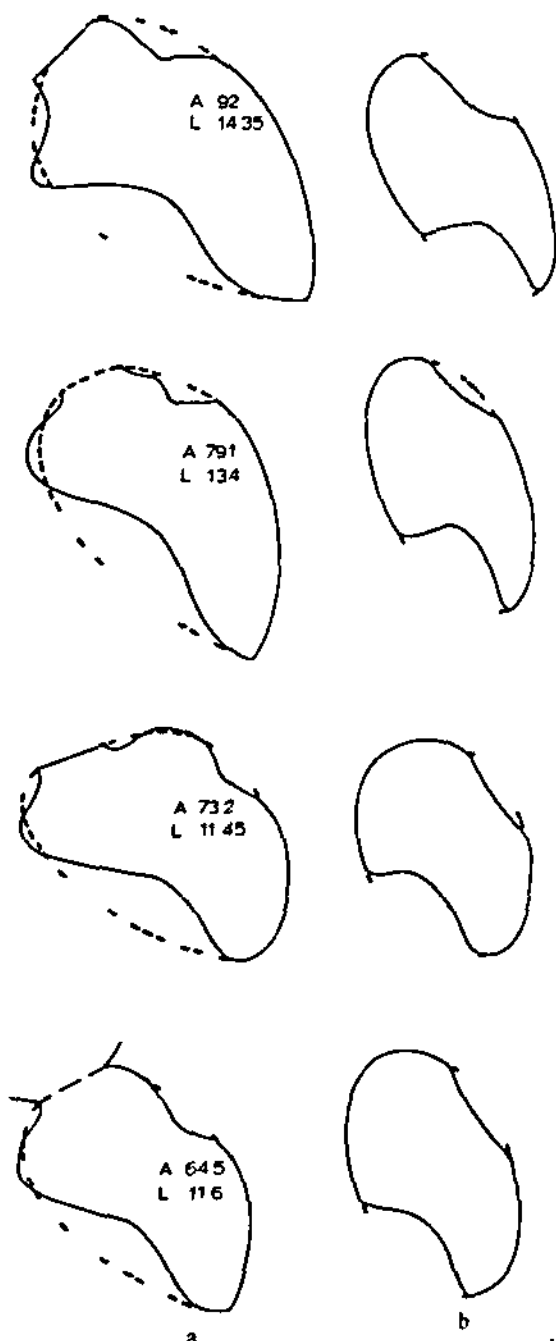


Fig 7 a) The 30° RAO end diastolic cavity outlines with th outermost ellipsoid for the 4 patients (I–IV) b) The model cavi outlines in the corresponding projection with the outer ellipsoid

towards the left a convexity may still remain in th aorto-apical direction as indicated by the pointe line in Fig 8d which possibly is due to the fact th the catenoid axis is oblique relative to the ellipsoi axis

The part of the left ventricle contiguous to th valvular apparatus is highly irregular At the mitr valve corresponding to the ventricular inflow (Fi 8c oblique shadening) the outermost ellipsoi exaggerates the anterior part of the cavity to a h g degree This anterior part is actually non-existen

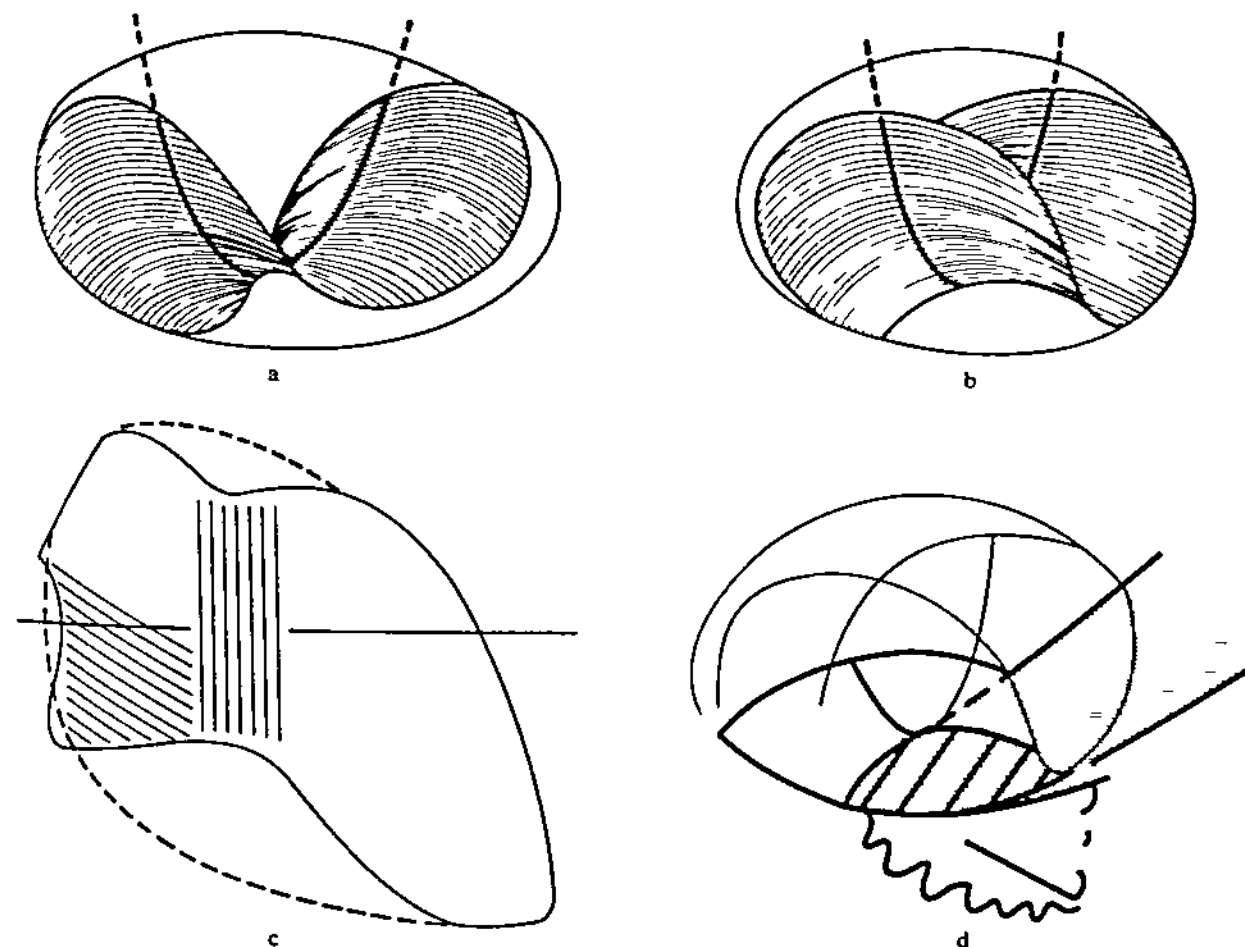


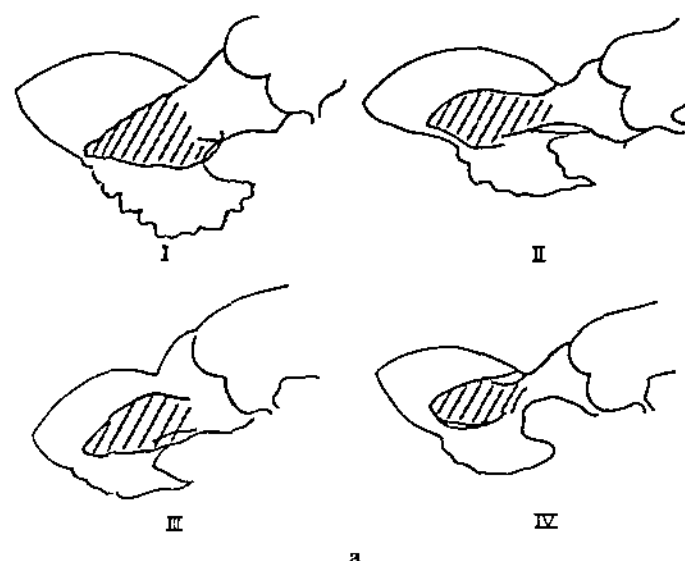
Fig 8 The outermost ellipsoid of the model for one of the patients The catenoid surface inside the ellipsoid and the line of transection between this surface and the ellipsoid surface are shown The uppermost catenary curve lying in the vertical plane and in the catenoid plane (heavy line unbroken inside and broken outside the ellipsoid a) Viewed along the 30° RAO paper plane at right angles to the longest ellipsoid axis b) Viewed along the 30 RAO paper plane corresponding to the 60 RPO projection c) The cavity outline and the outermost contour for one of the patients The ventricular inflow which is a posterior structure is obliquely shaded The vertical shading corresponds to the most protruding part of the septum and the unbroken straight line to the axis of the catenoid like surface formed by the septum d) The inflow part is excluded from the anterior part of the model cavity and the anterior aortic outline drawn obliquely upwards from the dorsally protruding septum of the model The thin apical anterior part of the model cavity has also been excluded as the longitudinal septal convexity straightens apically Thereby the anterior curve of the 60° RPO projection is produced The obliquely shaded part shows where the cavity is viewed nearly axially and in this region a thick layer of contrast medium is regularly observed on the cine films Dorsally the inflow part is added corresponding to the oblique shading in (c) Thus the 60° RPO end diastolic appearance is reproduced by the model

as this space is occupied by the right ventricular outflow tract and the pulmonary artery The anterior part is absent but dorsally the inflow actually lies outside the outermost ellipsoid The inflow part with the mitral valves is indicated in the drawing of Fig 8d Anteriorly the dorsally protruding septal border transitions directly into the outflow tract Thus the axially projected biconcave part together with the outflow tract limited dorsally by the anterior mitral leaflet with blood not containing contrast medium behind it causes the inverted cone appearance

In this manner (Fig 8d) the IHSS ventricular cavity consists of a mid/apical part a right/dorsal low part and a left/anterior outflow part whereby the 30° RAO and the 60° RPO appearances are explained

In Fig 9 (I a–IV a) drawings of the 60° RPO end diastolic cine frames from the 4 patients and the corresponding model cavities drawn in the same manner as Fig 8d are presented

The model imitation is an approximation towards ideal geometric surfaces The presumptions upon which the registrations rest are not completely fulfilled and some of the calculations of the parameters also represent approximations in a geometric sense It is therefore no surprise that one of the parameters had to be modified in order to produce resemblance



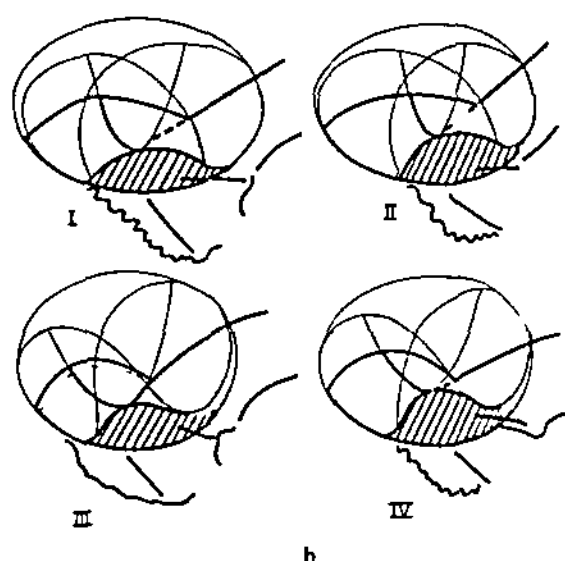


Fig 9 a) Drawings from the 60° RPO end diastolic cine frames from the 4 patients (I–IV) b) The corresponding model cavities drawn in the same manner as in Fig 8d

Probably some error exists in all the parameters making the relationship between the model and the ventricular cavity less perfect than would otherwise be the case The protrusion of myocardial mass and the papillary muscles tend to exaggerate the length of the indentation (d_1 in the Table) relative to the catenary curve The correction of the catenary arc (d_1 corrected) represents the accumulated error of the different parameters The problem was thus solved because the catenary arc is a parameter where the direction of the error is known

The resemblance produced is evident Therefore the cardioangiographic appearance is regarded as produced by a cavity with the general configuration described

Previously the left ventricular cavity of IHSS was described as shallow based upon volumetric analysis (Part II) This is supported by the present result which delivers a more detailed description of the end diastolic left ventricular cavity in IHSS

Conclusion

The left ventricular surface of the muscular interventricular septum in IHSS is convex longitudinally and concave transversely The long axis of the catenoid is oblique relative to the apico-aortic axis whereby the asymmetric indentations of the 30° RAO IHSS left ventricular cavity are explained The IHSS ventricular cavity is shallow in its mid and apical parts

SUMMARY

The angiographic appearance of the end diastolic left ventricular cavity in 4 patients with obstructive idiopathic hypertrophic subaortic stenosis is characterized by a model in projective geometry The muscular interventricular septum catenoid like (convex longitudinally and concave transversely towards the left ventricular cavity) has an oblique long axis of the catenoid relative to the apicomidaortic axis of the left ventricle The cavity is shallow in its mid and apical parts

REFERENCES

BALTAXE H A LEVIN AA R and ALONSO D R Appearance of the interventricular septum in obstructive lesions of the left ventricular outflow tract Amer J Roentgenol 127 (1976) 573

BRAUNWALD E LAMBREW S ROCKOFF D ROSS J and MORROW A G Idiopathic hypertrophic subaortic stenosis Circulation 29–30 (1964) Suppl No 4 p 3

COHEN J EFAT H GOODWIN J F OAKLEY C M and STEINER R E Hypertrophic obstructive cardiomyopathy Brit Heart J 26 (1964) 16

DODGE H T Determination of left ventricular volume and mass Radiol Clin N Amer 9 (1971) 459

FARRER BROWN G Primary cardiomyopathies In A colour atlas of cardiac pathology p 91 Wolfe Medical Publications London 1977

HUTCHINS G M and BULKLEY B H Catenoid shape of the interventricular septum Possible cause of idiopathic hypertrophic subaortic stenosis Circulation 58 (1978) 392

KASSER I S and KENNEDY J W Measurement of left ventricular volumes in man by single plane cineangiocardiography Invest Radiol 4 (1969) 83

ASI G Idiopathic hypertrophic subaortic stenosis I Interventricular septum during the systolic contraction A The shortening of the muscular interventricular septum B Analysis of the protruding non bending muscular interventricular septum Acta radiol Diagnosis 21 (1980) 53

— Idiopathic hypertrophic subaortic stenosis II The shallow left ventricular cavity Acta radiol Diagnosis 21 (1980) 165

SEGARDAL G (Heart surgeon Haukeland University Hospital) Personal communication

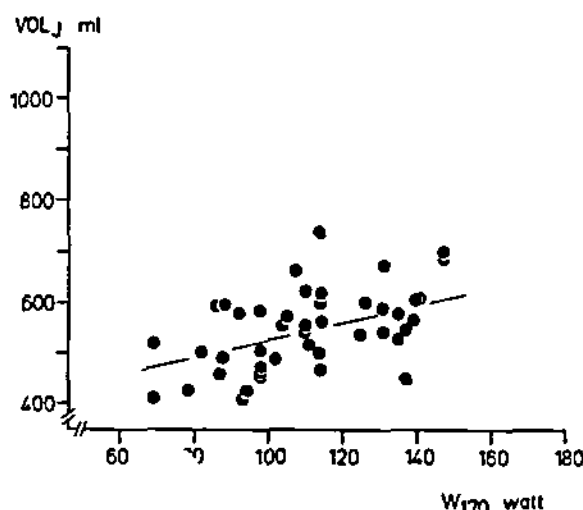


Fig 10 Relation between total heart volume and physical work capacity in young women (20–26 years)

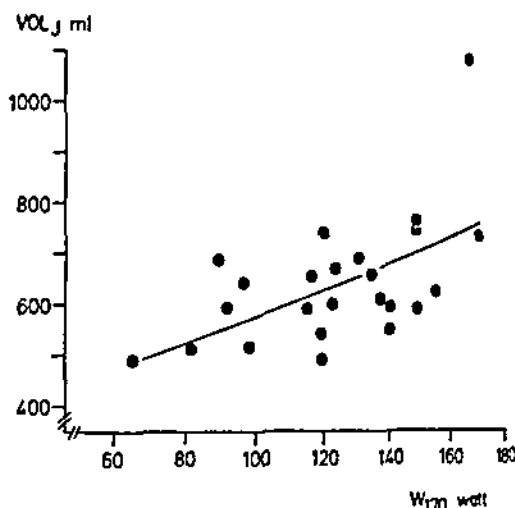


Fig 11 Relation between total heart volume and physical work capacity in middle aged women (40–45 years)

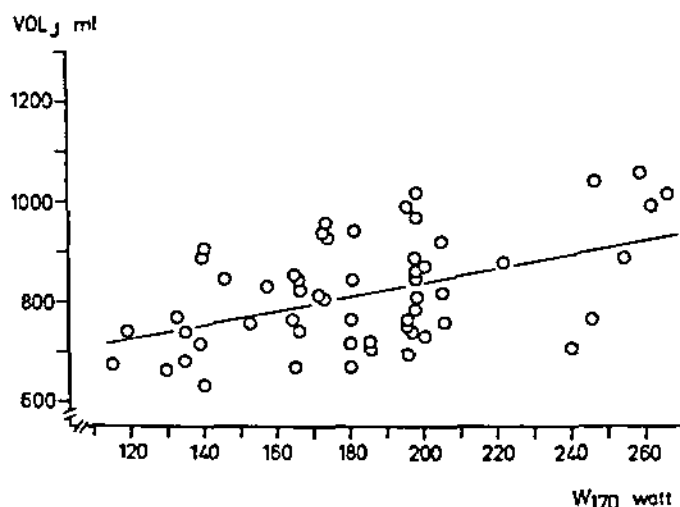


Fig 12 Relation between total heart volume and physical work capacity in young men (20–26 years)

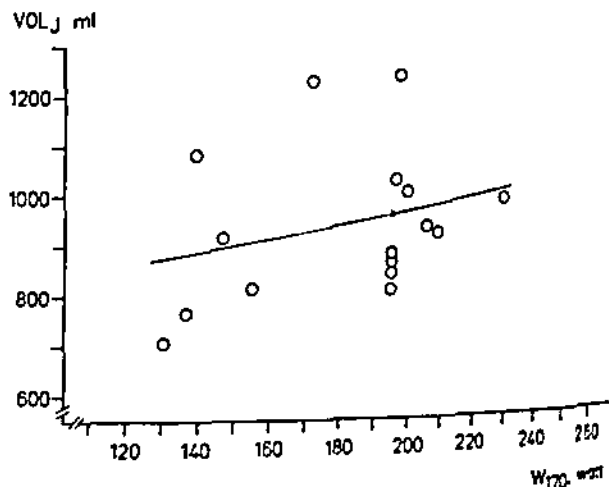


Fig 13 Relation between total heart volume and physical work capacity in middle aged men (40–45 years)

ing discussion is concentrated upon data related to this method

The stepwise regression analysis shows that the variable with the greatest explanatory value is body weight even though in young women the coefficient of correlation is remarkably low probably depending upon the combination of low body weight and high work capacity in some cases Therefore it follows that body surface area is a poorer variable for predicting the heart volume than body weight It is also worthy of note that the stepwise regression analysis indicates that measures of physical work capacity (max O_2 or W_{170}) have such low explanatory value that they are only of marginal importance as additions to body weight The simple correlation coefficient for heart volume—W_{170}—was in the order of 0 5 for young men and women and 0 30 and 0 60 for middle aged men and women respectively

In all groups the combination of the variables body weight and THb gave a correlation coefficient close to or above 0 6 in the stepwise regression analysis As a rule the addition of further variables only gave a very slight increase of the explanatory value By including many variables in the analysis a fairly high multiple correlation coefficient can be obtained but for practical routine use this would be inconvenient Even with the use of a number of variables so that the correlation coefficient reaches a value of 0 70 to 0 85 an explanatory value for the heart volume of more than 50 to 70 per cent is not achieved This is assuming the existence of a linear relationship between different variables On the other hand if the relationship between them were to

non linear this might—if correctly defined—give considerably higher degree of correlation

Thus it is not clear how to explain the variations hich lie between 30 and 50 per cent They may due to technical roentgenologic factors or to athematical reasons e g in the choice of formula in the measurement procedure The biologic var tion must also be taken into account

In two groups (young women and middle aged en) the fact that some subjects were smokers ntered as a predictive factor The implication of is is not clear Some form of co variation with nother predictive factor or factors seems probable t cannot be reasonably supposed that the smoking abits in themselves will lead to a larger heart vol me unless it is assumed that heart disease caused the smoking is present This seems unlikely es ecially in the group of young women

The stepwise regression analysis shows that body eight is a more informative variable for predicting he heart volume than body surface area Infor nation on the body weight is also more easily ob ainable than that on the body surface area which has to be calculated from a complicated formula or obtained as an approximate value from a nomogram For clinical use the heart volume therefore should be eferred to body weight instead of surface area

For scientific purposes the heart volume should e related to a number of physiologic variables (Ta le 3) in addition to body weight The most impor ant of these is total haemoglobin mass followed by measures of physical work capacity (W_{max} max O HR_{ma} or W_{170})

A slight increase of the total heart volume with increasing age was found A further analysis of this relationship will be published in a future com munication together with recommendations for techniques and reference values for different ages

SUMMARY

An acceptable method and equations for predicting the total heart volume from correlations to physiologic var iables in young and middle aged healthy persons are pre sented Body weight gives more predictive information than body surface area The use of the total hemoglobin mass and measures of physical work capacity as variables in addition to body weight will only increase the accuracy of the prediction relatively slightly

Request for reprints Dr Uno Erikson Department of Diagnostic Radiology Akademiska Sjukhuset S 750 14 Uppsala Sweden

REFERENCES

BACKLUND L and TAMMIVAARA HILTY R Gas ex changes in two male age groups in relation to in spiratory oxygen fraction physical exercise and body posture Ups J med Sci 77 (1972) 95

— BERGSTROM K ERICSSON P ERIKSON U HUIT FELDT B and RENCK H Choice of variables for pre dicting the heart volume Ups J med Sci 79 (1974) 97

BERGSTROM K ERIKSON U and GUSTAFSSON B Roentgenological determination of the heart volume Acta Soc Med upsalien 74 (1969) 81

DIXON W J (editor) Biomedical computer programs University of California Press Los Angeles 1975

ERIKSON U FRIMAN G and WEGENIUS G Heart volume determination A methodologic analysis Acta radiol Diagnosis 21 (1980) 461

JONSELL S A method for the determination of the heart size by teleroentgenography (a heart volume index) Acta radiol 20 (1939) 325

KJELLBERG S R RUDHE U and SJOSTRAND T The re lations of the cardiac volume to the weight and surface area of the body the blood volume and the physical capacity for work Acta radiol 31 (1949) 113

— LONROTH H and RUDHE U The effect of various factors on the roentgenological determination of the cardiac volume Acta radiol 35 (1951) 413

FROM THE DEPARTMENT OF DIAGNOSTIC RADIOLOGY (DIRECTOR PROF T OLIN) MALMO ALLMANNA SJUKHUS S 21401 MALMÖ SWEDEN

ANGIOGRAPHY OF THE OVARIAN ARTERY IN ADNEXAL LESIONS

S KARLSSON and K JONSSON

The diagnostic accuracy of angiography has generally improved during the past two decades but angiography still takes a subordinate place as a preoperative diagnostic method in gynecologic disorders Experience with angiography of the ovarian artery is still very limited (KAHN & FRATES 1968 FRATES 1969 LATHROP & FRATES 1970 OHLSON 1973) Therefore an attempt was made to define the advantage and limitations of ovarian angiography in patients with pelvic tumor

Material and Methods

The material consisted of 39 women aged 29 to 73 years mean 52 with a palpable pelvic tumor diagnosed at a gynecologic health control An ultrasound examination confirmed the tumor and the patients were then referred for pelvic angiography The angiographic technique has been described previously (KARLSSON & PERSSON 1979) In all cases a lumbar aortography was performed in order to obtain a general view of the vascular supply of the tumor followed by a selective angiography of the ovarian artery using the same technique as NORDMARK (1977) described for selective catheterization of the testicular artery The amount of contrast medium used in the selective series varied from 4 to 10 ml depending on the diameter of and blood flow in the ovarian artery i e on the vascularization of the tumor The films were exposed at a rate of 1 film/s for 1? seconds In 31 of the patients bilateral selective examination of the internal iliac arteries was also performed

All patients but one underwent surgery and microscopic diagnoses of the tumors were obtained

Normal anatomy

Both the ovarian arteries and adnexal branches of the uterine arteries take part of the blood supply of the tubes and the ovaries The distribution between their respective supply areas varies greatly (DUBREUIL CHAMBARDEL 1925–26 JOACHIMOVITS 1931) The ovarian artery can also take part in the blood supply of the fundus uteri (LUSCHKA 1864)

Generally the ovarian artery originates from the antero-lateral part of the abdominal aorta at the level of the second lumbar vertebra (GERARD 1913 ELISKA 1961) Most often it forms a relatively wide angle with the aorta at its origin and then takes a caudal and slightly lateral course crosses over the ureter and enters the pelvis superimposed on the sacroiliac joint It enters the upper external angle of the broad ligament where it divides into its terminal branches the ovarian and tubal branches These as a rule anastomose with the corresponding terminal branches of the uterine artery In the lower lumbar and pelvic parts the ovarian artery has a typical tortuous course (Fig 1)

Submitted for publication 6 September 1979

Results

Forty one ovarian arteries were examined and of these 37 originated from the antero lateral part of the aorta at a level varying from the upper margin of L2 to the lower part of L3 In 4 cases it originated from a renal artery In one of these the ovarian artery branched off from the left renal artery 1 cm from the aorta In 3 cases it originated from a rightsided lower pole renal artery Totally 20 left and 21 right ovarian arteries were catheterized

The diameter of these arteries measured on aortography films with a 10 times magnifying lupe varied between 1 0 and 3 5 mm When selective ovarian angiography of the same vessels was performed the diameter was always slightly increased

Nine of the patients had bilateral tumors in 8 of these only the side with the wider ovarian artery was catheterized

Malignant tumors Twenty nine ovarian arteries were examined in 28 cases of malignant tumors (Table) 22 being carcinomas 4 teratomas and 2 metastases from an adrenal malignant tumor of lipoid cell type

Pathologic vessels i e irregular with varying caliber and often with an advanced corkscrew appearance existed in 26 tumors while 2 of the malignant cystic teratomas had no such vessels The vascularity of the malignant tumors was rich in 6 cases medium in 16 and poor in 6

In one case only was the whole tumor distinctly outlined (Fig 2) In the remaining cases only part of the tumor was demonstrated via ovarian angiography and an exact estimation of the size and shape of the tumors was therefore not possible Nor was it possible to differentiate between solid and cystic malignancies with the aid of angiography (Fig 3)




Fig 1 Normal ovarian angiography in a 48 year-old woman Tubo ovarian branches (→) Ovarian branch of the uterine artery filled in retrograde direction (↔)

Four cystic malignant teratomas were all sparsely vascularized with narrow vessels running along the cyst wall and only 2 of these had pathologic vessels in part of the tumor (Fig 4) The ovarian vein was filled in 16 of the 28 malignant tumors but this did not increase the diagnostic information In no case was an evident early filling of the ovarian vein observed

Benign tumors and normal ovaries In 7 patients no malignant tumor was present Four of these

Table

Angiographic findings in ovarian lesions

	Malignant tumors	Benign cysts and normal ovaries	Inflammatory lesions
No of tumors	28	7	4 (+1)
Tumor size (cm)	2–20	3–12	3–6
Diameter of ovarian artery (mm)	1 0–3 0	1 0–3 5	1 0–2 5
Pathologic vessels	26	0	4 (+1)
Accumulation of contrast medium	28	0	4 (+1)
Early arteriovenous shunts	9	0	4 (+1)
Filling of ovarian vein	16	2	2 (+1)



a



b

Fig 2 65-year-old woman with encapsulated and lobulated cyst adenocarcinoma of the left ovary measuring 5 cm × 8 cm Retrograde filling of intramural vessels in left uterus (→)



a




b

Fig 3 Solid adenocarcinoma of the right ovary in a 59-year-old woman The tumor is richly vascularized but in spite of this not distinctly outlined



a



b

Fig 4 30 year-old woman with large malignant cystic teratoma of the left ovary a) Early b) late arterial phase Although the tumor is partly richly vascularized no evaluation of its size and possible



a



Fig 5 Pedunculated myoma in a 33-year-old woman a) Iliac angiography b) Ovarian angiography (subtraction) Slightly enlarged uterus very richly vascularized (→) the myoma close to the right uterine cornu less filling of tubo-ovarian



Fig 6 Woman aged 55 with an enlarged uterus 18 cm in diameter The right ovarian artery supplies part of the large myomatous uterus

proved to have normal ovaries at surgery but all had myomas 2 of these being stalked and at palpation considered as being malignant ovarian tumors These myomas could all be correctly diagnosed with bilateral selective internal iliac angiography (Fig 5) One myomatous uterus had a diameter of 18 cm The normal ovary and tube were stretched over the right cranial surface of the uterus and the 3 mm wide right ovarian artery took a considerable part of the blood supply of the uterus (Fig 6) The remaining 3 patients had a 4 cm dermoid cyst a 6-cm endometrioid cyst and a 12 cm simple cyst respectively

None of the benign cysts or normal ovaries had pathologic vessels The ovarian artery had the same diameter as in cases of malignant tumors The ovarian vein was filled in 2 of these cases In no case was the tumor or ovary demonstrated to a degree which allowed an estimation of the size or shape

Inflammatory lesions were found in 5 patients including one patient with a 2 cm ovarian metastasis from an adrenal tumor in combination with a 3 cm×4 cm sactosalpinx (Fig 7) One had a 5 cm abscess one an 8-cm sactosalpinx and the 2 remaining patients had sactosalpinxes measuring 4 cm×6 cm and 3 cm×4 cm respectively The latter 2 also had cystic ovaries measuring 8 cm and 6 cm in diameter respectively (Fig 8)

The vascularity had the same appearances as those observed in malignant cases but often with a richer vascularity and a more blurred appearance Arteriovenous shunting within the tumors was demonstrated in all cases with inflammatory lesion Filling of the ovarian vien was observed in 2 cases

Discussion

Both the ovarian and uterine arteries have to be examined for the angiographic diagnosis of gynecologic tumors and the catheterization must be as selective as possible in order to improve the demonstration of small arterial branches

Previously aortography was the standard angiographic method used in the diagnosis of adnexal lesions The results were poor (BORELL et coll 1952 BORELL & FERNSTROM 1953 1954 FERNSTROM 1955 PFEIFFER & BARKE 1960 MARANTA et coll 1964 SMITH 1971) With bilateral selective internal iliac angiography the diagnostic information improved (ALTEMUS 1969)

The value of selective catheterization of the ovarian artery in cases of pelvic tumors was pointed out by KAHN & FRATES FRATES examined 10 patients with 12 selective ovarian angiographies and recommended the method whenever pelvic angiography was indicated for the evaluation of gynecologic diseases

LATHROP & FRATES described selective ovarian angiography as a useful refinement in demonstrating various forms of trophoblastic disease

Malignant tumors Of 28 malignant tumors including the small metastasis combined with sactosalpinx 26 had an evident neo vascularity (Table) The 2 tumors without pathologic vessels were large and cystic lesions with malignant excrescences in a very limited part of the tumor In the capillary phase all malignant tumors had an accumulation of contrast medium within the tumor although a heavy accumulation occurred in only 6 cases and even in these cases only within a small part of the tumor It must be emphasized that in only one case (Fig 2) this accumulation demonstrated the whole circumference of the tumor

An early shunting to the veins within the tumors occurred in 9 of the 28 malignant tumors T



a



b

Fig 7 Sactosalpinx and ovarian metastases in a 29 year old woman a) Early b) late arterial phase Retrograde filling of the right uterine marginal artery (→) and the arcuate ramus (↔) Even the left uterine marginal artery is filled (↔) The hypervascularized sactosalpinx and small metastasis cannot be differentiated (↔)



a



b

Fig 8 Woman aged 36 with 6 cm ovarian cyst and sactosalpinx Ovarian angiography The cyst (→) is avascular the sactosalpinx (↔) hypervascular In late arterial phase retrograde filling of left uterine half (↔)

reasons for the relative hypovascularity even in cases of solid adenocarcinomas are probably degeneration and necrosis

Benign tumors and normal ovaries As mentioned it has been claimed that the ovarian artery can also take part in the blood supply of the fundus uteri FERNSTROM described one case of a uterus with a diameter of about 10 cm Both uterine arteries were displaced laterally in their course along the lateral margins of the uterine corpus Otherwise no information of diagnostic value was obtained He assumed that part of the blood supply of the myomatous uterus was derived from the ovarian artery One case (Fig 6) in the present series proves that such a blood supply is possible At operation the ovary as well as the tube were normal Thus a tumor supplied by an ovarian artery does not necessarily mean that the tumor is of ovarian or tubal origin

Several cases of pedunculated myomas are erroneously considered at palpation as malignant ovarian tumors With selective bilateral internal iliac angiography the diagnosis of extrauterine masses versus uterine ones is possible (ALTEMUS) with an additional selective ovarian angiography the diagnosis is certain (Fig 5)

In benign cystic tumors in the capillary phase of internal iliac angiography occasionally a thin rim of contrast medium is observed in the capsule of the tumor (KARLSSON & PERSSON 1980) Such a rim was not demonstrated in any of the benign tumors in the present series of selective ovarian angiography Neither benign lesions nor normal ovaries were well outlined and angiography alone did not give information about the size or shape of the tumours

Inflammatory masses In the present material it was not possible to differentiate between malignant and inflammatory lesions An early venous shunting within the lesion occurred in all inflammatory cases compared with one third of the cases with malignant tumors The hypervascularity was more evident in inflammatory lesions with a heavy accumulation of contrast medium in the capillary phase However both cases of sactosalpinx in combination with simple cysts could be erroneously considered as lobulated malignant tumors

Evidently the early arteriovenous shunting is not a reliable sign of malignancy and hypervascularity is not pathognomonic of malignant tumors (LAGERGREN et coll 1958)

Ultrasound is of great importance in the topographic evaluation of pelvic tumors but of little support in the differential diagnosis between malignant and benign tumors Selective angiography of the ovarian artery is a valuable complement to selective internal iliac angiography in the diagnosis of ovarian and tubal lesions and further enhances the possibilities of differentiating extrauterine masses from uterine FRATES assumed that when the ovarian artery as observed at aortography measured 1 5 mm or more in diameter it was abnormal and should be selectively examined It appears that this limit should rather be 1 0 mm and that even then the selective catheterization of the ovarian artery should not offer great difficulty It should be performed as a complement to selective internal iliac angiography

However a wide ovarian artery is as shown in the present material not pathognomonic for adnexal pathology but a clear indication of an attempt at selective catheterization of the vessel

The limitations of angiography of gynecologic tumors is the complicated blood supply of the ovaries and tubes The vascular supply of hypovascularized tumors such as benign simple cysts may not be demonstrated

The combination of ultrasound and pelvic angiography is proven to be reliable in the evaluation of gynecologic lesions (KARLSSON & PERSSON 1979) and can therefore be recommended preoperatively Selective ovarian angiography enhances the possibilities for a correct preoperative diagnosis

SUMMARY

Selective catheterization of the ovarian artery was performed in 39 women with pelvic tumor Previously the combination of ultrasound and bilateral selective internal iliac angiography was proven to be valuable in the evaluation of gynecologic lesions The present series demonstrates that selective ovarian angiography still enhances the possibilities for a correct preoperative diagnosis

REFERENCES

ALTEMUS R Differentiating uterine and extrauterine masses by bilateral selective hypogastric arteriography Radiology 92 (1969) 1020

BORELL U and FERNSTRÖM I The adnexal branches of the uterine artery An arteriographic study in human subjects Acta radiol 40 (1953) 561

— — The ovarian artery Acta radiol 42 (1954) 253

— — LINDBLOM K and WESTMAN A The diagnostic

value of arteriography of the iliac artery in gynecology and obstetrics Acta radiol 38 (1952) 247

DUBREUIL CHAMBARDEL L Traite des variations du systeme arteriel Masson et Cie Paris 1925–26

ELISKA O Venae et arteriae spermaticae a Jejich Variabilita (In Czech) Čs Morfol 9 (1961) 200

FERNSTROM I Arteriography of the uterine artery Acta radiol (1955) Suppl No 122

FRATES R Selective angiography of the ovarian artery Radiology 92 (1969) 1014

GERARD G Sur les variations d origine et de nombre des arteres genitales spermatiques ou ovariennes de l homme C R Soc Biol (Paris) 74 (1913) 778

JOACHIMOVITS R Varietaten der Anastomosen zwischen Arteria ovarica and Arteria uterina Arch Gynak 147 (1931) 697

KAHN P and FRATES R The value of angiography of the small branches of the abdominal aorta Amer J Roentgenol 102 (1968) 407

KARLSSON S and PERSSON P H Angiography ultrasound and fine needle aspiration biopsy in the evaluation of gynecologic tumors Acta radiol Diagnosis 20 (1979) 779

— — Angiography in uterine and adnexal tumors Acta radiol Diagnosis 21 (1980) 11

LAGERGREN C LINDBOM Å and SODERBERG G Hypervascularization in chronic inflammation demonstrated by arteriography Acta radiol 49 (1958) 441

LANG E Arteriography in gynecology Radiol Clin N Amer 5 (1967) 133

LATHROP J and FRATES E Selective ovarian angiography in trophoblastic disease Obstet and Gynec 35 (1970) 844

LUSCHKA H Die Anatomie des menschlichen Beckens Verlag der H Lauppschen Buchhandlung Tubingen 1864

MARANTA E CAMPONOVA F und DEL BUONO M S Die Beckenangiographie Fortschr Rontgenstr 101 (1964) 229

NORDMARK L Angiography of the testicular artery I Method of examination Acta radiol Diagnosis 18 (1977) 25

OHLSON L Non pregnant anatomy of the posterior abdominal wall as reflected in the course of the ovarian vessels and the ureter Acta radiol Diagnosis 14 (1973) 145

PFEIFFER J und BARKE R Angiographie der Beckengefasse Fortschr Rontgenstr 93 (1960) 787

SMITH R S Pelvic arteriography in the differential diagnosis of pelvic mass Amer J Obstet Gynec 111 (1971) 952

FROM THE DEPARTMENT OF DIAGNOSTIC RADIOLOGY KAROLINSKA SJUKHUSET S 10401 STOCKHOLM SWEDEN

RADIOLOGIC LOW-DOSE PELVIMETRY

Indications and pelvimetry data

HANS OHLSÉN

Radiologic pelvimetry is the only simple method for accurate determination of all the conventional pelvic diameters Many methods have been described especially concerning the evaluation of the distal part of the pelvis According to RUSSEL (1973) the most comprehensive evaluation of pelvimetry was made by BORELL & FERNSTRÖM (1960) who analysed close to 50 single or combined measurements in almost 400 deliveries in patients with small pelvic dimensions selected from more than 3 000 pelvimetries The result of this analysis constituted the basis for the simple orthodiagraphic technique now commonly used in Sweden after modifications by BORELL & RÅDBERG (1964) and DIEHL & FERNSTRÖM (1966) The modified pelvimetry employing a low dose technique with rare earth screens entails a mean absorbed dose to the maternal ovaries (considered to be located inside the primary closely coned lateral radiation field) of 0 9 mGy and a total fetal gonad dose in vertex presentation of 0 01 mGy (AXELSSON & OHLSÉN 1979)

Notwithstanding the reduced radiation doses with a consequent lowering of the risk to the fetus and mother the efficacy of pelvimetry has been questioned by some authors (HANNAH 1965 MCGRUDER 1968 RUSSEL & RICHARDS 1971 KELLY et coll 1975) Meanwhile the incidence of pelvimetries has increased Recommendations to widen the indications to include for instance not only primigravidae but also multigravidae with breech presentation have been proposed (ROVINSKY et coll 1973)

The aim of the present work was to determine actual mean values of pelvic diameters and the correlation between them comparing the incidence of contracted pelvis and the indications for pelvimetry in later years with those of an earlier period (1940–1957) at this hospital A further aim was to evaluate the efficacy in selecting patients with contracted pelvis by clinical palpation in the routine work On the basis of these results and with consideration paid to the radiation dose a re-evaluation of the clinical application of radiologic pelvimetry was intended

Technique

The following standard technique was used

A lateral film was exposed with the patient in erect position with field size 24 cm×24 cm and with a centimeter ruler in the midplane of the patient The reference points of the sagittal diameter of the inlet (SI) were the upper dorsal part of the symphysis and the nearest point of the sacrum which often was the promontory (obstetric conjugate) The sagittal diameter of the outlet (SO) was measured from the lower dorsal border of the symphysis to the lower tip of the sacrum or if no joint existed between the sacrum and the coccyx to the tip of the coccyx

An antero posterior orthodiagraphic film was exposed in supine position with two fields of 5 cm×15 cm and a 5 cm tube shift to each side from the midline between the two exposures The central ray was directed about 22 5 towards the head of the patient projecting the ischial spines within the obturator foramina The film cassette was placed directly

Submitted for publication 31 October 1979

Table 1

Mean values of the pelvic diameters and defined limits for con traction and borderline in vertex presentation with normal si e of the fetal head Figures in centimeters

Pelvic diameter	Abbrevia tion	Mean	Contrac tion	Border line
Sagittal inlet	SI	12	<10	10–11
Transverse inlet	TI	13½		
Sum of inlet	ΣI			23
Interspinous	IS	10½	<8	
Intertuberous	IT	11½		
Sagittal outlet	SO	12	<9	
Sum of outlet (IS+IT+SO)	ΣO		<29 5	29 5–31 5

* Solitary measurements irrespective of the ΣO

Table 2

Number of pelvimetries at different periods between 1966 and 1977 compared with the period 1940 to 1957 at this hospital

Year	Period	Deliveries	Pelvimetry	
			No	Per cent
1940 to 1957 (Borell & Fernstrom)		38 711	3 223	8
1966 to 1969	P I	9 005	1 161	13
1973 to 1974	P II	5 122	787	15
1976 to 1977	P III	4 200	777	19

under the patient The interspinous (IS) and inter tuberous (IT) diameters were directly measured on the film without geometrical correction The widest transverse diameter of the inlet (TI) was directly measured and corrected by subtraction of one mil limeter for each centimeter by which the diameter exceeded 10 cm

When pelvimetry was performed during delivery the position of the fetal head including rotation de gree of flexion or deflexion was determined accord ing to BORELL & FERNSTRÖM (1967) For evaluating the degree and type of moulding of the fetal head a complementary film over the head with the central ray directed 10° towards the feet was performed in rare instances

The limits for pelvic contraction and borderline measurements in vertex presensation with a normal sized fetal head according to BORELL & FERNSTRÖM (1960 1967) BORELL & RÅDBERG and FERNSTRÖM (1968) are given in Table 1

Table 3

Pelvimetry data in control cases selected from period P III Number of controls for the inlet diameters 362 and for the outlet diameters 490

Pelvic diameter	Controls		
	Mean	SD	SEM
SI	12 2	1 0	0 051
TI	13 8	0 8	0 044
ΣI	26 0	1 4	0 072
IS	10 5	0 8	0 034
IT	11 6	1 0	0 043
SO	11 9	1 0	0 045
ΣO	34 0	2 0	0 089

Table 4

Correlation coefficients between the pelvic diameters in 777 pelvimetries

	SI	TI	ΣI	IS	IT	SO	ΣO
SI	–						
TI	0 12	–					
ΣI	0 79	0 71	–				
IS	0 03	0 55	0 36	–			
IT	0 06	0 36	0 27	0 67	–		
SO	0 38	0 19	0 39	0 13	0 13	–	
ΣO	0 23	0 50	0 48	0 79	0 80	0 57	–

Material and Methods

All pelvimetries at this department during three periods have been analysed (Table 2) The same method of pelvimetry was used in all three periods For the first period 1966 to 1969 (P I) only the incidence of pelvimetry was calculated for the sec ond period 1973 to 1974 (P II) pelvimetry data were calculated manually and therefore only used in some calculations defined in the following test for the third period 1976 to 1977 (P III) basic pelvimetry data were inserted into a statistical computer pro gram (STATPAC)

For analysis the material P III was divided into cases with and cases without clinically considered contracted pelvis All cases without contracted pel vis at a clinical evaluation will subsequently be re ferred to as controls In the control group when evaluating the pelvic inlet the following cases were excluded patients referred for pelvimetry because

Table 5

Incidence of contraction and borderline in relation to presentation of the fetus

Pelvic capacity	Type of presentation: Vertex n (=672)	Vertex Per cent	Breech n (=105)	Breech Per cent	All pelvimetries n (=777)	All pelvimetries Per cent	Incidence of contracted pelvis in relation to: All 4 200 deliv (per cent)	All women (per cent)
Vertex presentation								
Inlet contraction	5[b]							
SI<10					15	1.9	0.4	~0.4
Outlet contraction	10[a,c]							
ΣO<29.5		12.5						
Inlet borderline	5[b]							
SI 10–11 & ΣI<23					69	8.9	1.6	~8
Outlet borderline	64[d]							
ΣO 29.5–31.4								
Normal	588	87.5						
Breech presentation								
Inlet contraction			13					
SI<11.5				34.3	36	4.6	0.9	~0.9
Outlet contraction			23					
ΣO<32.5								
Normal			69	65.7				

[a] 1 case also inlet contraction
[b] 2 cases also outlet borderline
[c] 1 case also inlet borderline
[d] 2 cases also inlet borderline

of a mobile fetal head above the inlet or bulging above the symphysis on palpation patients with a previous complicated delivery or with signs of disproportion during labour and patients with a possible contracted outlet on palpation When evaluating the outlet in the control group the same cases were excluded as for the inlet except for cases referred for pelvimetry because of a mobile head above the inlet on palpation

Standard statistical methods were used and the mean values standard deviation (SD) and standard error of mean (SEM) were calculated for all pelvic diameters The probability (p) of significant differences was calculated by Student s t test or the χ^2 test

Results

Pelvimetry data The mean values for the pelvic diameters in the control group are given in Table 3

The pelvic diameters were cross-correlated (Table 4) All combinations were significantly correlated in some way because of the large number of observations and a common factor in each patient unknown but possibly a genetic one A correlation coefficient merely being significantly separated from zero does not mean that the statistical connection is of clinical interest The correlation coefficient should be of such a magnitude that the fraction of the part explained by the other factor becomes important preferably over 50 per cent The square product of one coefficient (r^2) statistically called coefficient of determination (STEEL & TORRIE 1960) gives the percentage of the statistical variation explained by the compared variable (factor) For clinical reasons therefore correlation coefficients of about $r=0.7$ or more were considered to imply a significant correlation of clinical interest

The highest correlation coefficient between single diameters was found between the interspinous (IS) and intertuberous (IT) diameter namely $r=0.67$ or r^2 0.45 No correlation between the diameters of the inlet and those of the outlet was found but a tendency to correlation was found between the transverse diameter of the inlet (TI) and the sum of the outlet

diameters (ΣO=IS+IT+SO) and especially the IS included in the ΣO The correlation coefficient be tween the sum of IS and IT and the whole sum of the outlet diameters (ΣO) was 0 88

The incidence of contraction and borderline measurements in vertex presentation (applying the limits given in Table 1) was 12 5 per cent (Table 5) In term breech presentations abnormal pelvic meas urements were found in together 34 3 per cent with the limits 11 5 cm for SI and 32 5 cm for ΣO These limits have been suggested for cases in which the fetal weight is estimated to be 3 000 to 3 500 g (OHLSÉN 1974) Using these limits abnormal dia meters were found in 15 4 per cent of all pelvimet ries

Incidence figures for pelvic contraction in the whole fertile female population were calculated on the assumption that radiographic pelvimetry had been performed in practically every case with con tracted pelvis in some cases after a difficult delivery only The overall incidence of contraction in vertex presentation was estimated to be approximately 0 4 per cent Contracted outlet was twice as common as inlet contraction (Table 5) The overall incidence of borderline measurements in vertex presentation was estimated to be about the same as in the control group 8 per cent Borderline measurements were much more common in the outlet than in the inlet The overall incidence of abnormal diameters in the whole fertile female population with breech presen tations was estimated to be about the same (0 9 per cent) as that calculated when related to all de liveries This was possible since the number of breech presentations examined by radiographic pel vimetry corresponded to an incidence of 2 5 per cent of all deliveries i e only a little less than the normal incidence of breech deliveries

Subnormal measurements of a single diameter of the outlet in cases with a sum of the three diameters above borderline (ΣO≥31 5) are given in Table 6 Subnormal measurements of either the IS or SO were present in two of 777 cases according to the criteria given in Table 1 Of 1 564 pelvimetries (P II+P III) the IS was less than 8 0 cm in one case and less than 8 5 cm in 12 cases in all these 12 cases ΣO was below 31 5

The types of contracted outlet were evaluated in 31 cases with ΣO less than 30 0 in 1 564 pelvimetries Two main types were present a general type with small measurements (defined as less than the mean value subtracted by 2 SD of all three diameters (14

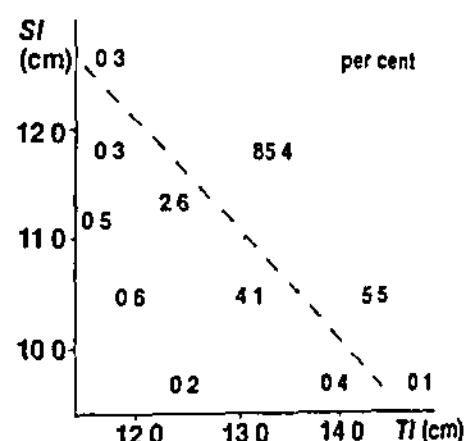


Fig 1 Relation between the diameters of the inlet (SI TI ΣI=SI+TI) in 1 564 pelvimetries (PII+PIII) ΣI less than (– –) ΣI less than 23 ( )

Table 6

Number of cases with small measurements of a single diameter in the outlet together with a sum of outlet above borderline (ΣO≥31 5)

Pelvic diameter		All cases n (=777)	Sum of outlet (ΣO≥31 5) n (=690)
IS	<8 0	0	–
	<8 5	7	0
	<9 0	29	6
IT	<8 5	0	–
	<9 0	5	0
	<9 5	18	[illegible]
	<10 0	35	8
SO	<9 0	[illegible]	1
	<9 5	4	[illegible]
	<10 0	16	10

cases) and a transverse type with small measur ments in the two transverse diameters (16 cases) only one case was the low ΣO the result of a sm SO (9 4 cm) together with transverse diameters ju above 10 cm

The anthropoid type of the pelvic inlet accordi to CALDWELL & MOLOY (1938) defined as TI le than SI was present in 53 of 777 cases (7 per cent In these cases the lowest value of SI was 1? 0 c and in only one case was ΣI below 24 The me value of ΣI (26 2 cm) in anthropoid cases did n significantly differ from the mean value in the co trol group without palpatory evidence of contracti inlet

The anthropoid type of inlet was found to be co

Table 7

Indications for pelvimetry during period P III in comparison with the period 1940 to 1957 (BORELL & FERNSTROM) at this hospital The change of relative incidence related to the number of deliveries between period 1940 to 1957 and period P III is given as a numeral factor

Indications	1940 to 1957 n=3 293 (per cent)	Period 1976 to 1977 P III n=777		Change factor
		First indic n=742 (per cent)	First + second indic n=870 (per cent)	
Complicated previous delivery	12	4 3	4 0	0 8
Possible disproportion between fetus and pelvis during labour	20	4 1	3 9	0 4
Small outlet on palpation	–	21 1	20 2	–
Mobile fetal head above the inlet	20	19 1	20 4	2 0
Small external conjugate	11	–	–	–
Breech presentation	6	15 1	13 2	5 4
Elderly primagravida (≥35 years)	5	5 5	5 1	3
Prolonged period of infertility	3	2 7	3 1	1 9
Other indications (post maturity before oxcytocin stim toxicosis diabetes before lumbar anesthesia heart failure pelvic fracture small patient anxious patient etc)	23	8 1	30 1	2 6
Total	100	100	100	

related to small outlet measurements especially to a small IS Contraction or borderline measurements of the outlet (ΣO<31 5) was present in 28 per cent of the cases of the anthropoid type as compared with 8 per cent in the control group ($p<0\ 001$) and 22 per cent in cases with palpatory evidence of contracted outlet (not significant)

From a clinical point of view it would appear important to find out the incidence of cases in which a small TI coexisting with a normal SI implied a risk for disproportion between the fetus and the pelvis Cases with TI less than 12 0 cm SI equal to or greater than 11 0 cm and ΣI less than 24 were selected This means an anthropoid like configuration or a projected area of the inlet below average with a normal SI Of 1 564 pelvimetries 12 cases (0 8 per cent) fulfilled these criteria (Fig 1) Further analysis of these 12 cases showed that 8 of them also had small outlet measurements (<31 5) while 3 had ΣO just above 31 5 and one an ΣO of 33 2

Indications Indications for pelvimetry were retrospectively collected from the radiologic records In 35 cases (4 5 per cent) no information was available Two or more indications were present in 128 cases (16 5 per cent) and the apparently most important was classified first (Table 7) The most common indication was possible contracted outlet on palpation most often equivalent to a small IT according to GREENHILL (1960) this was present in about 20 per cent of the cases The indication of a mobile fetal head above the inlet or in a few cases a fetal head bulging above the symphysis was of the same frequency as the indication of a small IT in most cases with a mobile fetal head the pelvimetry was performed before labour had started The third most frequent indication was breech presentation (13 per cent) two thirds of these were primigravidae

Since the frequency of pelvimetries had increased during the last few decades the incidence of the indications was also related to the total number of deliveries The relative variation of incidence for each indication between the period 1940 to 1957 and period P III could be expressed by a factor given in Table 7

Efficacy of palpation in predicting a narrow pelvis A mobile fetal head above the inlet or the symphysis was used as the palpatory criterion for possible inlet contraction A small IT or in a few cases a small SO on palpation was in the same way used as the criterion for possible outlet contraction The mean values of the pelvic diameters in such cases were smaller than those in the controls ($p<0\ 001$)

except for the SO where the difference was less significant ($p<0.01$) probably because of the small number of cases referred for pelvimetry with a small SO (Table 8)

The diagnostic accuracy of palpation can be statistically presented as defined in Tables 9 and 10 As no difference between the periods P II and P III was found the two periods were combined for the analysis In 312 cases with possible contracted outlet on palpation a narrow outlet defined as contraction or borderline ($\Sigma O<31.5$) was found in 22 per cent of the cases which corresponds to the Predictive value of a positive test (PV pos) according to VECCHIO (1966) χ^2 test analysis revealed a highly significant ($p<0.001$) difference in the incidence of a narrow outlet between the group with possible contraction on palpation and the controls

Out of the 298 cases with a mobile head above the inlet a contracted inlet was found in 8 cases (PV pos=3% Table 9) The χ^2 test showed no significant difference in the incidence of a narrow inlet between the group with a mobile head above the inlet and the controls

Discussion

The clinical application of radiologic pelvimetry is dependent on several factors the accuracy of the radiologically defined narrow pelvis in predicting the outcome of the delivery the clinical efficacy in selecting patients with a narrow pelvis for pelvimetry the radiation dose and socio-economic aspects All these factors have to be weighed against the risk of a complicated delivery in case of unexpected dystocia From the obstetric viewpoint the risk associated with contracted outlet is considered to be greater than that of contracted inlet since the latter is detected earlier in labour and appropriate measures can be decided upon more easily

Prognostic value of radiologic pelvimetry In the early era of radiologic pelvimetry the shape of the pelvic inlet (CALDWELL & MOLOY STEER 1959) and the sub pubic angle (NICHOLSON 1938 MORRIS 1947 GILLANDERS 1959) was considered important Different indexes for the inlet and the so-called mid pelvis were recommended (e g COLCHER & SUSSMAN 1944 ALLEN 1947 MOIR 1949 SNOW 1949) The prognostic value of these indexes were evaluated by BORELL & FERNSTRÖM (1960) in a large series For the pelvic inlet the SI alone was the best prognostic parameter being better than

Table 8

Pelvimetry data in cases with suggested contraction on palpation for the inlet a mobile fetal head above the inlet for the I[illegible] and IT a small IT or unspecified outlet contraction for the SO [illegible] small SO on palpation for the ΣO a small IT or SO or unspecified outlet contraction on palpation

Pelvic diameter	Suggested contraction No	Suggested contraction Mean	Controls (Table 3) Mean	Statistical t test	Statistical p
SI	178	11 8	12 2	4 6	<0 001
TI	178	13 5	13 8	3 7	<0 001
ΣI	178	25 3	?6 0	5 7	<0 001
IS	160	10 2	10 5	4 9	<0 001
IT	160	11 0	11 6	6 4	<0 001
SO	15	11 3	11 9	3 0	<0 01
ΣO	171	33 0	34 0	5 8	<0 001

Table 9

Efficacy of palpation in predicting a narrow pelvis Cf also Table 10

Type of test	Definition (Table 10)	Suggested contraction: Inlet (Mobile head above inlet) No	Inlet Per cent	Outlet (Small IT or SO) No	Outlet Per cent
Sensitivity	$\frac{a}{a+b}$	$\frac{8}{19}$	(4?)	$\frac{69}{139}$	50
Specificity	$\frac{d}{c+d}$	$\frac{683}{973}$	70	$\frac{857}{1\ 100}$	78
PV pos	$\frac{a}{a+c}$	$\frac{8}{298}$	3	$\frac{69}{31?}$	[illegible]
PV neg	$\frac{d}{b+d}$	$\frac{683}{694}$	98	$\frac{857}{9?7}$	9?
False pos	$\frac{c}{c+d}$	$\frac{290}{973}$	30	$\frac{243}{1\ 100}$	[illegible]
False neg	$\frac{b}{a+b}$	$\frac{11}{19}$	(58)	$\frac{70}{139}$	50
Prevalence	$\frac{a+b}{a+b+c+d}$	$\frac{19}{99?}$	2	$\frac{139}{1\ ?39}$	11
χ^2 test		1 3 =not signif		49 5= $p<0.001$	

PV=Predictive Value of a positive/negative test (VECCHIO 1966)

Table 10

The four subgroups a–d were defined as follows narrow inlet=SI<10 or SI 10–11 and ΣI<23 narrow outlet=ΣO<31 5

	Indication for pelvimetry		Total
	Suggested contraction	No indication of contraction (controls)	
arrow pelvis at pelvimetry	a	b	a+b
ormal pelvimetry	c	d	c+d
otal	a+c	b+d	a+b+c+d

ombined measurements or evaluations of the hape For the pelvic outlet the sum of posterior ntertuberous and sagittal diameters was a good rognostic tool but an even better prognostic value as achieved when the interspinous diameter was dded (IS+IT+SO=ΣO) The distal part of the pel is including the mid pelvis should be regarded as functional unit (KALTREIDER 1954 BORELL & ERNSTRÖM 1960 OHLSÉN 1973) termed the outlet

However in spite of the results of BORELL & ERNSTRÖM (1960) other methods and combina ions of measurements with possibly less prognostic ccuracy and sometimes higher radiation doses are ometimes used in several countries RUSSEL said hat the best method is probably the one to which he user is accustomed an opinion which is ques ionable if the method used has less prognostic effi acy or gives higher radiation doses

In a few reports the usefulness of pelvimetry in he management of labour have been questioned HANNAH found the management being based on pelvimetry in only 5 per cent of cases but the evaluation can be criticized from the fact that the pelvimetry comprised only a lateral film so that the transverse diameters were unknown MCGRUDER found the pelvic measurements inadequate in 12 of 140 cases in all these cases clinical evidence of contraction was present In a further 29 cases with clinically possible contraction radiologic pelvimetry was normal however 8 of these led to cesarean section The author concluded that radiologic pel vimetry is rarely indicated RUSSEL & RICHARDS found a fourfold increase of forceps delivery in the pelvimetry group and that the proportion of forceps delivery was equal irrespective of whether the sum of IT and SO was above or below the mean value

KELLY et coll reporting on a cooperative series of 4 600 pelvimetries from 16 hospitals pointed out that if pelvimetry helps to provide an early and accurate diagnosis of disproportion between the fetus and pelvis the labour time before cesarean section should be shorter in the pelvimetry group However no such difference was found between women with disproportion (not further specified) in whom pel vimetry (1 008 cases) was performed and those with disproportion who had not been subject to pel vimetry (219 cases) The authors also made an evaluation of the prognostic value of the finding of a normal pelvimetry in this group 27 per cent nonetheless were delivered by cesarean section Of all patients undergoing cesarean section 41 per cent had been submitted to pelvimetry These authors conclude that because of the significant risk for cesarean section even when pelvimetry is normal the clinician still has to decide on clinical grounds the management of the labour

In some of these reports as well as in several others the rate of forceps delivery or cesarean sec tion is used as an indicator of disproportion between the fetus and the pelvis However it would seem that careful obstetric pediatric evaluation of each case e g concerning the fetal morbidity or mortality as a possible consequence of disproportion between the fetus and the pelvis would be more desirable

At this hospital the indications for elective cesarean section e g in borderline cases have be come successively more liberal during the past two decades For this reason it seemed useless to try to evaluate the prognostic value of the criteria for nar row pelvis in vertex presentation as suggested by KELLY et coll The recent material does not contain a sufficient number of complicated vaginal deliveries with a narrow pelvis to permit reliable statistical conclusions Therefore the results from older series had to be used A reliable prospective analysis of the outcome including the long term prognosis in bor derline cases with vertex presentation will primarily require that all patients with borderline pelvis be known and that a trial of labour to normal delivery be performed in most cases

Incidence of pelvic contraction The incidence of contraction varies considerably in different reports partly due to different criteria used for contraction and partly due to different methods of examination Because of disparities in the selection of patients for pelvimetry only figures related to the total number of deliveries can be compared

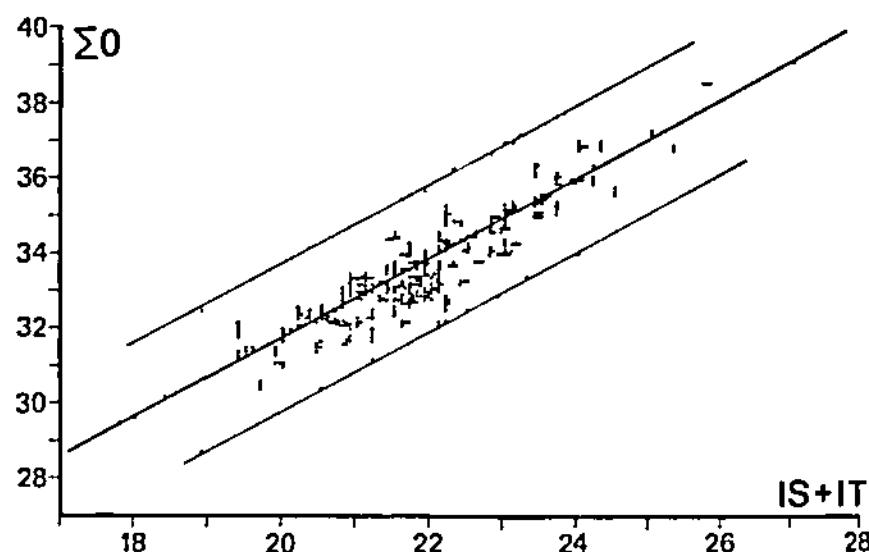


Fig 2 Correlation between the sum of interspinous and intertuberous (IS+IT) diameters and the sum of outlet (ΣO=IS+IT+SO) in 777 cases Linear regression ΣO=10 31+1 07 (IS+IT) 95% confidence interval indicated

Concerning the pelvic inlet most authors use the same definition for contraction namely SI below 10 cm In the present series the incidence of SI less than 10 cm was 0 13 (0 09–0 14) per cent from the three periods as compared with the 0 21 per cent reported by BORELL & FERNSTRÖM for the period 1940 to 1957 ($p<0\ 05$) However BORELL & FERNSTRÖM also reported a sharp decline in the number of cases with contracted pelvis after 1947 a decrease almost certainly due to antirachtitic prophylaxis Therefore the incidence in the period 1950 to 1957 was calculated from that material This incidence of 0 05 per cent was almost significantly ($p<0\ 05$) lower than the incidence of 0 13 per cent in the present series A possible cause for this tendency towards a small increase of contracted pelvis may be insufficient antirachitic prophylaxis during the childhood of today s pregnant women Another cause may be the increase in the number of immigrants from countries not employing such prophylaxis

Further evaluation of the cause of the small increase in the incidence of contracted pelvis was not possible in the present series The observed incidence of 0 13 per cent is roughly on the same level as the figures given in certain other reports e g 0 2 per cent by HANNAH and 0 09 per cent by MCGRUDER

Contracted pelvic outlet (ΣO<29 5) was found in 0 2 per cent (38 cases) of deliveries from the three periods It should be kept in mind that this is a minimum value as it cannot be excluded that some patients with such measurements but without clinical disproportion were not examined with pelvimetry The maximum incidence of contraction should be twice that for the minimum value or 0 4 per cent since according to the empiric definition of contraction at least 50 per cent of the children will be seriously injured if delivered vaginally in such instances and consequently disclosing the contraction The incidence of contracted outlet is equal to the incidence of disproportion in the distal part of the pelvis as observed by BORELL & FERNSTRÖM HOLMBERG (1968) found a higher incidence of contracted outlet but not differing statistically from the present series

The incidence of borderline measurements which is almost of the same clinical interest as the incidence of contraction is seldom given by other authors Furthermore to calculate accurately the incidence of contracion and borderline cases vertex and breech presentations also have to be separated No such analysis has been found in the literature A narrow pelvis which by definition means a risk for disproportion between the fetus and the pelvis was calculated to occur in not more than close to 10 per cent of all women (Table 5) A narrow outlet was more common than a narrow inlet which is in agreement with the findings of BORELL & FERNSTRÖM

Indications At this hospital pelvimetry has always been used very liberally The frequency has increased steadily to around 19 per cent of all deliveries (Table 2) This frequency is comparable with the highest one found in the cooperative review

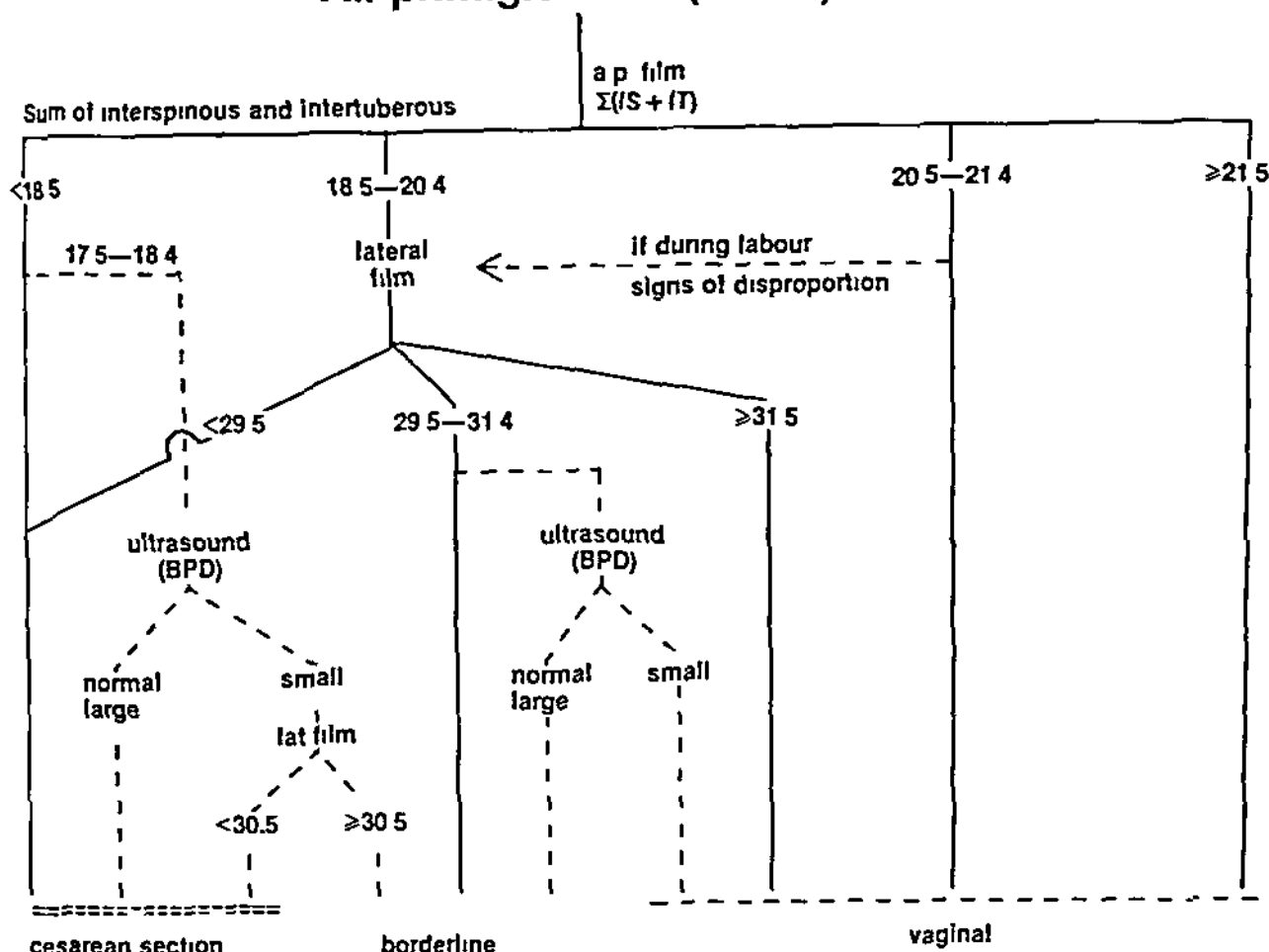
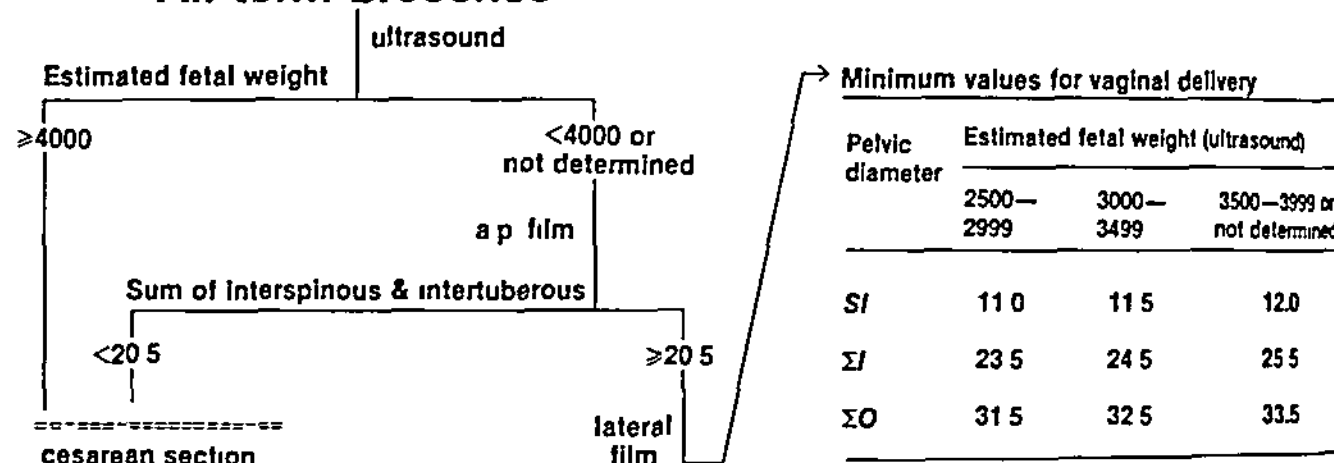


Fig 3 Modified routine low-dose pelvimetry in vertex presentation An orthodiagraphic a p film is exposed in all cases A supplementary lateral film is exposed only in certain cases depending on the sum of interspinous and intertuberous diameter and in some of these cases only during labour when disproportion between fetus and pelvis is indicated Determination of biparietal diameter (BPD) of the fetus by ultrasound can be helpful in selected cases For the pelvic inlet a supplementary lateral film is exposed only in rare cases in which the fetal head does not pass the inlet despite good uterine contractions

based on materials from 16 hospitals by KELLY et coll

With the exception of complicated previous delivery and possible disproportion between the fetus and pelvis during labour all the ordinary indications are more common nowadays Despite the fact that BORELL & FERNSTRÖM pointed out that a mobile fetal head with or without premature rupture of membranes is not an adequate indication for pelvimetry until failure of the head to descend is manifest and coexisting with good uterine contractions a mobile head above the inlet often encountered before onset of labour was one of the most common indications in the present series (Table 7)

Efficacy of palpation in predicting a narrow pelvis Concerning the pelvic inlet HANNAH reported that the indication for pelvimetry was non-engagement of the fetal head in 114 cases (38 per cent) half of which were examined before labour had started as compared with 19 per cent in the present series HANNAH found a total of 17 cases with an SI of less than 10 cm but does not specify the number of these which were referred for pelvimetry because of non engagement of the head If theoretically all 17 cases were referred with this indication the maximum value of PV pos would be 15 per cent compared with 3 per cent in the present series (Table 9) It is not unlikely that the results agree Since in the present series no significant difference in the incidence of narrow inlet existed between patients referred for pelvimetry because of a mobile head above the inlet and those in the control group



Pelvic diameter	Estimated fetal weight (ultrasound)		
	2500—2999	3000—3499	3500—3999 or not determined
SI	11 0	11 5	12.0
ΣI	23 5	24 5	25 5
ΣO	31 5	32 5	33.5

Fig 4 Modified routine low-dose pelvimetry in term breech presentation Cases of footling presentation are excluded as this is considered to be a primary indication for cesarean section obviating pelvimetry Minimum values for vaginal delivery according to OHLSÉN 1974 1975 (SI=sagittal diameter of inlet ΣI=sum of sagittal and transverse diameter of inlet ΣO=sum of outlet=IS+IT+SO)

this clinical finding does not constitute an adequate indication for pelvimetry The only valid indication concerning the inlet is failure of the fetal head to descend despite adequate uterine contractions (BORELL & FERNSTROM)

The detection of contracted outlet before labour is important since it may cause difficulties late in labour often resulting in an emergency intervention HOLMBERG (1966) found contracted outlet at palpation in 24 of 557 primigravidae examined by himself At pelvimetry an ΣO below 31 5 was found in 14 of these 24 cases (PV pos=58%) No cases erroneously considered as normal were encountered in 48 pelvimetries where the palpation had been normal These excellent results were not confirmed in the present series yielding the corresponding figures of PV pos 22 per cent and a possible false negative rate of not less than 50 per cent (Table 9) This high false negative rate may be somewhat less since some of the patients in the control group may not have been examined by palpation However the present figures reflect fairly well the efficacy of this method in routine work The results indicate per se that palpation of the IT in routine work selects patients with a narrow pelvis

Modified radiologic pelvimetry for routine use The question arises whether pelvimetry should be restricted to strictly selected cases be used more liberally or perhaps even routinely in all gravidae In Sweden among the probable 10 per cent of all women with a narrow pelvis in relation to the presentation of the fetus only a minor proportion will exhibit a manifest disproportion between the fetus and the pelvis at vaginal delivery

Before labour the sole practical clinical method for selecting patients with narrow pelvis seems to be palpation of IT However this method possibly does not detect more than about one half of the cases with a narrow outlet in routine work Vaginal ultrasonic evaluation of the IS according to VÁCLAVÍNKOVÁ (1973) appears to be a better method for predicting a small ΣO but has so far not been used in routine work

If theoretically palpation of a small IT together with a history of previous complicated delivery and breech presentation are taken as the only indications for pelvimetry before labour the number of pelvimetries performed during labour for possible disproportion will increase which in turn may lead to an increase in fetal morbidity To some extent this might be compensated for by a smaller number of fetuses irradiated

Employing a liberal use of pelvimetry say about 15 per cent of all deliveries as in the present material after exclusion of a mobile fetal head as one indication the incidence of a narrow pelvis will be about 15 per cent of the pelvimetries compared with the incidence of 10 per cent in all women The advantage of a liberal usage is that cases with an increased labour risk e g elderly primigravidae and patients with toxemia will get a pelvimetry before labour diminishing the incidence of unexpected dispropor

tion in this risk group This advantage should be weighed against the unavoidable increase of irradiation

Routine use of pelvimetry in all gravidae cannot be justified despite the very low absorbed dose when the modern technique is used However as pointed out the detection of a contracted outlet is more important than a contracted inlet before labour Furthermore there is a marked difference almost by a factor of 100 in the absorbed dose to the maternal ovaries between the lateral and the orthodiagraphic a p film (AXELSSON & OHLSEN) As the sum of IS and IT obtained from the a p film is well correlated to ΣO this film can be used as a screening of the outlet measurements (Fig 2) Routine use of the orthodiagrphic a p film supplemented by a lateral film in certain cases can be calculated to give important information with a smaller radiation dose If all primigravidae at this hospital about 50 per cent of all deliveries were routinely examined with an a p film and presuming that a complementary lateral film were taken corresponding to 10 per cent of all primigravidae with vertex presentation and in 85 per cent of patients with breech presentation the mean absorbed dose to the ovaries of all gravidae would be reduced by at least a factor of 2 as compared with the present praxis

The management of such a modified routine low dose pelvimetry in vertex presentation is proposed in Fig 3 ΣO below 31 5 corresponds to Σ(IS+IT) below 21 5 (Fig 2) However (as evident in Fig 3) a supplementary lateral film would be exposed when Σ(IS+IT) is 18 5 to 20 4 or when the sum is 20 5 to 21 4 and disproportion is considered during labour

Further indication for a supplementary lateral film would also be present for instance in cases in which the fetal head does not pass the pelvic inlet despite adequate uterine contractions and in some high risk deliveries Determination of the biparietal diameter by ultrasound gives valuable further information especially in borderline cases which can be useful in the management of labour (Fig 3) The mode of delivery in a borderline case must be individually decided upon

In all term breech presentations irrespective of parity a routine orthodiagraphic a p film is indicated except in those cases in which the estimated fetal weight is with great likelihood over 4 000 g or when footling presentation is at hand indicating cesarean section (Fig 4) When the sum of IS and IT is above 20 5 a supplementary lateral film should be exposed The minimum values of SI ΣI and ΣO for vaginal delivery at different estimated or unknown fetal weights are given in Fig 4 (OHLSÉN 1974 1975)

SUMMARY

In large patient populations from Karolinska Sjukhuset radiologic pelvimetry data including mean values and correlation of the pelvic diameters have been defined Overall incidence of contraction and borderline pelvic measurements and the efficacy of selecting by palpation the patients with a narrow pelvis have been evaluated The indications for pelvimetry were related to an earlier period By re-evaluation of the clinical application of pelvimetry a modified routine low dose pelvimetry is proposed From measurement of the transverse outlet diameters on an orthodiagraphic a p film the sum of the outlet diameters is estimated and a supplementary lateral film is exposed in selected cases Employing pelvimetry in all primigravidae by the orthodiagraphic a p film would still result in a lower total population dose than does the presently used routine of complete pelvimetry consisting of the same a p and lateral films in selected cases

REFERENCES

ALLEN E P Standardised radiological pelvimetry Part IV Interpretation of pelvimetry Brit J Radiol 20 (1947) 205

AXELSSON B and OHLSÉN H Radiation doses in low dose pelvimetry using rare-earth screens Acta radiol Oncology 18 (1979) 470

BORELL U and FERNSTRÖM I Radiologic pelvimetry Acta radiol (1960) Suppl No 191

— — Der Geburtsmechanismus *In* Gynakologie und Geburtshilfe Vol II p 600 Georg Thieme Verlag Stuttgart 1967

— and RÅDBERG C Orthodiagraphic pelvimetry with special reference to capacity of distal part of pelvis and pelvic outlet Acta radiol Diagnosis 2 (1964) 273

CALDWELL W E and MOLOY H C Anatomic variations in the female pelvis—classification and obstetric significance Proc roy Soc Med 32 (1938) 1

COLCHER A E and SUSSMAN W A practical technique for roentgen pelvimetry with a new positioning Amer J Roentgenol 51 (1944) 207

DIEHL J and FERNSTRÖM I Radiologic pelvimetry with special referernce to widest transverse diameter of pelvic inlet Acta radiol Diagnosis 4 (1966) 557

FERNSTRÖM I Backenmatning (In Swedish) Swedish Society of Medical Radiology 1968

GILLANDERS L A Radiological evaluation of the pelvic outlet Brit J Radiol 32 (1959) 371

GREENHILL J P Obstetrics W B Saunders Company Philadelphia 1960

HANNAH W J X ray pelvimetry—a critical appraisal Amer J Obstet Gynec 91 (1965) 333

HOLMBERG N G Clinical evaluation of the pelvic outlet Acta obstet gynec scand 45 (1966) 377
— The assimilation pelvis A radiological and obstetrical study Part II Acta obstet gynec scand (1968) Suppl No 7
KALTREIDER D F The prediction and management of outlet dystocia Amer J Obstet Gynec 67 (1954) 1049
KELLY K M MADDEN D A ARCARESE J S BARNETT M and BROWN R F The utilization and efficacy of pelvimetry Amer J Roentgenol 125 (1975) 66
MCGRUDER C E X ray pelvimetry at a teaching hospital—A ten year evaluation J nat med Ass 60 (1968) 213
MOIR J C Measuring the obstetric value of the pelvis J Obstet Gynaec Brit Emp 56 (1949) 189
MORRIS W J C Outlet contraction of the pelvis Edinb med J 54 (1947) 90 (Cited by Russel)
NICHOLSON C The interpretation of radiological pelvimetry J Obstet Gynaec Brit Emp 45 (1938) 950
OHLSEN H Moulding of the pelvis during labour Acta radiol Diagnosis 14 (1973) 417
— Backenmatning vid 340 satesförlossningar (In Swedish) *In* Satesförlossning p 31 Proceedings of the Swedish Gynecological Society Vaxjo 1974
— Outcome of term breech delivery in primigravidae A feto pelvic breech index Acta obstet gynec scand 54 (1975) 141
ROVINSKY J J MILLER J A and KAPLAN S Management of breech presentation at term Amer J Obstet Gynec 115 (1973) 497
RUSSEL J G B Radiology in obstetrics and antenatal paediatrics Butterworth & Co Ltd London 1973
— and RICHARDS B A review of pelvimetry data Brit J Radiol 44 (1971) 780
SNOW W Basic analysis of obstetric pelvis by roentgen study Amer J Obstet Gynec 58 (1949) 757
STATPAC (Statistical program package) The Computer Department Karolinska Institutet Stockholm 1979
STEEL R G D and TORRIE J H Principles and procedures of statistics McGraw Hill Book Company New York 1960
STEER C M Evaluation of the pelvis in obstetrics Second edition W B Saunders Company Philadelphia 1959
VACLAVINKOVA V A method of measuring the interspinous diameter by an ultrasonic technique Acta obstet gynec scand 52 (1973) 161
VECCHIO T J Predictive value of a single diagnostic test in unselected populations New Engl J Med 274 (1966) 1171

FROM THE DEPARTMENT OF DIAGNOSTIC RADIOLOGY (DIRECTOR PROF H LODIN) AKADEMISKA SJUKHUSET S-750 14 UPPSALA SWEDEN

PERCUTANEOUS NEPHROPYELOSTOMY

A new technique

P G LINDGREN and A HEMMINGSSON

Percutaneous nephropyelostomy had been used only to a minor extent for drainage of the renal pelvis and ureter (GOODWIN et coll 1955 BARTLEY et coll 1965 VELA NAVARRETE 1971 MOLIN & ULMSTEN 1971 SAXTON 1971 JONSSON et coll 1972) before 1974 when ALMGÅRD & FERNSTRÖM introduced a practicable technique A polyethylene catheter on a trocar was introduced into the renal pelvis under fluoroscopy During the next 7 or 8 days in three steps the catheter was replaced by wider catheters and finally a soft balloon catheter was inserted

Ultrasonic guidance at percutaneous nephropyelostomy has previously been accomplished with the aid of a static B scanner (HARRIS et coll 1976 PEDERSEN et coll 1976 HELLSTEN et coll 1977 among others)

This technique has been modified implying that the renal pelvis is punctured under the control of dynamic (real time) ultrasound with a sector scanner This means that the passage of the needle through the tissue can be observed on a monitor display during the puncture procedure and a wide bore catheter can then be inserted primarily

Material and Methods

Percutaneous pyelostomy was performed on 33 patients (ages 26–75 years mean 58) in 6 of them bilaterally A marked hydronephrosis was present in 20 kidneys moderate in 13 and slight in six

The patient was placed in the prone position on a radiographic couch with a fluoroscope A mobile dynamic ultrasonic apparatus (ATL Mark III with a 3 0 MHz transducer) was used The puncture site was chosen on the medio-posterior axillary line as the puncture channel should run horizontally and the catheter not be compressed when the patient is lying on his back The puncture site was located between or below the lower ribs

After the application of local anaesthesia and under sterile conditions the puncture was carried out with the aid of a needle guide unit fitted to the transducer head of the ultrasonic apparatus A sterile rubber glove had been previously drawn over the transducer head (Fig 1) The prolongation of the direction of the groove for the needle in the guide unit was located in the 90° ultrasonic field which was about 3 to 4 mm in thickness This meant that the passage of the puncture needle OD 2 mm) through the tissue could be followed on the monitor display from a point 1 cm under the skin surface and then directed towards the renal pelvis It could also be observed when the tip of the needle penetrated the renal pelvis A groove instead of an enclosed channel as needle guide permitted the transducer and needle guide unit to be easily removed when the needle had been inserted with its tip in the renal pelvis

When the tip of the needle was located in the renal

Submitted for publication 24 March 1980

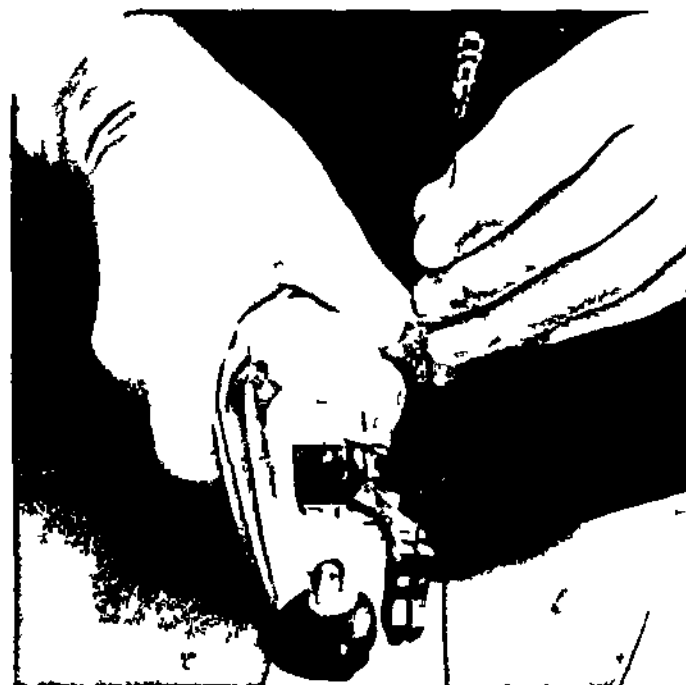


Fig 1



Fig 2a



Fig 2b

Fig 1 The puncture needle in the groove of the needle guide unit This is mounted on the scanner head which is covered with a sterile glove

Fig 2 a) The puncture needle located with its tip in the dilated renal pelvis (photograph of frozen image from a video recording of the puncture procedure) b) Schematic drawing of Fig 2a

pelvis (Fig 2) the mandrin was removed and under fluoroscopy a guide wire (P 205 diameter 1 19 mm) was placed in the upper part of the ureter The needle was then replaced by a catheter (grey Ödman ID 1 8 OD 2 8 mm) and over this was threaded a teflon catheter No 355 (OD 4 5 mm) with 2 or 3 side holes (ALMGÅRD & FERNSTRÖM) The tip of this latter catheter was placed in the ureteropelvic junction or in the upper part of the ureter (Fig 3) The inner narrower catheter and the guide wire were then removed The No 355 catheter was fixed to the skin with a suture and left in situ for 2 days Using a P 205 guide wire it was then replaced by a soft balloon catheter with end holes (Foley catheter No 12) for temporary or permanent drainage

Results

The insertion of the pyelostomy catheter did not lead to any complications In 8 patients two puncture attempts had to be made partly because the renal pelvic dilatation was small or moderate and partly because the patients had difficulty in holding their breath at the puncture attempt In the other patients the first attempt at puncture was successful In all cases the polyethylene catheter with the No 355 catheter could be introduced and placed with their tips in the ureteropelvic junction The change to a balloon catheter two days later was also performed without complications In one patient a ureteral calculus passed spontaneously and a balloon catheter was therefore not necessary

Discussion

The advantage of ultrasonically guided puncture at nephropyelostomy over the use of fluoroscopy is that the risks involved with ionizing radiation are decreased and that the renal pelvis can be localized even if it does not contain contrast medium

Previously ultrasonic guidance has usually been carried out with the aid of a static B scanner The main disadvantage of this technique is that the needle cannot be observed during the puncture proce



Fig 3 Teflon catheter No 355 placed with its tip in the ureteropelvic junction

dure as the image of the renal pelvis is frozen on the monitor display

With the aid of a dynamic ultrasound equipment the tip of the needle and sometimes the whole needle can be observed during its passage through the tissues

Linear array transducers with a special puncture channel are difficult to sterilize and their size sometimes makes it difficult in thin patients to obtain good skin contact at punctures between the ribs

A sector scanner has the advantages that the transducer requires only a small area of skin contact that it is easily manoeuvred and that the problem of sterilization is solved by covering the scanner head with a sterile rubber glove

If more than one attempt at puncture has to be made it is an advantage to use a relatively fine puncture needle (STABLES et coll 1975 PFISTER & NEWHOUSE 1979) as is employed in the technique described Furthermore the use of a metal guide with a polyethylene catheter provides a rigid guiding tool whereby a coarse drainage catheter (PE 355) can be inserted in the same session A balloon catheter for permanent drainage can therefore be introduced after only 2 days which means that the hospital stay can be shortened by 5 or 6 days The relatively atraumatic puncture procedure permitted bilateral pyelostomy to be performed at the same session in 4 patients which previously has been difficult in most cases

Conclusion The described technique implies a reduction of the risks involved in ionizing radiation increased puncture safety less discomfort for the patient a lower demand on personnel and a shortened stay in hospital

SUMMARY

Percutaneous nephropyelostomy was carried out in 33 patients with a modified technique The puncture was performed under control by dynamic ultrasound with a sector scanner using a needle guide unit fitted to the transducer head and primary insertion of a wide bore catheter After 2 days the catheter could be replaced by a balloon catheter for permanent or temporary drainage

REFERENCES

ALMGÅRD L E and FERNSTRÖM I Percutaneous nephropyelostomy Acta radiol Diagnosis 15 (1974) 288

BARTLEY O CHIDEKEL N and RADBERG C Percutaneous drainage of renal pelvis for uraemia due to obstructed urinary flow Acta chir scand 129 (1965) 443

GOODWIN W E CASEY W C and WOOLF W Percutaneous trocar (needle) nephrostomy in hydronephrosis J Amer med Ass 157 (1955) 891

HARRIS R D MCCULLOUGH D L and TALNER L B Percutaneous nephrostomy J Urol 115 (1976) 628

HELLSTEN S HILDELL J LINK D and ULMSTEN U Percutaneous nephrostomy Aspects on applications and technique Europ Urol 4 (1977) 282

JONSSON M LINDBERG B and RISHOLM L Percutaneous nephro-pyelostomy in cases of ureteral obstruction Scand J Urol Nephrol 6 (1972) 51

LINDGREN P G Ultrasonically guided punctures A modified technic Radiology 137 (1980) 235

MOLIN J and ULMSTEN U Percutaneous nephropyelostomy Opusc med 16 (1971) 270

PEDERSEN J F COWAN D F KRISTENSEN J K HOLM H H HANCKE S and JENSEN F Ultrasonically guided percutaneous nephrostomy Report of 24 cases Radiology 119 (1976) 429

PFISTER R C and NEWHOUSE J H Interventional percutaneous *pyeloureteral techniques II Percutaneous* nephrostomy and other procedures Radiol Clin N Amer 17 (1979) 351

SAXTON H M Percutaneous nephrostomy Brit J Radiol 44 (1971) 899

STABLES D P HOLT S A SHERIDAN H M and DONOHUE R E Permanent nephrostomy via percutaneous puncture J Urol 114 (1975) 684

VELA NAVARRETE R Repeat direct pyelography via needle nephrostomy Acta radiol Diagnosis 11 (1971) 33

FROM THE DEPARTMENTS OF DIAGNOSTIC RADIOLOGY UROLOGIC SURGERY AND ONCOLOGY AKADEMISKA SJUKHUSET S 75014 UPPSALA SWEDEN

COMPUTED TOMOGRAPHY IN STAGING OF BLADDER CARCINOMA

L FRODIN A HEMMINGSSON A JOHANSSON and H WICKLUND

Staging of carcinoma of the urinary bladder is important for the choice of therapy (SEIDELMANN et coll 1977) and also has prognostic implications (KENNY et coll 1972 MUIR et coll 1978) A system for staging of bladder carcinoma was introduced by ...METT & STRONG (1946) and later modified by ...ARSHALL (1952) The classification generally ac...pted today is that adopted by the UICC (WAL...CE et coll 1975)

Hitherto the staging has been based upon cysto...py with biopsy transurethral resection and pal...tion under general anaesthesia with complemen...y radiographic examinations such as cystography ...ONNOLLY et coll 1966 KAFKAS 1973) urography ...UIR et coll) lymphography (WAJSMAN et coll ...75 JOHNSON et coll 1976) ultrasound ...CLAUGHLIN et coll 1975) and angiography ...OUSEN & NILSSON 1962 LANG et coll 1966 ...NTERBERGER et coll 1972) However with all ...se methods the staging is still uncertain Thus ...NNY et coll found that erroneous staging had ...en made clinically in 56 per cent of 105 patients ...ETALA & HAZRA (1978) reported that angiography ...ve false negative results in 20 per cent and false ...sitive results in 10 per cent with respect to ...avesical extension of the tumour Computed ...mography (CT) has been claimed to provide a ...tter basis for a correct evaluation of the extension ...the tumour (SEIDELMANN et coll 1977 HODSON ...coll 1979) An investigation of the advantages and ...sadvantages of this method has therefore been ...ade

Material and Methods

In the period December 1977 to March 1979 52 patients (40 men 12 women mean age 67 2 years range 44–81) with carcinoma of the bladder were examined Patients with minor superficial lesions of low grade malignancy were not included

The tumours were staged in accordance with the UICC classification and nomenclature for the primary tumour (Fig 1 WALLACE et coll) with the exception that groups T1 T2 and T3a were combined into one group (≤T3 a)

Clinical staging was based on cystoscopy with biopsy transurethral resection and palpation under general anaesthesia In 6 patients the findings at palpation were considered to be uncertain Urography was performed in all patients influencing the staging in whom impairment of flow was present in the upper urinary tract

For CT an Ohio Nuclear Delta 50 Fast Scanner was used with an exposure time of 18 s and a nominal section thickness of 13 mm The region between the symphysis pubis and the iliac crest was examined with the patient in the supine position before and 10 min after intravenous injection of contrast medium (40 ml of Conray Meglumin 282 mg I/ml)

In all patients the tumour was staged by clinical evaluation and CT and in 12 of them both examinations were repeated before operation was carried out after the preoperative irradiation (40 Gy) In the 12

Submitted for publication 24 March 1980

Table 1

Different staging by CT and clinical evaluation in 12 cases

Clinical staging		CT staging				
		T3 a	T3 b	T4 a	T4 b	T4 a+b
T3 a	8		7	1		
T3 b						
T4 a						
T4 b	2					2
T4 a+b	2			2		

Table 2

CT staging in 6 clinically uncertain cases

Clinical staging		CT staging			
4	T3 a or T3 b	4	T3 a		
2	T3 b or T4	1	T3 a	1	T4 a

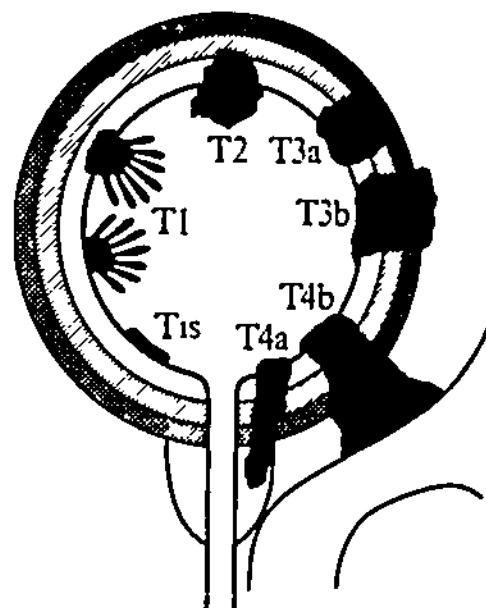


Fig 1 Classification of bladder tumours Tis = flat in situ carcinoma T1 = superfcial tumour not beyond the lamina propria T2 = tumour with invasion of superficial muscle T3a tumour with invasion of deep muscle T3 b = tumour with infiltration of perivesical fat T4 a = tumour with involvement of adjoining organs T4 b = tumour fixed to the pelvic or abdominal walls

patients operated upon and examined preoperatively the findings at CT were compared with those at operation and with the results of microscopic examination of the operative specimens The operation consisted of simple cystectomy and cutaneous entero uretero anastomosis In men the urinary bladder prostate seminal vesicles and urethra were removed in women the bladder and the urethra

Results

Before irradiation the tumour could be staged in 51 patients by CT and in 46 by clinical evaluation Assessment with CT was not possible in one patient because of artifacts produced by a metal prosthesis in one hip and clinical evaluation was not possible in 6 patients because of difficulties in palpation

In 33 of the 45 patients in whom the tumour could be staged with both methods identical staging results were obtained (28 as ≤T3a 2 as T3b 2 as T4a none as T4b 1 as T4a+b) In one of these patients CT revealed not only a very extensive tumour stage T4a+b (Fig 2a) but also bone destruction of part of the ilium on one side (Fig 2b)

In 10 of the 12 patients with discrepant staging from clinical evaluation and CT the former gave a less advanced stage than the latter whereas in the other 2 patients the tumour was staged as T4a+b on the basis of the clinical findings and as only T4a on the basis of CT (Table 1) In 8 of the 10 patients in whom CT resulted in a more advanced stage than clinical evaluation the tumours were clinically assessed as T3a or smaller i e tumours confined to the bladder wall In 7 of these 8 patients CT revealed tumour infiltration of the perivesical fat classified as stage T3b (Fig 3) In one patient CT also disclosed encroachment on the seminal vesicle of one side equivalent to stage T4a (Fig 4)

In 2 patients the tumour was clinically staged as T4b with growth onto the pelvic wall but at CT also encroachment on the prostate (Fig 5) and seminal vesicle was evident i e T4a+b (Fig 6) In the 2 patients whose lesions were referred to a lower stage at CT (T4a) than at clinical evaluation (T4a+b) no tumour growth towards the pelvic wall was observed at CT One of these patients died one month after CT Autopsy revealed continuous tumour involvement of the pelvic wall and also para aortic lymph node metastases

The 6 patients in whom the staging was uncertain on the basis of clinical findings were classified by CT as shown in Table 2

In 10 of the 12 cystectomy patients who were examined preoperatively the findings at CT corresponded with those at operation In one of the other 2 patients a mass was found in the lesser pelvis at CT


Fig 2a


Fig 2b


Fig 3

Fig 2 a) Extensive tumour involving the pelvic wall to the right and posteriorly towards the uterus (T4a+b) b) Destruction of the outer cortex of part of the right ilium (→) and general sclerosis of the skeleton

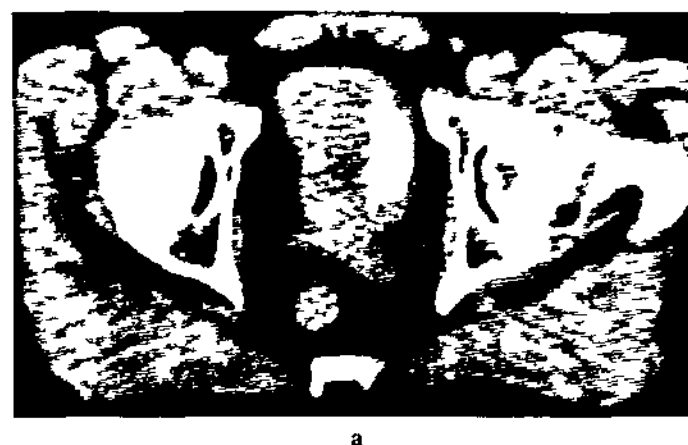
Fig 3 Tumour in the dorsal part of the bladder with infiltration into the perivesical fatty tissue posteriorly to the right (T3 b)

considered to be enlarged lymph nodes but at operation this was found to be due to an aneurysm of the common iliac artery The other patient was classified at CT as T3 b but at microscopy no perivesical tumour growth was found (Fig 7) Adhesions between the intestine and urinary bladder following irradiation probably gave rise to the erroneous evaluation at CT

Regression of the tumour after radiation therapy was noted at CT in 10 patients (Fig 4) In 5 patients residual tumour tissue was found in the operative specimen after the irradiation In a further 5 patients CT revealed thickening of the bladder wall which was confirmed on palpation of the specimen and corresponded to inflammation fibrosis and oedema in the bladder wall at microscopy

Discussion

The potential of CT to give information on the perivesical extension of a bladder tumour is confirmed in the present series and is in accordance with previous reports (PETERSEN 1977 SEIDELMANN et coll 1977 1978 HODSON et coll) The extension of bladder tumours to the perivesical fat tissue and to neighbouring organs is difficult to assess by clinical methods (Table 1) and CT is therefore of value in such cases On the other hand the depth of tumour infiltration into the bladder wall cannot be clearly determined by CT in its present form (SEIDELMANN et coll 1977) Stiffness of a thickened bladder wall has been considered to indicate deep tumour infiltration into the wall i e stage T3 a but this is difficult to distinguish from oedema following biopsy (HODSON et coll) Staging with CT should therefore if possible be performed before endoscopic procedures and irradiation which leads to regressive changes in the bladder wall sometimes combined with adhesions between the bladder wall and the intestine (Fig 7) With the exception of superficial tumours without muscular involvement (T1) the tumours which should be examined with



a



b



c

Fig 4 a) Large right sided bladder tumour with involvement of the right seminal vesicle (T4 a) b) Obstruction of the right ureter with hydronephrosis and no renal excretion of contrast medium Left kidney also hydronephrotic but function maintained c) Regression of tumour after irradiation with 40 Gy General thickening of the bladder wall right seminal vesicle drawn upwards



Fig 5



Fig 6



Fig 7

Fig 5 Tumour in the dorsal region of the bladder base encroaching upon the prostate (T4 a →)

Fig 6 Tumour in the dorsal region of the bladder with involvement of the left seminal vesicle (T4 a) Artifacts from prosthetic material in the right hip

Fig 7 Tumour in the right dorsal region of the bladder with thickening of the bladder wall The poorly defined border against the surrounding structures was initially considered as tumour infiltration (T3 b) but this was not confirmed at microscopy The appearance probably being due to adhesions

CT for staging are all those which have been classified on a clinical basis as T3a or smaller which will include several types of tumour with perivesical extension (Table 1) In addition CT should be used in cases of more extensive tumours (T3b T4a+b) for the main purpose of improving the dose planning for irradiation

In the present series of patients CT in 2 cases led to an erroneous diagnosis of lymph node metastases Enlarged lymph nodes are difficult to assess correctly especially in the lesser pelvis due to the varying widths of the iliac blood vessels and fluid filled intestines in the vicinity of the vessels (HODSON et coll) This latter difficulty can be reduced by the administration of contrast medium to the small and large intestines

The bladder was evaluated clinically by cystoscopy combined with biopsy from the findings at transurethral resection and by palpation under general anaesthesia However in many cases palpation was not performed both before and after resection and furthermore the resections were often not carried out to a sufficient depth to permit a complete clinical evaluation CT was carried out with urine in the bladder and after intravenous injection of contrast medium The width of the ureters could thereby be assessed as well as the presence of impairment of urinary flow A more reliable evaluation of the thickness of the bladder wall might be possible after administration of carbon dioxide (SEIDELMANN et coll 1978) or fatty liquid such as the infusion emulsion Intralipid into the bladder (CALISSENDORFF et coll 1979) The value of these methods is being investigated at present

Conclusion

Computed tomography permits a more reliable evaluation of the perivesical extension of a bladder tumour to fat tissue and neighbouring organs than clinical evaluation However difficulties are encountered at CT in assessing the presence of metastases in the lesser pelvis

SUMMARY

A comparison was made between the use of clinical methods and computed tomography for staging of carcinoma of the urinary bladder in 52 patients CT was found to be the most reliable method for determining the perivesical extension of the tumour It is of value for determining the extent of the tumour before irradiation and for establishing the tumour response It was less reliable for diagnosing metastases in the lesser pelvis

REFERENCES

BOUSEN E and NILSSON J Angiography in the diagnosis of tumors of the urinary bladder Acta radiol 57 (1962) 241

CALISSENDORFF B AHLBERG N E BERLIN T and COLLSTEN L Personal communication 1979

CONNOLLY J G CHALLIS T W WALLACE D M and BRUCE A W Use of the fractionated cystogram in the staging of bladder tumors Canad J Surg 9 (1966) 39

HIETALA S O and HAZRA T Angiography in vesical and perivesical neoplastic and non neoplastic lesions Acta radiol Diagnosis 19 (1978) 447

HODSON N J HUSBAND J E and MACDONALD J S The role of computed tomography in the staging of bladder cancer Clin Radiol 30 (1979) 389

JEWETT J H and STRONG G H Infiltrating carcinoma of the bladder Relation of depth of penetration of the bladder wall to incidence of local extension and metastases J Urol 55 (1946) 366

JOHNSON D E KAESLER K E KAMINSKY S JING B S and WALLACE S Lymphangiography as an aid in staging bladder carcinoma Sth med J 69 (1976) 28

KAFKAS M Study and diagnosis of bladder tumors by triple contrast cystography J Urol 109 (1973) 832

KENNY G M HAZDUER G J MOORE R M and MURPHY G P Current results from treatment of stages C and D bladder tumors at Roswell Park Memorial Institute J Urol 197 (1972) 56

LANG E K NOURSE M H WISHARD JR W M and MERTZ J H O The accuracy of preoperative staging of bladder tumors by arteriography A 5 year study J Urol 95 (1966) 363

MARSHALL V F The relationship of the preoperative estimate to the pathologic demonstration of the extent of vesical neoplasm J Urol 68 (1952) 714

MCLAUGHLIN I S MORLEY P DEANE R F BARNETT E GRAHAM A G and KYLE K F Ultrasound in the staging of bladder tumours Brit J Urol 47 (1975) 51

MUIR B B SINCLAIR D J and DUNCAN W The role of radiology in the assessment of bladder cancer Clin Radiol 29 (1978) 479

PETERSEN R W A computerized tomographic evaluation of malignancies of the bladder and prostate Computerized Tomogr 1 (1977) 283

SEIDELMANN F E COHEN W N and BRYAN P J Computed tomographic staging of bladder neoplasms Radiol Clin N Amer 15 (1977) 3

— — — TEMPES S P KRAUS D and SCHOENROCK G Accuracy of CT staging of bladder neoplasms using the gas filled method Report of 21 patients Amer J Roentgenol 130 (1978) 735

WAJSMAN S BAUMGARTNER S MURPHY G and MERRIN C Evaluation of lymphangiography for clinical staging of bladder tumors J Urol 114 (1975) 712

WALLACE D M CHISHOLM G D and HENDRY W F T N M classification for urological tumours Brit J Urol 47 (1975) 1

WINTERBERGER A R KENNY G M CHOI S H and MURPHY G P Correlation of selective arteriography in the staging of bladder tumors Cancer 29 (1972) 332

Acta Radiologica Diagnosis 21 (1980) Fasc. 6

FROM THE DEPARTMENTS OF DIAGNOSTIC RADIOLOGY, SURGERY AND UROLOGY, UNIVERSITY HOSPITAL, S-221 85 LUND, SWEDEN

QUANTITATIVE DOPPLER AND ULTRASOUND MEASUREMENTS IN SURGICALLY PERFORMED ARTERIOVENOUS FISTULAS OF THE ARM

L. FORSBERG, T. HOLMIN and E. LINDSTEDT

Arteriovenous fistulas, performed according to the method described by BRESCIA et coll. (1966) have been widely used at this hospital during the last decade (LINDSTEDT 1972, LINDSTEDT & LINDHOLM 1979). They are used mainly for dialysis and to facilitate administration of cytostatics or parenteral nutrition. STEPHENSON & LICHTI (1971) introduced Doppler examination for patency controls and KEITZER & LICHTI (1975) for semiquantitative estimation of flow velocity in such fistulas. Examination in order to prove patency or not does not necessitate any quantification, since the flow velocity curves of a brachial artery supplying an open shunt are characteristically different from those of a normal brachial artery (FORSBERG et coll. 1980). A Doppler apparatus equipped with a calibrator makes possible a quantification of the velocity of flow in an vessel, and is particularly appropriate for vessels leading to a fistula, where reversed flow is not affecting the measurements.

Material and Methods

The material consisted of 87 patients, 32 men and [illegible] women, 11 to 70 years old (mean 46 years) with open fistulas. They were examined one day to 10 years after the fistula was established. Twenty-nine of the fistulas were used for dialysis in uraemic patients from 2 months to 10 years (mean 2[illegible] years) and the remainder mainly for cytostatic infusion.

The fistulas were made 5 to 7 mm in length and secured with continuous Prolene sutures. All were performed between the radial artery and the cephalic vein in the distal forearm with anastomosis side to-side in most cases, side to-end in a few.

The Doppler examinations were performed with a 10 MHz directional Doppler (Parks 806). Calibration of the equipment was performed before every examination with an oscillator giving a signal of 1000 Hz. The Doppler probe was placed in a plastic holder giving a constant angle of 45° between the probe and the underlying structures. Maximum flow velocity is recorded when the probe is pointing in the direction of the vessel. Registrations were obtained over the brachial artery just above the elbow where the artery runs parallel to the skin. Recordings were made on a Siemens polygraph.

The diameter of the brachial artery was also measured in 63 patients with 3.5 and 5.0 MHz B-scan ultrasound. The artery was palpated before examinations with Doppler in order to mark out the direction and exact position of the vessel in question. Examinations were made both longitudinal and transverse over the artery. The longitudinal procedure turned out to be giving better and more reproducible information than did the transverse one.

In the patients in whom both flow velocity and diameter measurements were performed the volume

---

Submitted for publication 8 February 1980.

flow was calculated by multiplying the cross section area of the artery with the obtained flow velocity

Results

Doppler examination of the flow velocity of well functioning fistulas of the arm gave a mean value of 45 cm/s (Fig 1 SD 12 cm/s) in 83 patients The diameter of the brachial artery as measured with ultrasound in the 63 patients varied from 3 to 9 mm (mean 5 1 mm SD 1 3 mm) In this group no correlation was found between the flow velocity and the diameter of the brachial artery (Table) Neither was any correlation found in a series of 72 patients in whom flow velocity was related to the age of the fistula (Fig 2) The diameter was also related to the age of the fistula (Fig 3) in 55 patients but no correlation was at hand In some patients it was difficult to assess the proper duration of the fistula These cases were excluded from the time related evaluations No extreme values of flow velocity or arterial diameter were found in this group Calculations of volume flow in 63 patients gave a mean flow of 634 ml/min (SD 370 ml/min) No certain correlation could be found when in 55 patients relating volume flow to the age of the fistula (Fig 4)

In 12 patients in dialysis the diameter of the brachial artery was measured giving a mean of 5 5 mm±1 7

Flow velocity calculations were made in all 29 patients with fistulas used for dialysis No correlation could be found between duration of dialysis and flow velocity in the feeding artery (Fig 5)

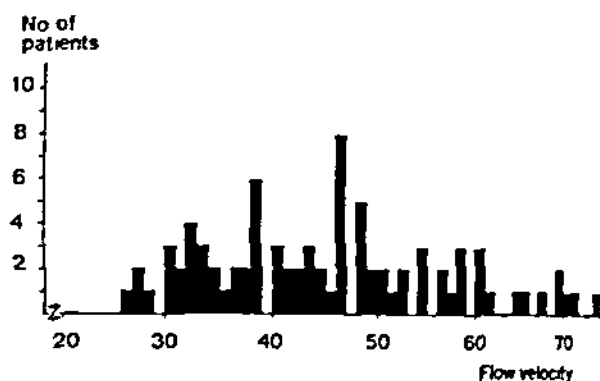


Fig 1 Flow velocity measurements (cm/s) with 10 MHz Doppler in 83 patients with well functioning arteriovenous fistula Mean 45 cm/s SD 12 cm/s

Table

Flow velocity in the feeding (brachial) artery of the fistula in 63 patients The diameter of the artery is not affecting the velocity of flow

Diameter (mm)	Flow velocity (cm/s)
3	71 38 67 31 46
3 5	50 37
4	43 41 49 70 47 37 38 38
	58 48 58 56 34
4 5	38 48
5	46 43 40 60 37 40 46 46
	46 40 33 45 57 61 49
5 5	46 30 64 60 51 57 38
6	28 34 69 48 74
6 5	56 32 41 65 46 48 54 30
7	60 69 3
7 5	36
8	46
9	57

Discussion

At this institution arteriovenous fistulas between the radial artery and the cephalic vein (BRESCIA et coll) has been the standard procedure since 1967 (LINDSTEDT) making arterialized veins for dialysis and other purposes

The flow in arteriovenous fistulas of this kind has been examined with many different techniques giving somewhat different numeric values of the flow

HURWICH (1969) used plethysmographic methods to measure flow in fistulas of the forearm in 12 patients getting a mean flow of 220 ml/min LINDSTEDT & NORDENFELT (1972) estimated fistula flow using cardiac output measurements with dye dilution before and after compressing the fistula in 10 patients and found a mean flow of 600 ml/min KLUTSCH et coll (1972) used the same principle in 23 patients and obtained a mean shunt flow of 535 ml/min (198–812 ml/min) and KULT et coll (1973) with a dye-dilution method obtained flows from 471 to 1013 ml/min Dye-dilution was also used by GÖTHLIN et coll (1977) in 15 patients resulting in a mean flow of 1590 ml/min (range 790–2750 ml/min) ANDERSON et coll (1977) measured flow in fistulas (end to-side cephalic vein to radial artery) of 38 patients with an electromagnetic flow meter and found a mean flow of 242±89 ml/min

The volume flow was calculated in 63 of the pres

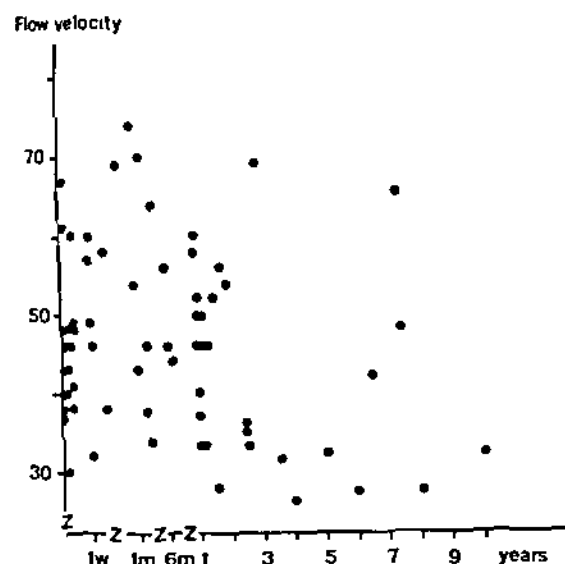


Fig 2 Flow velocity (cm/s) in 7? patients compared with the age of the fistula no correlation

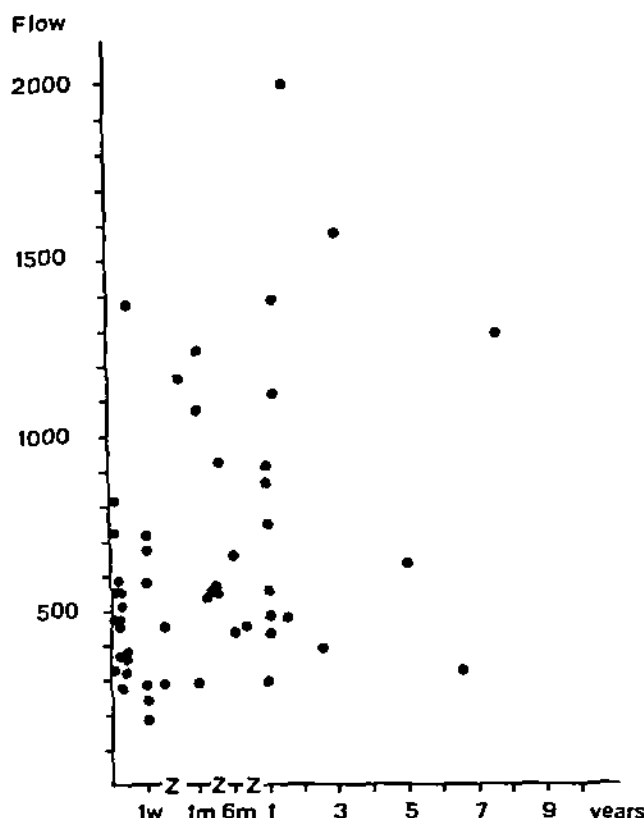


Fig 4 Volume flow (ml/min) in 55 patients compared with the age of the fistula no correlation

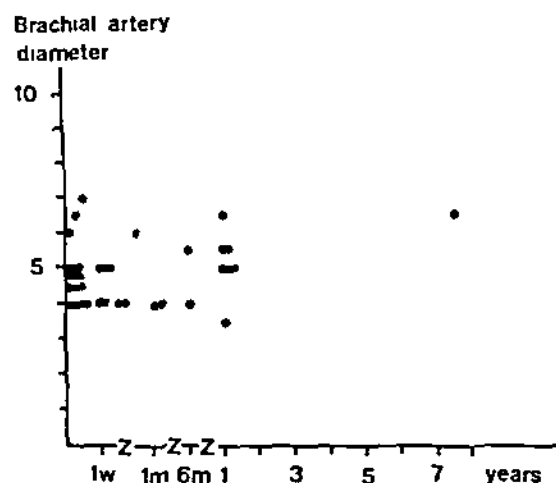


Fig 3 Diameter (mm) of the brachial artery in 55 patients compared with the age of the fistula no correlation

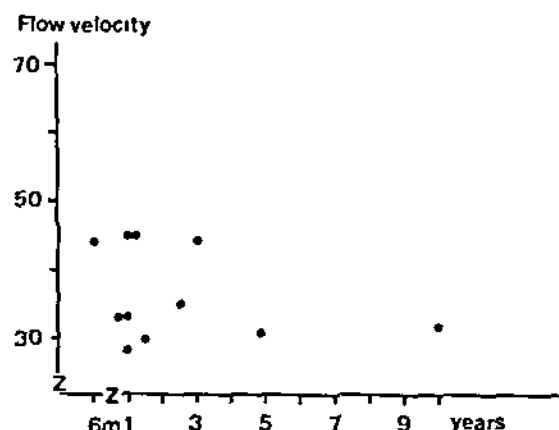


Fig 5 Flow velocity (cm/s) in the feeding (brachial) artery of 9 patients fistula used for dialysis No correlation between flow velocity and length of dialysis period

ent patients in whom both Doppler measurements of the flow velocity and ultrasound measurements of the diameter of the brachial artery were performed giving a mean flow of 634±370 ml/min The dye dilution measurements of the same type of fistulas gave higher flow values than did electromagnetic and plethysmographic methods In a previous series of 14 patients at this hospital (FORSBERG et coll) a good correlation (r=0 91) was found between dye dilution measurements and measurements performed with Doppler technique However the dye dilution method gave higher values 1940+

ml/min and 1230±570 ml/min respectively The values of flow in this group of patients are somewhat higher than in the present group of patients with well functioning fistulas The Doppler dye measurements were performed in a selected group of patients examined with angiography before closing the fistula or reducing the flow due to various symptoms none of the patients having cardiac insufficiency

The Doppler method has been used by KEITZER & LICHTI for a crude estimation of flow comparing flow velocity in the normal brachial artery with the velocity of flow in the brachial artery feeding the fistula A 3 to 4 times increase in flow velocity was considered adequate However mean flow velocity is sometimes very difficult to estimate in a normal artery with pulsatile flow with a component of reversed flow The calculation of flow is easier in an artery feeding a fistula as a continuous forward flow exists The mean flow velocity in the present 83 patients was 45 cm/s No correlation was found between the age of the fistula and the three variables flow velocity volume flow and arterial diameter (Figs 2 3 4) The length of the dialysis period did not affect the flow velocity (29 patients Fig 5) HOLMAN (1937) postulated that arteriovenous fistulas at least central ones increase their flow as time passes This was not found in the present series but repeat examination must be performed to elucidate the dynamics of an arteriovenous fistula of the arm

For determination of the flow velocity a calibration of the Doppler equipment is essential The Parks 806 apparatus is equipped with an oscillator giving a fixed frequency of 1000 Hz Other types of calibrators could be used as described by FORSBERG & OLIN (1980)

The possibility of performing non invasive quantitative measurements of flow and flow velocity makes possible analysis of normal flow velocity in fistulas as well as recognizing changes when the capacity of the fistula is diminishing It should also be possible to assess small changes of an individual fistula Further analyses concerning the haemodynamics of fistulas are thus warrented and might add some new information in this field

SUMMARY

Quantitative Doppler flow and flow velocity determinations were made combined with ultrasound estimation of the arterial diameter of the feeding vessel in arteriovenous fistulas of the arm used both for dialysis administration of cytostatics and parenteral nutrition In 83 patients flow velocity alone was determined while the volume flow was calculated in 63 The effect of the length of the dialysis period and age of the fistula on the different parameters is discussed

REFERENCES

ANDERSON C B ETHEREDGE E E HARTER H R GRAFF R J CODD J E and NEWTON W T Local blood flow characteristics of arteriovenous fistulas in the forearm for dialysis Surg Gynec Obstet 144 (1977) 531

BRESCIA M J CIMINO J E APPEL K and HURWICH B J Chronic haemodialysis using venipuncture and a surgically created arteriovenous fistula New Engl J Med 275 (1966) 1089

FORSBERG L and OLIN T Effect of interposed skin at Doppler flow estimation at 5 and 10 MHz With description of a calibration device Acta radiol Diagnosis 21 (1980) 203

— TYLÉN U OLIN T and LINDSTEDT E Quantitative flow estimations of arteriovenous fistulas with Doppler and dye-dilution techniques Acta radiol Diagnosis 21 (1980) 465

GOTHLIN J LINDSTEDT E and OLIN T A dye-dilution method for the determination of blood flow in Cimino Brescia fistulae Invest Urol 15 (1977) 167

HOLMAN E Arteriovenous aneurysm Abnormal communications between the arterial and venous circulation Macmillan New York 1937

HURWICH B J Plethysmographic forearm blood flow studies in maintenance thermodialysis patients with radial arteriovenous fistulae Nephron 6 (1969) 673

KEITZER W F and LICHTI E L Applications of the Doppler Common and unusual situations Angiology 26 (1975) 172

KLUTSCH K ROSS W CHRIST V und SCHEITZA E Die hamodynamischen Auswirkungen der subkutanen arteriovenosen Fistel bei chronischer Uramie Z Kreisl Forsch 61 (1972) 497

KULT J SCHEITZA E GROSSWENDT J und KLUTSCH K Das reale Shuntvolumen subcutaner arteriovenoser Fisteln bei chronisch hamodialysierten Patienten Z Kardiol 62 (1973) 158

LINDSTEDT E Studies in therapeutic arteriovenous fistulae Scand J Urol Nephrol (1972) Suppl No 14

— und LINDHOLM T Die Gefassanschlusse bei Dialysepatienten Zbl Chir 104 (1979) 477

— and NORDENFELT J Haemodynamic studies in patients with Cimino-Brescia arteriovenous fistulae Scand J Urol Nephrol (1972) Suppl No 14 p 33

STEPHENSON H E JR and LICHTI E L The Doppler ultasonic flowmeter in the management of the dialysis arteriovenous fistula Arch Surg 103 (1971) 744

Acta Radiologica Diagnosis 1 (1980) Fasc 6

FROM THE DEPARTMENTS OF DIAGNOSTIC RADIOLOGY I AND ORTHOPAEDIC SURGERY SAHLGRENSKA SJUKHUSET UNIVERSITY OF GOTHENBURG S-41685 GOTHENBURG SWEDEN

PHLEBOGRAPHY IN CRURAL HEMATOMA

Differential diagnosis from recent deep vein thrombosis

B E ZACHRISSON P LUKES and B ROMANUS

A differentiation between recent deep vein thrombosis of the lower leg and traumatic hematoma is sometimes difficult Increasing pain in the calf edema and an increasing volume of the leg usually occur in both conditions

The crural hematoma that can be mistaken for deep vein thrombosis is usually caused by partial or total muscular rupture with injury of muscle vessels A thorough questioning on the onset of symptoms and clinical examination of the calf can in most cases lead to the diagnosis of muscle rupture (STENER & WICKBOM 1966 PETERSON & STENER 1976) However difficulties may arise in cases with a previous history of deep vein thrombosis permanent anticoagulative treatment or when the trauma consists only of slightly increased activity In these cases phlebography may be indicated for obtaining a differential diagnosis thus enabling adequate therapy

The phlebographic criteria for deep vein thrombosis of the leg have been divided into two groups direct and indirect (DE WEESE & ROGOFF 1963 BORGSTRÖM et coll 1965 NYLANDER 1968 BECKER et coll 1970 BERGVALL 1971 ZACHRISSON & JANSEN 1973) The presence of constant filling defects is considered to be a reliable direct indication of thrombosis (BORGSTRÖM et coll) HAEGER NYLANDER (1967) and NYLANDER have pointed out that non filling of the deep veins of the lower leg combined with increased velocity of flow is a main finding in acute thrombosis of the lower leg An increase of the subfascial pressure because of edema is assumed to be the cause of non filling of deep veins of the lower leg in the acute stage of venous thrombosis (MAY & NISSL 1967 NYLANDER) A similar mechanism has been discussed in the compartmental syndrome (RENEMAN 1975) another cause may be a hematoma located in the deep fascial spaces However non filling of the veins may also be caused by contraction of the muscles of the calf (ALMÉN & NYLANDER 1962 1964) Experience from patients with primary incorrect phlebographic diagnosis of deep vein thrombosis based on indirect signs only and with the conclusive diagnosis of crural hematoma has prompted us to the present report describing the phlebographic findings in hematoma of the calf and considering the differentiation from recent venous thrombosis

Material and Methods

A 5 year period of medical records at this hospital with a final diagnosis of crural hematoma were reviewed Fifteen patients (11 men and 4 women) with an average age of 52 years (range 18–69) had been examined by ascending phlebography (GREITZ 1954) in one a descending phlebography (BERGVALL) was also performed The indication for the phlebography was suggested thrombosis in 10 cases thrombosis or hematoma in 5 cases In 3 patients a

Submitted for publication 6 September 1979



Fig 1a



Fig 1b



Fig 2

Fig 1 49 year-old man Phlebography of the right lower leg 4 days after sudden onset of pain in the calf and swelling a) Rapid superficial flow and non filling of deep veins b) Cone shaped compression and occlusion of the popliteal vein indicating expanding lesion Rupture and major hematoma of the medial gastrocnemius muscle found at operation

Fig 2 57 year-old woman Phlebography of the right lower leg after 5 days of swelling and pain in the calf Thrombosis suggested Non filling of the veins of the medial head of the gastrocnemius The patient developed subcutaneous descending hematoma A local swelling later palpable in the medial gastrocnemius muscle and distal to it a defect in the muscle contour

second phlebography was performed 1 12 or 18 days respectively after the first one the indication was in one case suggested thrombosis and in 2 cases thrombosis or hematoma The preliminary diagnosis at the first examination was thrombosis (based on indirect signs) in 5 cases no thrombosis in 9 and probably hematoma in one Seven patients received anticoagulation treatment until later the conclusive diagnosis of hematoma was made Thus the material consists of 18 phlebographies All the films were re-examined by two of the authors and the following abnormalities were considered Constant filling defect total occlusion partial compression or displacement of veins total or local non filling of the deep veins Phlebographies in the present series registered as non pathologic included post thrombotic lesions and varicose veins

The medical records were evaluated by one of the authors (B R) Special attention was paid to notes on sudden onset of pain at exercises such as running climbing stairs or similar physical activities Localized tenderness or swelling over the muscles of the calf and their localization near the achilles tendon indicated muscle rupture (O DONOGHUE 1970) Descending hematoma appearing later behind the malleoli also indicated major hematoma or muscle rupture (HAEGER et coll 1967 TIBBUTT & GUNNING 1974) According to these criteria 11 patients had muscle rupture and at least in 7 of these cases the rupture was located in the



g 3 49 year-old man Phlebography of the left lower leg after :k on the calf a) Ascending phlebography days after ıuma Compression of the popliteal vein Non filling of the :dial gastrocnemius veins Compression of the posterior tibial d fibular veins (→) b) Descending phlebography at the same casion Slow emptying of the posterior tibial fibular and mus lar veins (→) The findings indicate an expanding lesion in the ep flexor compartment One week later subcutaneous hema ma of the whole calf

ıedial head of the gastrocnemius muscle The ther 4 cases had hematoma of other origins

Results

In 7 of the patients some abnormalities were found it phlebography cone formed occlusion of popliteal veins in 2 cases (Fig 1) compression of deep veins in 3 displacement of deep veins in 3 non filling of deep veins of the lower leg in 5 and local non filling of deep veins in 3 cases (4 examinations) Isolated non filling of the veins in the medial head of the gastrocnemius was observed in 2 cases (Fig 2) Constant filling defects indicating recent thrombosis were not observed In one of the cases the deep veins of the lower leg were not filled at the first phlebography A second examination one day later revealed compression and displacement of deep veins A descending hematoma appeared later (Fig 3) In the total material phlebographies with out evident abnormality occurred in 10 cases at the first examination In 3 of these cases a second phlebography was abnormal In one case no filling of the deep veins of the calf occurred and at puncture of the calf old blood was aspirated In one case the veins of the medial head of the gastrocnemius did not fill this case was found to have muscular necro sis and hematoma as a result of pressure during prolonged unconsciousness caused by drug intoxica tion (one similar case was reported by GRONNER in 1972)

Discussion and Conclusion

The clinical diagnosis in recent deep vein throm bosis is uncertain (COON & COLLER 1959 MAY & NISSL NEGUS et coll 1968 FLANC et coll 1969 BECKER et coll) In the acute stage it can be diffi cult or impossible to differentiate deep vein throm bosis from hematoma The presence of even minor trauma or medical treatment that can increase bleeding tendencies (anticoagulative acetylsali cylate) or decrease muscular tendinous strength (cortisone) should be asked for Special diagnostic difficulties exist in cases with a previous history of thrombosis or permanent anticoagulative treatment and if information on any trauma is lacking In such cases phlebography is indicated

The phlebographic examinations were often con sidered normal in the present cases with crural hematoma as also was found by HAEGER et coll This may be due to the phlebography being per formed in an early stage of the hematoma before the veins have been affected Thus a normal phlebography does not exclude hematoma but with great certainty thrombosis In cases in which the clinical diagnosis is still unclear after some days the phlebography should be repeated Non filling of the deep veins is often found in patients with major hematomas thus simulating thrombosis This may lead to a wrong therapy with anticoagulative drugs resulting in increasing bleeding and symptoms This fact further emphasizes that the phlebographic diagnosis of recent deep vein thrombosis should only be based on constant filling defects (BORG STRÖM et coll)

The veins of the medial gastrocnemius head are anatomically constant and are well filled in most

normal cases (GREITZ 1955) Non filling of these veins should be considered pathologic if the phlebo graphic technique is adequate this finding may indicate muscular rupture and hematoma Compres sion displacement and occlusion of the deep venous system in combination with superficial collateral flow indicate major hematoma in the calf as well as cone shaped narrowing of the popliteal vein in the distal direction However in the popliteal region other expanding lesions may be considered e g Baker cysts (GOOD 1964 HENCH et coll 1966 PERRI et coll 1968 SWETT et coll 1975)

SUMMARY

Fifteen cases of crural hematoma in which phlebo graphy had been performed were revised A phlebo graphy was often normal in an early stage of hematoma In major crural hematoma compression displacement and occlusion of the deep venous system occurred Non filling of deep veins occurred in 6 cases and venous thrombosis should therefore only be diagnosed on the basis of constant filling defects

REFERENCES

ALMÉN T and NYLANDER G Serial phlebography of the normal lower leg during muscular contraction and relaxation Acta radiol 57 (1962) 264

— — False signs of thrombosis in lower leg phlebo graphy Acta radiol Diagnosis 2 (1964) 345

BECKER J BORGSTRÖM S and SALTZMAN G F Oc currence and course of thrombosis following prostatec tomy A phlebographic investigation Acta radiol Diagnosis 10 (1970) 513

BERGVALL U Phlebography in acute deep venous thrombosis of the lower extremity Acta radiol Diagnosis 11 (1971) 148

BORGSTRÖM S GREITZ T VAN DER LINDEN W MOLIN J and RUDICS I Ascending phlebography in fresh thrombosis of the lower limb Amer J Roentgenol 94 (1965) 207

COON W W and COLLER F A Clinicopathologic cor relation in thromboembolism Surg Gynec Obstet 109 (1959) 259

FLANC C KAKKAR V V and CLARKE M B Post operative deep-vein thrombosis Effect of intensive prophylaxis *Lancet I (1969)* 477

GOOD E A Rheumatoid arthritis Baker s cyst and thrombophlebitis Arthr and Rheum 7 (1964) 56

GREITZ T The technique of ascending phlebography of the lower extremity Acta radiol 42 (1954) 421

— Phlebography of the normal leg Acta radiol 44 (1955) 1

GRONNER A T Muscle *necrosis simulating a malignant* tumor angiographically Radiology 103 (1972) 309

HAEGER K and NYLANDER G Acute phlebography Triangle 8 (1967) 18

— NILSSON I M and ROBERTSSON B Tromboembo lirisken vid oral antikonception (In Swedish) Lakar tidningen 64 (1967) 3498

HENCH P K REID R T and REAMES P M Dissecting popliteal cyst simulating thrombophlebitis Ann intern Med 64 (1966) 1259

MAY R *und* NISSL R *Zur Symptomatik* der frischen Thrombose der tiefen Beinvenen Fortschr Rönt genstr 107 (1967) 262

NEGUS D PINTO D J LE QUESNE L P BROWN N and CHAPMAN M ^{125}I labelled fibrinogen in the diagnosis of deep vein thrombosis and its correlation with phlebography Brit J Surg 55 (1968) 835

NYLANDER G Phlebographic diagnosis of acute deep leg thrombosis Acta chir scand (1968) Suppl No 387 p 30

O DONOGHUE D H Treatment of injuries to athletes *Second* edition W B *Saunders Company Phila delphia London Toronto 1970*

PERRI J A RODNAN G P and MANKIN H J Giant synovial cyst of the calf J Bone Jt Surg 50 (1968) 714

PETERSON L and STENER B Old total rupture of the adductor longus muscle A report of seven cases Acta orthop scand 47 (1976) 653

RENEMAN R S The anterior and the lateral compart mental syndrome of the leg due to intensive use of muscles Clin Orthop 113 (1975) 69

STENER B and WICKBOM I Angiography in three cases of muscle rupture with organizing haematoma Acta radiol *Diagnosis 4 (1966) 169*

SWETT H A JAFFE R B and MCIFF E B Popliteal cysts Presentation as thrombophlebitis Radiology 115 (1975) 613

TIBBUTT D A and GUNNING A J Calf haematoma A new sign in differential diagnosis from deep vein thrombosis Brit med J 4 (1974) 204

DE WEESE J A and ROGOFF S M *Phlebographic* patterns of acute deep venous *thrombosis* of the leg Surgery 53 (1963) 99

ZACHRISSON B E and JANSEN HJ Phlebographic signs in fresh postoperative venous thrombosis of the lower *extremity Acta radiol Diagnosis* 14 (1973) 87

Acta Radiologica Diagnosis 21 (1980) Fasc 6

FROM THE DEPARTMENT OF ORAL RADIOLOGY UNIVERSITY OF LUND SCHOOL OF DENTISTRY S-21421 MALMÖ SWEDEN

DOUBLE CONTRAST TOMOGRAPHY OF THE TEMPOROMANDIBULAR JOINT

A new technique based on autopsy specimen examinations

P L WESTESSON K Å OMNELL and M ROHLIN

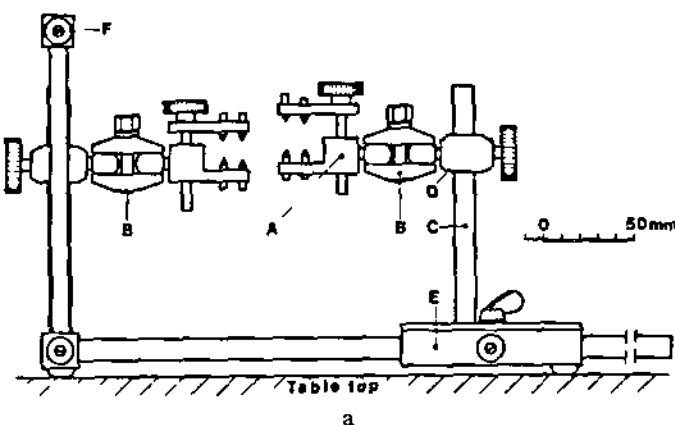
Muscular and articular disorders of the stomatognatic system are prevalent (HANSSON & NILNER 1975 HELKIMO 1979 SOLBERG et coll 1979) and often exhibit symptoms related to the temporomandibular joint For this reason radiographic examination of this joint is a common diagnostic procedure Conventional radiography tomography included may reveal changes in shape structure and function of the skeletal parts of the joint However abnormalities are often located in the soft tissues of the joint (STEINHARDT & LANGEN 1933 BLACKWOOD 1963 MOFFETT et coll 1964 CARLSSON et coll 1968 OBERG et coll 1971 LINDVALL et coll 1976 BEAN et coll 1977 HANSSON & ÖBERG 1977) and these abnormalities are not readily demonstrated with conventional radiographic techniques Perforation and displacement of the disc are usually not demonstrated

In order to gain information of the soft tissue components NØRGAARD (1947) used temporomandibular arthrography with an iodine contrast medium However this method has found a limited application only probably due to the difficult injection technique During the last decade however renewed interest for the method has appeared (AGERBERG & LUNDBERG 1971 CHAO-CHU et coll 1973 TOLLER 1974 LYNCH & CHASE 1978 WILKES 1978a b KATZBERG et coll 1979 FARRAR & MCCARTY 1979) Double contrast examination has been widely applied to other joints such as the knee (ANDERSON & MASLIN 1974 THIJN 1976 FIROOZNIA et coll 1976 DALINKA et coll 1977 HORN 1977 ROEBUCH 1977) the shoulder joint (GOLDMAN & GHELMAN 1978) and the elbow (ETO et coll 1975) The information yielded by the application of this technique was by ETO et coll HORN and GOLDMAN & GHELMAN considered to be superior to that resulting from the use of single contrast arthrography

A technique for double contrast examination of the temporomandibular joint was described by ARNAUDOW et coll (1968) and ARNAUDOW & PFLAUM (1974) A small amount of iodine contrast medium followed by a larger amount of air was injected into the joint compartments The authors indicated the diagnostic value of early recognition of cartilage abnormalities in the joint demonstrated with this technique

Various procedures for double contrast examination of the temporomandibular joint have been tested in anatomic specimens which led to a modification of the technique described by ARNAUDOW et coll and ARNAUDOW & PFLAUM The modified technique is now described

Submitted for publication 4 October 1979



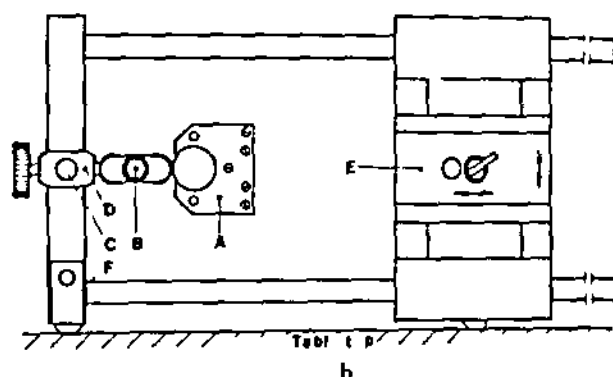


Fig 1 Positioning device for temporomandibular joint specimens (schematic) a) Lateral aspect b) superior aspect For lateral tomography the device is placed in the position shown in (a) For a p tomography the device is rotated 90° around its long axis bringing the supporting leg (F) in contact with the top of the tomographic table (b) A—Holders consisting of metal plates carrying pointed pins for fixation of temporal bone and mandibular ramus B—Double ball socket joints C—Rods with movable holders (A) and double ball and socket joints (B) D—Displaceable sleeves carrying the ball and socket joints and holders E Cross guided unit for positioning the condyle in relation to the temporal portion (In the superior aspect the right holder and the double ball and socket joint have been excluded to facilitate demonstration of the cross guided unit) F—Supporting leg

Anatomy of the temporomandibular joint

A thorough knowledge of the anatomy of the temporomandibular joint will facilitate the understanding of the double contrast tomography and its results For a more detailed description cf KREUTZIGER & MAHAN (1975) and OBERG & CARLSSON (1979)

The skeletal parts of the temporomandibular joint consist of the fossa and the articular tubercle of the temporal bone and of the mandibular condyle The articulating surfaces are primarily comprised of dense collagenous connective tissue which may become cartilaginized due to functional load The joint is divided by the disc in two separate compartments upper and lower Antero posteriorly the upper compartment extends from a border several mm anterior to the most inferior prominence of the articular tubercle to the posterior part of the roof of the fossa The lower compartment caps the condyle reaching in a more inferior direction on the posterior side than on the anterior side On an a p view the upper compartment partly covers the lower compartment by a medial and a lateral recess The posterior wall of the fossa does not take part in the articulation

The disc is biconcave in the sagittal plane i e thickest anteriorly and posteriorly On the a p view the disc is semilunar often slightly thicker medially than laterally The disc can be divided into a central part which is dense and hard and a peripheral looser and softer part which merges with the surrounding capsule The thickness of the disc in the middle part is approximately one mm anteriorly and posteriorly approximately 2 and 3 mm respectively (HANSSON et coll 1977) Medially and laterally the disc is firmly attached to the condyle merging into the capsule anteriorly and posteriorly

The capsule originates from the temporal bone at the periphery of the articulating joint surface It extends inferiorly in the shape of a funnel around the mandibular condyle and attaches to the lower part of the condyle and the upper part of the mandibular neck Anteriorly and posteriorly the capsule is loose to allow for movements of the mandible Excessive displacement of the condyle is restricted by the temporomandibular ligament situated in the lateral wall of the capsule This ligament extends from the lateral inferior surface of the zygomatic arch to the lateral neck of the condyle The lateral pterygoid muscle passes through the antero medial part of the capsule inserting into the disc and the condyle

Material and Methods

Forty five right temporomandibular joint autopsy specimens were each removed en bloc through the middle cranial fossae The soft tissue covering the joint capsule was removed before radiography

A positioning device was constructed to hold the specimen during radiography (Fig 1) The holders A consisted of metal plates with pointed pins which were used for fixation of the temporal and the mandibular parts Orientation of the specimen in the positioning device was made by the aid of double ball and socket joints B The holders and the double ball and socket joints A and B could be moved along

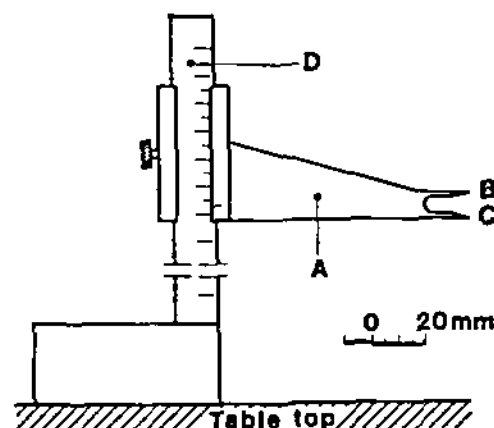


Fig 2 Indicator device for establishing the levels of tomographic sectioning in simultaneous tomography (schematic) A—Arm movable vertically B and C—Pointers The distance between B and C is equal to the distance between the uppermost and lowermost tomographic section obtained in one exposure D—Scale used for adjustment of the tomographic table

rods C in order to establish the relation between the temporal and the mandibular parts of the joint specimen The holder used for fixation of the mandibular part was placed in a cross guided unit E This unit which allowed only horizontal movement was used for examination of the joint in different antero-posterior condylar positions It was possible to define and re established each condylar position by using two coordinate axes indicated on the cross guided unit

For lateral tomography the positioning device was placed as in Fig 1 a For a p tomography the device was turned 90° bringing the supporting leg F in contact with the top of the tomographic table The 90° rotation was performed without displacing the specimen

The joint was punctured with a 14 vein point needle 0 4 mm×20 mm fixed to a 1 ml syringe graded in 0 01 ml The lower joint compartment was punctured first With the condyle in an inferior position but behind the posterior slope of the articular tubercle the puncture was made postero inferior to the condyle A resistance was felt when the capsule was passed The needle was then advanced 2 to 3 mm in an upward inward forward direction along the posterior surface of the condyle the needle was slightly tilted so that the posterior surface of the condyle could be felt with the needle tip After slight withdrawal of the needle injections were made in the following sequence 0 5 ml air 0 10 iodine contrast medium and approximately 0 8 ml air

Puncture of the upper joint compartment was performed with the condyle positioned inferior to the articular tubercle The needle was introduced approximately 3 mm behind the condyle at the level of its upper surface The needle was then advanced almost horizontally inward and forward until the needle tip made contact with the articular eminence The needle was withdrawn slightly and injections made in a sequence of 0 5 ml air 0 15 ml iodine contrast medium and approximately 1 0 ml air Between the injection of iodine contrast medium and the final injection of air into each compartment the condyle was moved frequently particularly in an antero posterior direction in order to distribute the contrast media in the joint spaces

The first 22 joint specimens were injected with Urografin 60% (sodium and methylglucamine diatrizoate 292 mg I/ml) The remaining 23 were injected with Conray (iothalamate sodium 400 mg I/ml) At a temperature of 37°C the viscosity of Urografin 60% and Conray is 4 4 mPa s and 4 5 mPa s respectively In order to maintain a uniform viscosity throughout the syringe with contrast medium was placed in 37°C water for 10 min

Radiography

The apparatus used for this investigation was a Philips Universal Polytome equipped with a Siemens Biangulix roentgen tube 150/30/50R hypocycloidal movement FFD 1 465 m focus size 0 6 mm×0 6 mm magnification factor 1 3 exposure data 60 kV 20-33 mA 6 s The diameter of the cross section of the beam in the tomographic plane was 42 mm No grid was used The radiographic examination was performed approximately 3 min after the puncture procedure and the injections

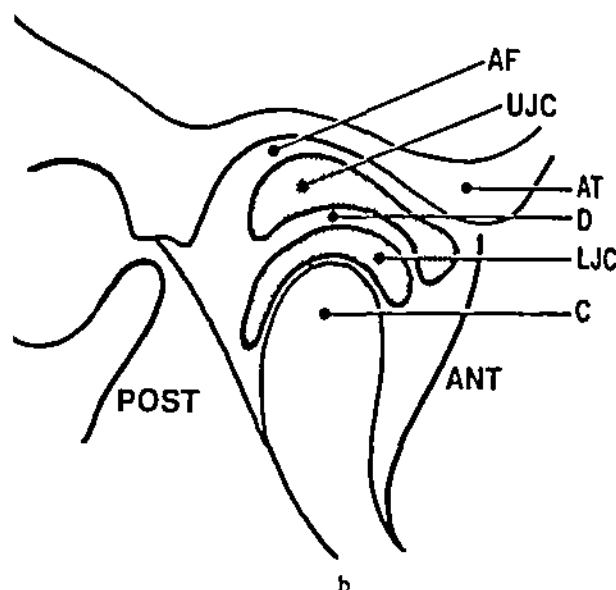
Simultaneous tomography was performed using a multi film cassette containing 5 pairs of intensifying screens (Siemens Verstärkerfolien Simultan) and 5 films (Ilford Rapid R) covering a total tissue layer of 10 5 mm Thus the interspace between the different tomographic sections was 2 5 mm

An indicator device was used for establishing the level of sectioning (Fig 2) After placing the device on the table top the arm A was adjusted in relation to the specimen The two pointers B and C indicated the uppermost and lowermost tomographic sections respectively which were obtained in one exposure The tomographic table was adjusted so that its measurements were identical to those indicated on the scale D of the indicator device

Two directions of tomographic sectioning were



a

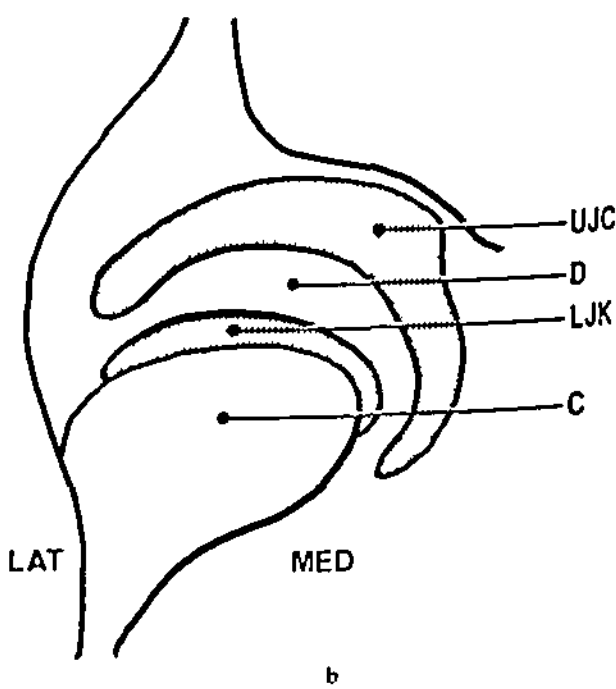


b

Fig 3 a) Lateral double contrast tomography The central part of a temporomandibular joint specimen The condyle is placed inferiorly in the fossa Upper joint compartment has a slight sigmoid shape and is located more anteriorly than the lower compartment The latter is of uniform width and is capping the condyle On the posterior surface of the condyle the lower compartment reaches further inferiorly than on the anterior surface The disc is separated from the mandibular and temporal component b) Schematic drawing of (a) AF—Articular fossa UJC—Upper compartment AT—Articular tubercle D—Disc LJC—Lower compartment C—Condyle ANT—Anteriorly POST—Posteriorly



a

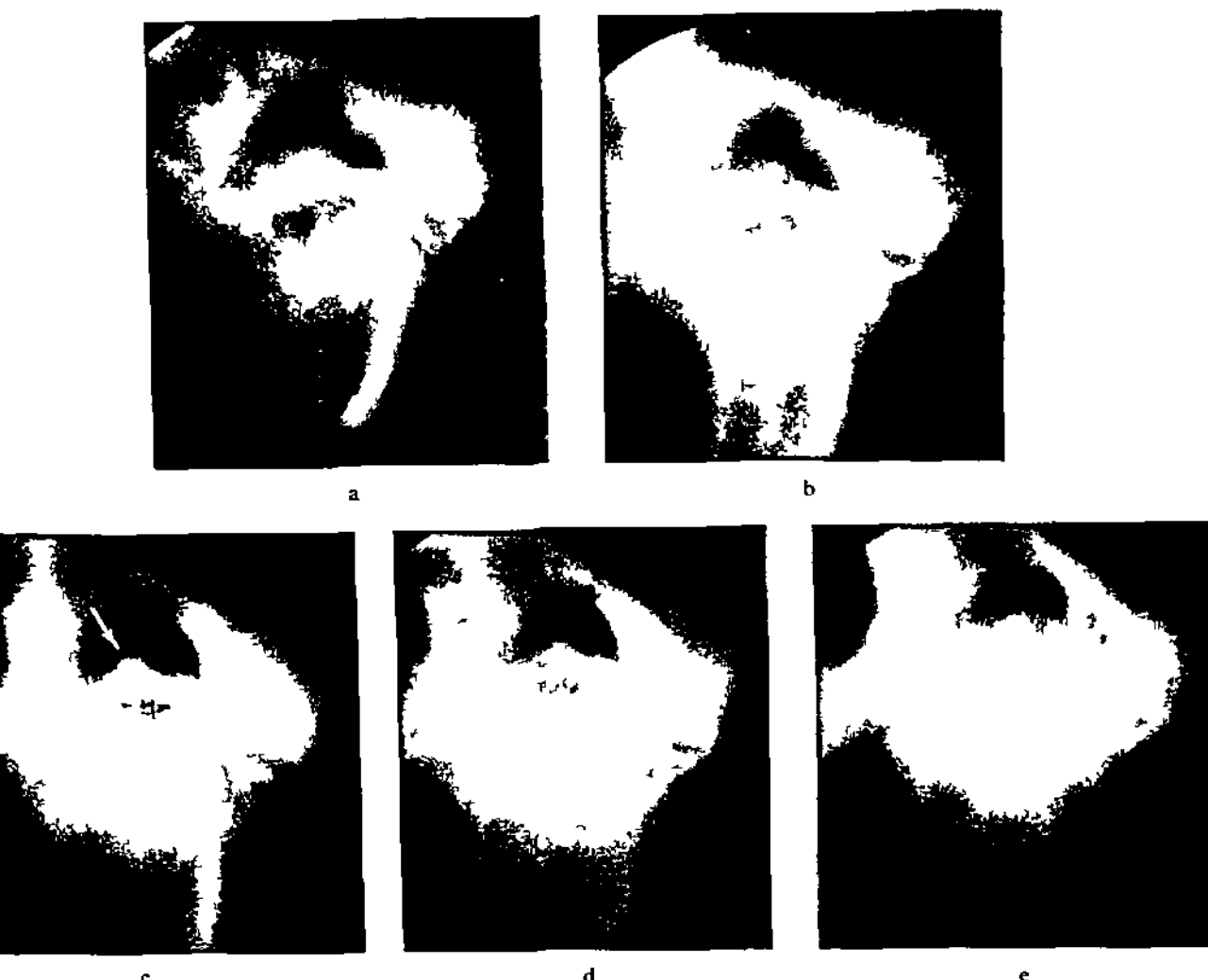


b

Fig 4 a) A p double-contrast tomography Central part of a specimen The condyle is placed inferiorly in the fossa Both joint compartments have a crescentic appearance Medially the upper joint compartment embraces the lower joint compartment Laterally the disc is attached to the lateral convexity of the condyle medially more inferiorly b) Schematic drawing of (a) UJC—Upper compartment D—Disc LJC—Lower compartment C—Condyle LAT—Laterally MED—Medially

employed lateral perpendicular to the long axis of the condyle and a p parallel to this axis

Lateral tomographs Two exposures were made using the multi film cassette The table was moved 10 mm vertically between exposures An average condyle has a latero medial dimension of approximately 20 mm (ÖBERG et coll) Thus the series of 10 tomograms obtained were distributed approximately throughout the latero-medial dimension of the joint



g 5 Lateral double-contrast tomography Series of films from ie exposure a) Most lateral view and e) most medial Distance tween each tomographic layer ~ 5 mm The shape of the disc d joint compartments depends on the tomographic layer Due local contact between the articular tubercle the disc and the ondyle in the area where the supero-anterior surface of the ondyle opposes the posterior slope of the tubercle the two joint ompartments are each seemingly divided into two chambers one posterior and one anterior In all sections the upper joint compartments have a fairly similar appearance In a medial direction the lower joint compartment deepens considerably in the posterior part The lateral part of the disc has a fairly even thickness (a) while the medial part is biconcave (d) The circular area in the posterior attachment of the disc (c) is caused by an accidental deposit of contrast medium (→)

Antero posterior tomography When the lateral omography was completed the positioning device was turned 90 placing the long axis of the condyle parallel to the table top i e to the plane of section ing The condyle was placed slightly posterior to the articular eminence Two exposures were made which were 10 mm apart The average antero-posterior dimension of the joint is approximately 20 mm (ÖBERG et coll) The resulting 10 tomograms demonstrated an antero posterior dimension of the joint containing the condyle as well as the structures situated slightly anteriorly and posteriorly

The films were developed in an Ilford Rapid R 200 automatic processor After the radiographic examination the joints were fixed in 10% neutral formalin

Results

In 40 specimens it was possible to inject both compartments of the joint The remaining 5 were only injected in one compartment as the other was accidently opened during removal of the specimens at autopsy Of the 40 specimens it was impossible to evaluate the resultant films of 3 specimens due to extensive extra articular deposits of the iodine contrast medium





Fig 6 Lateral double-contrast tomography Same tomographic layer of the central part of specimen The shape of the disc and the joint compartments depends on the position of the condyle a) Condyle is in low position behind the articular tubercle the disc is biconcave with a cranial convexity in its posterior part (→) The joint compartments are rounded b—d) Condyle is moved anteriorly step by step the disc obtains a biconvex form with a posterior caudal convexity (→) The joint compartments are stretched along the articular tubercle and the condyle (d)

Examples of lateral and a p double contrast tomography are illustrated in Figs 3 and 4 The lateral view (Fig 3 a) demonstrates the central part of the joint with the disc well separated from the temporal part and from the condyle The thickness of the disc was uniform except for the areas of attachment The walls of the 2 compartments are outlined by the contrast medium Immediately after injection the contrast medium was confined to the walls of the joint compartments but gradually penetrated through the soft tissues On the a p view (Fig 4 a) the outline of the joint is not as well defined as on the lateral view However the disc is clearly separated from the other joint components

The appearance of the joint compartments and the disc depended upon the level of sectioning (Fig 5) and the position of the condyle (Fig 6) as well as upon the amount of air injected The best over all view of the walls of the joint compartments was obtained from the middle third of the joint both in the lateral and the a p views when the condyle was positioned inferiorly in the fossa (Figs 3 4)

Frequently a local contact between the articular tubercle the disc and the condyle was observed (Figs 5 6) Occasionally this contact was maintained in the whole series of lateral films of the same joint However mostly the joint parts were separated at least in the medial third of the joint

Upper joint compartment Due to the local contact between the articular tubercle and the disc this compartment appeared as 2 chambers on many lateral tomograms

When the condyle was located behind the articular eminence the posterior chamber was generally more distended by air than the anterior one (Figs 5 6) At anterior position of the condyle both the posterior and the anterior chambers became elongated and narrow (Fig 6) In an extreme anterior position of the condyle the entire upper compartment appeared as a thin space along the tubercle (Fig 6 d) On a p views the width of the compartment appeared uniform except for the lateral and medial areas (Fig 4 a) The upper compartment often extended more caudally embracing the lower joint compartment

The disc Generally it was possible to demonstrate the disc with a very good definition particularly at lateral tomography The appearance of the disc varied considerably not only between tomographic layers (Fig 5) and different specimens (cf Figs 3–5) but also between different positions of the condyle Fig 6 illustrates a drastic change in the shape of the disc when the condyle had an anterior position In some joints the shape of the disc was biconcave in some sections (Fig 5 c) and in others it exhibited a rather uniform thickness (Fig 3 a) At a p tomography it was often difficult to obtain a definite outline of the disc However its shape and attachment to the lateral and medial poles and of the condyle appeared clearly (Fig 4 a)

Lower joint compartment This compartment covered the condyle in a cap-like fashion on both lateral and a p views (Figs 3 4) with the posterior part extending further caudally than the anterior part In

the central and medial parts of the joint the posterior part was shallower than in the lateral part (cf Fig 5a e)

Due to the local contact between the condyle and the disc which was frequently observed on lateral views this compartment seemed to be divided into a posterior and an anterior chamber The posterior chamber sometimes balloon like (Fig 6b) was easier to distend than the anterior one The anterior chamber appeared cleft shaped (Fig 5) or sac like (Fig 6 a) The more anteriorly the condyle was positioned the narrower was the lower compart ment

Discussion

The results indicate that it was possible to obtain double contrast tomograms of good quality of tem poromandibular joint specimens It was also possi ble to demonstrate the interaction between condylar position different levels of tomographic sectioning and disc configuration

Tomography appears to be the most reliable method for radiographic examination of the tem poromandibular joint (KLEIN et coll 1970 ECKER DAL 1973 GONCALVES et coll 1974 MARKOVIC & ROSENBERG 1976 OMNELL & PETERSSON 1976 STANSON & BAKER 1976 BEAN et coll LINDVALL et coll) The combination of double contrast exami nation and tomography allowed detailed demonstra tion of the soft tissue components of the joint The technique of ARNAUDOW et coll and ARNAUDOW & PFLAUM was modified by initial administration of a small amount of air which greatly facilitated the fol lowing injection and distribution of the iodine con trast medium The lower joint compartment was in jected first since it is partially covered by the upper compartment which when distended by air en croaches upon the lower compartment making the injection more difficult

Urografin 60% and Conray have approximately the same low viscosity Since Conray has a higher iodine content 400 mg I/ml against 292 mg I/ml for Urografin 60% it was used in the final 23 examina tions However no appreciable difference in rela tion to the type of contrast medium was found

Conray was also employed by ARNAUDOW et coll and ARNAUDOW & PFLAUM The amount of contrast medium injected was reduced from 0 5 to 0 15 ml and 0 5 to 0 10 ml for the upper and lower compart ments respectively during examination of the in itial 10 specimens It was felt that the smaller amounts of medium provided a better radiographic image of the joint compartments

Double contrast examination of the temporoman dibular joint requires a thorough knowledge of its anatomy The evaluation of the films was facilitated by inspection of the dissected joints

The procedure is presently being introduced in the clinical practice in patients with temporomandibular joint disorders

SUMMARY

Double-contrast tomography was applied to temporo-mandibular joint autopsy specimens Both joint com partments were given successive injections of air–iodine contrast medium–air Tomography was performed in lat eral and a p projections using a multi film cassette The shape of the disc and joint compartments was well dem onstrated The influence of the tomographic level and the position of the condyle on the appearance of the disc was analysed

REFERENCES

AGERBERG G and LUNDBERG M Changes in the tem poromandibular joint after surgical treatment A radio logic follow up study Oral Surg 32 (1971) 865

ANDERSON P W and MASLIN P Tomography applied to knee arthrography Radiology 110 (1974) 271

ARNAUDOW M und PFLAUM I Neue Erkenntnisse in der Beurteilung bei der Kiefergelenktomographie Dtsch zahnarztl Z 29 (1974) 554

— HAAGE H und PFLAUM I Die Doppelkontrastar throtomographie des Kiefergelenkes Dtsch zahn arztl Z 23 (1968) 390

BEAN L R OMNELL K Å and OBERG T Comparison between radiologic observations and macroscopic tis sue changes in temporomandibular joints Dentomaxil lofac Radiol 6 (1977) 90

BLACKWOOD H J J Arthritis of the mandibular joint Brit dent J 115 (1963) 317

CARLSSON G E LUNDBERG M OBERG T and WELAN DER U The temporomandibular joint A comparative anatomic and radiologic study Odont Revy 19 (1968) 171

CHAU-CHU C CHEN KANG C HSUAN PENG C KUANG-HSI S and YU-CHU C Evaluation of tem poromandibular arthrography in temporomandibular joint dysfunction An analysis of 60 cases (67 sides) Chin med J 10 (1973) 132 and 601

DALINKA K M BRENNAN R E and CANINO C Double contrast knee arthrography in children Clin Orthop 125 (1977) 88

ECKERDAL O Tomography of the temporomandibular joint Correlation between tomographic image and his tologic sections in a three-dimensional system Acta radiol (1973) Suppl No 329

ETO R T ANDERSON P W and HARLEY J D Elbow arthrography with the application of tomography Radiology 115 (1975) 283

FARRAR W B and McCARTY W L The TMJ dilemma J Ala dent Ass 63 (1979) 19

FIROOZNIA H SFLIGER G BARUCH H and WEATHERS R T Tomographic technique for visualization of the cruciate ligaments in double contrast arthrography Radiol Techn 47 (1976) 385

GOLDMAN A B and GHELMAN B The double contrast shoulder arthrogram Radiology 127 (1978) 655

GONCALES N MILLER A M YALE S H and ROSENBERG H M Radiographic evaluation of defects created in mandibular condyles Oral Surg 38 (1974) 474

HANSSON T and NILNER M A study of the occurrence of symptoms of diseases of the temporomandibular joint masticatory musculature and related structures J oral Rehabil 2 (1975) 313

— and OBERG T Arthrosis and deviation in form in the temporomandibular joint A macroscopic study on a human autopsy material Acta odont scand 35 (1977) 167

— — CARLSSON G E and KOPP S Thickness of the soft tissue layers and the articular disc in the temporomandibular joint Acta odont scand 35 (1977) 77

HELKIMO M Epidemiological surveys of dysfunction of the masticatory system *In* Temporomandibular joint function and dysfunction p 175 Edited by G A Zarb and G E Carlsson Munksgaard Copenhagen 1979

HORN J W The diagnosis of chondromalacia by double contrast arthrography of the knee J Bone Jt Surg 59 A (1977) 119

KATZBERG R W DOLWICK M F BALES D J and HELMS C A Arthrotomography of the temporomandibular joint New technique and preliminary observations Amer J Roentgenol 132 (1979) 949

KLEIN I E BLATTERFEIN L and MIGLINO J C Comparison of the fidelity of radiographs of mandibular condyles made by different techniques J prosth Dent 24 (1970) 419

KREUTZIGER K L and MAHAN P E Temporomandibular degenerative joint disease Part I Anatomy pathophysiology and clinical description Oral Surg 40 (1975) 165

LINDVALL A M HELKIMO E HOLLENDER L and CARLSSON G E Radiographic examination of temporomandibular joint A comparison between radiographic findings and gross and microscopic morphologic observations Dentomaxillofac Radiol 5 (1976) 24

LYNCH T P and CHASE D C Arthrography in the evaluation of the temporomandibular joint Radiology 126 (1978) 667

MARKOVIC M A and ROSENBERG H M Tomographic evaluation of 100 patients with temporomandibular joint symptoms Oral Surg 42 (1976) 838

MOFFETT B C JOHNSSON L C McCABE J B and ASKEW H Articular remodelling in the adult human temporomandibular joint Amer J Anat 115 (1964) 119

NØRGAARD F Temporomandibular arthrography Thesis Munksgaard Copenhagen 1947

OBERG T and CARLSSON G E Macroscopic and microscopic anatomy of the temporomandibular joint *In* Temporomandibular joint function and dysfunction p 101 Edited by G A Zarb and G E Carlsson Munksgaard Copenhagen 1979

— — and FAJERS C M The temporomandibular joint A morphological study on a human autopsy material Acta odont scand 29 (1971) 349

OMNELL K Å and PETERSSON A Radiography of the temporomandibular joint utilizing oblique lateral transcranial projections Comparison of information obtained with standardized technique and individualized technique Odont Revy 27 (1976) 77

ROEBUCH E J Double contrast knee arthrography some new points of technique including the use of Dimer X Clin Radiol 28 (1977) 247

SOLBERG W K WOO M W and HOUSTON J B Prevalence of mandibular dysfunction in young adults J Amer dent Ass 98 (1979) 25

STANSON A W and BAKER H L Routine tomography of the temporomandibular joint Radiol Clin N Amer 14 (1976) 105

STEINHARDT G und LANGEN P Vergleichende röntgenologische und anatomische Untersuchungen am Kiefergelenk Fortschr Röntgenstr 48 (1933) 683

THIJN C J P Double-contrast arthrography in meniscal lesions and patellar chondropathy Radiol clin (Basel) 45 (1976) 345

TOLLER P A Opaque arthrography of the temporomandibular joint Int J oral Surg 3 (1974) 17

WILKES C H (a) Structural and functional alterations of the temporomandibular joint North w Dent 57 (1978) 287

— (b) Arthrography of the temporomandibular joint in patients with the TMJ pain-dysfunction syndrome Minn Med 61 (1978) 645

ROM THE DEPARTMENT OF DIAGNOSTIC RADIOLOGY (DIRECTOR PROF J GOTHLIN) UNIVERSITY OF BERGEN MEDICAL SCHOOL HAUKELAND SYKEHUS N 5016 BERGEN NORWAY

VERTEBRAL BODY SIZE IN LUMBAR SPINAL CANAL STENOSIS

J L LARSEN and D SMITH

The outline of the spinal canal in a transverse :ction of the lumbar spine varies in different pa ents and at different levels The dominant shape is pentagon the anterior wall of which is formed by ie vertebral body Stenosis of the lumbar canal is nown to occur in some congenital disorders e g :hondroplasia and in certain acquired skeletal dis rders such as Paget s disease However in most atients no easily detectable predisposing lesion can e found It is commonly believed (VERBIEST 1976 :PSTEIN et coll 1977) that most cases of spinal tenosis are based upon an anatomic variant with arying degrees of reduction of the vertebral fora ien particularly in the sagittal direction to which re added degenerative lesions of the vertebral rches and flaval ligaments If this theory of a con ;enital or developmental basis for spinal stenosis is 'alid in the majority of patients the possibility xists of concomitant alterations in the configuration ind size of the vertebral bodies The concept of itenosis of the lumbar canal does not involve the ixial (or longitudinal) diameter of the spinal canal nor the height of the vertebrae which consequently were not estimated in the present connection

Material and Methods

The material consisted of 83 patients in whom lumbar myelography had been performed because of low back pain sciatica or suggested spinal stenosis It was divided into 3 groups (1) patients with symptoms and myelographic findings consistent with stenosis of the lumbar spinal canal (2) an intermediate group probably without definite stenosis and (3) patients definitely without clinical or radiographic evidence of spinal canal stenosis

The measurements made of the vertebral bodies were

a) The intermediate width of the vertebral body assessed as the shortest transverse diameter meas ured halfway between the upper and lower vertebral surfaces

b) The intermediate depth (or sagittal diameter) defined as the shortest antero posterior diameter measured in the mid sagittal plane halfway between the upper and lower vertebral body surfaces

The anatomic points of reference were chosen in order to evade as far as possible degenerative le sions especially common at the vertebral edges For further details cf LARSEN & SMITH (1980)

Results

The results are presented in Figs 1 and 2 No difference in mid sagittal or mid transversal diame ters of the vertebral bodies between the three patient groups could be demonstrated The same anatomic references were employed as those used by SAND (1970) on anatomic material with good correlation of the results However allowance must be made for the fact that the skeletal material reported on by SAND as is usual in anatomic investigations on bones dates several hundred years back in age People at that time were of a shorter stature which undoubtedly must have been reflected in their ver tebrae

Sagittal vertebral body diameter In all 3 groups a slight increase from the first to the third lumbar vertebra was found hardly any difference existed between the fourth and the fifth The difference

Submitted for publication 14 December 1979

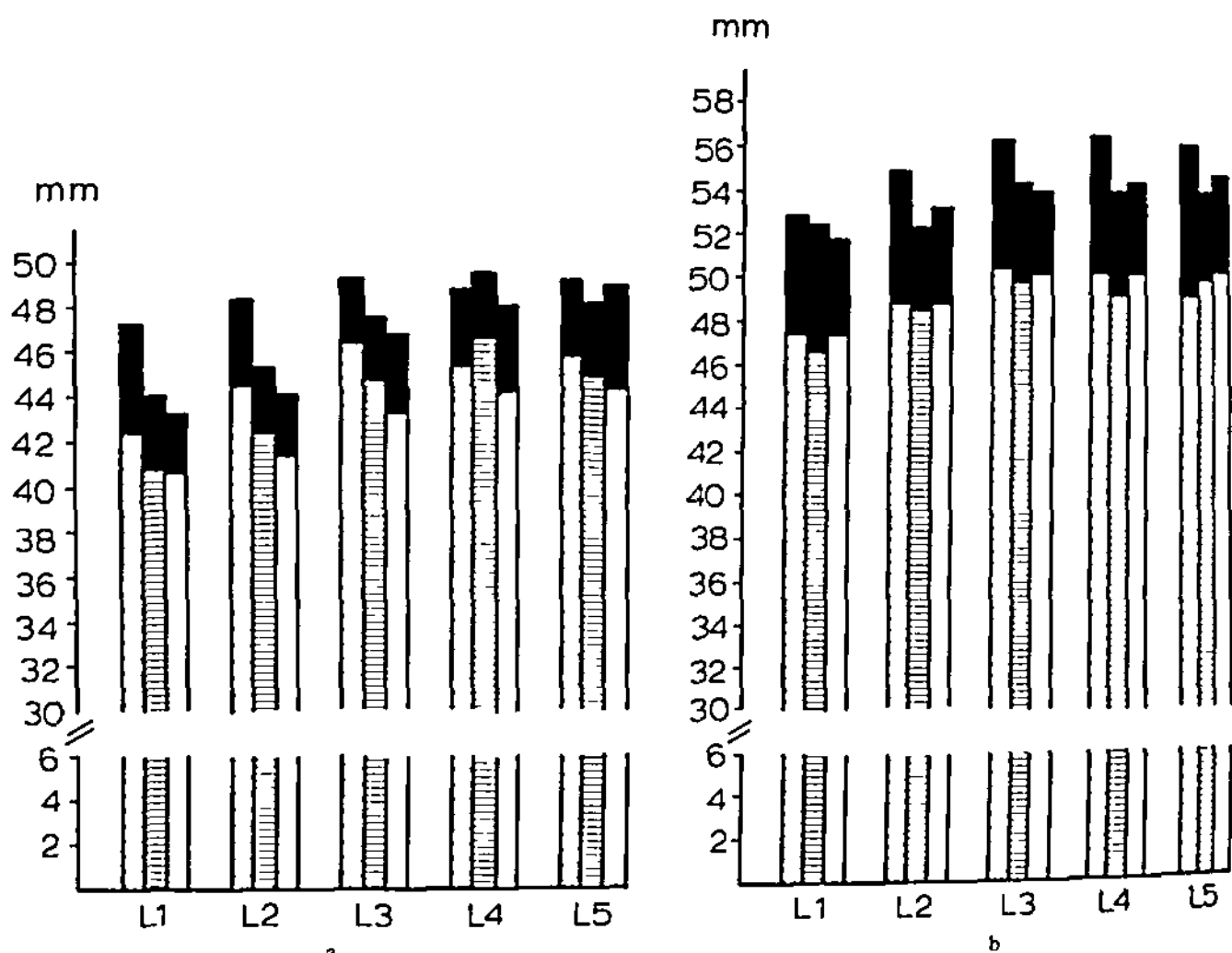


Fig 1 Mean sagittal diameter of lumbar vertebral bodies in the three groups (1=▢ 2=⊟ 3=□ 1 SD added=■) a) Females b) males

between the males and the females in the various groups varied between 7 2 mm as maximum (group 3 at L2) and 3 3 mm as minimum (group 1 at L5)

The sex difference of the mean values estimated by SAND was between 3 and 4 mm from L1 to L5 Taking the factor of magnification into account the difference between the mean values between the sexes in the present series was never larger than 5 1 mm

Transverse vertebral body diameter This was larger in group 1 than in groups 2 and 3 regardless of sex the difference ranging from 4 9 mm (females at the first lumbar level) down to 1 9 mm (males at first lumbar level) The most probable explanation of the difference however small in group 1 versus the others is variation in age the mean age in group 1 being 10 to 11 years higher than in groups 2 and 3 SAND made a detailed analysis of the influence of age only with regard to L2 and L5 and found an increasing transverse diameter with increasing age

Discussion

At first shown by HUIZINGA et coll (1951) and later confirmed by SAND the sagittal diameter of the vertebral canal gradually decreases from L1 to L3 no significant difference exists between L3 and L4 but it increases from L4 to L5 The relative narrowing in the middle part of the canal is considered to be predisposing for stenosis of the lumbar canal which has a predilection for the L3/L4 interspace with the L4/L5 and L2/L3 levels second and third

The same authors found a definite increase in the interpedicular distance (which can be regarded as synonymous with the transverse diameter of the vertebral foramen) from L4 to L5 but no significant

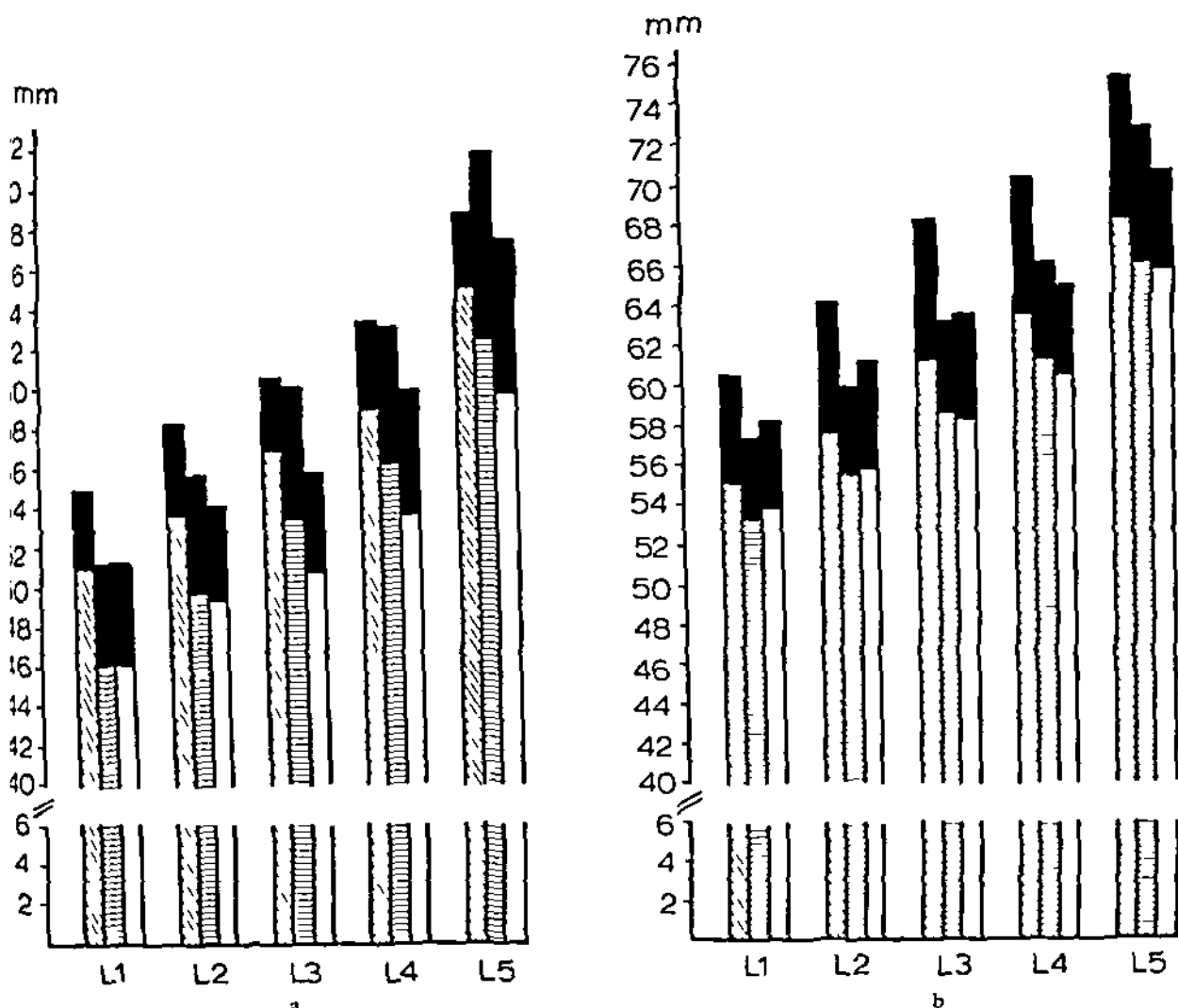


Fig 2 Mean transverse diameter of lumbar vertebral bodies in the groups marked as in Fig 1 a) Females b) males

difference between the upper four lumbar vertebrae (the Lapps in SAND s series excluded) As evident in the figures the external shape of the vertebral bodies did not follow this configuration neither in patients with stenosis nor in controls

Theoretically the vertebrae and the spinal canal can be related in three ways (a) Small and large vertebrae can have respectively small and large vertebral foramina (b) the vertebral foramen can be independent of the vertebra (within certain limits) and (c) the larger the vertebra the thicker its walls around the vertebral foramen which subsequently can be small and vice versa

These possibilities do not seem ever to have been explored to the full extent JONES & THOMSON (1968) compared proportional measurements of the bony lumbar canal and the vertebral bodies in patients with lumbar stenosis and in controls demonstrating a smaller ratio (canal/body) in patients with stenosis RAMANI (1976) did the same in patients with disc prolapse and in controls also finding a smaller ratio in the first group He concluded that patients with prolapsed lumbar discs necessitating operation had canals tending to be narrower than normal The present results support the view that the decrease in ratio is not caused by overgrowth of the vertebral body which should then have increasing diameters from group 3 to 1 The increase in size of the vertebral body in horizontal diameter beyond the age when growth usually subsides is dependent on the periosteal bone growth on its vertical surfaces The vertical diameter is a product of enchon

dral bone apposition terminating at the end of pubescence

Of the theoretic possibilities presented the series does not support hypothesis (a) nor (c) As shown by ELLIOT (1945) the cross sectional area of the spinal cord is independent of sex height and weight the same holds true for the dural sac and the included subarachnoid space at least in a p diameter (DE VILLIERS & BOOYSEN 1976) These factors then do not influence the necessity of adequate foraminal diameters which should also favour hypothesis (b)

The patients were unselected and except for degenerative lesions none of the patients had evidence of skeletal disorder that should predispose for spinal stenosis The investigation confirms the supposition that lumbar canal stenosis is based upon developmental or degenerative lesions in the posterior part of the vertebral canal and not in the vertebral bodies Congenital or developmental factors predisposing for stenosis do not manifest themselves in the sagittal or transverse diameters of the vertebral bodies

SUMMARY

The transverse and sagittal diameters of the lumbar vertebral bodies have been compared in patients with symptoms and myelographic findings consistent with stenosis of the lumbar canal in patients with some narrowing of the lumbar canal and in patients without clinical or myelographic indication of stenosis No significant difference in the measured diameters was found

REFERENCES

DE VILLIERS P D and BOOYSEN E L Fibrous spinal stenosis A report on 850 myelograms with a water soluble contrast medium Clin Orthop 115 (1976) 140

ELLIOT H C Cross sectional diameters and areas of human spinal cord Anat Rec 93 (1945) 287

EPSTEIN B S EPSTEIN J A and JONES M D Lumbar spinal stenosis Radiol Clin N Amer 15 (1977) 227

HUIZINGA J HEIDEN J A v d and VINKEN P J J G The human lumbar vertebral canal A biometric study Proc kon ned Akad Wet Ser C 55 (1951) 22

JONES R A C and THOMSON J L G The narrow lumbar canal J Bone Jt Surg 50B (1968) 595

LARSEN J L and SMITH D Size of the subarachnoid space in stenosis of the lumbar canal Acta radiol Diangosis 21 (1980) 627

RAMANI P S Variations in size of the bony lumbar canal in patients with prolapse of lumbar intervertebral discs Clin Radiol 27 (1976) 301

SAND P G The human lumbo sacral vertebral column An osteometric study Universitetsforlaget Oslo 1970

VERBIEST H Neurogenic intermittent claudication *Lesions of the spinal cord and cauda equina stenosis of the vertebral canal narrowing of the intervertebral foramina and entrapment of the peripheral nerves In* Handbook of clinical neurology Vol 20 p 611 Edited by P J Vinken and G W Bruyn North Holland Publ Co Amsterdam 1976

FROM THE DEPARTMENT OF DIAGNOSTIC RADIOLOGY III (DIRECTOR DOCENT C-G HELANDER) SAHLGRENSKA SJUKHUSET S-411 32 GOTHENBURG SWEDEN

RECEPTOR SATURATION IN ROENTGEN FILMS

K G STRID and S REICHMANN

Commencing a series of mathematical investigations of quantum fluctuations in radiographic imaging an analysis was given of fluctuations in the radiation relief and some implications with regard to image recording (STRID 1980) It was shown how image quality as described by the signal to noise ratio of the radiation relief or the recorded pattern increases with increasing photon fluence which entails increased dose to the patient It was pointed out how improved secondary screening though reducing the informative (image forming) radiation flux will lead to image improvement or dose reduction Although dynamically limited recording devices were considered the behaviour of photographic detectors was not treated in any detail

The roentgen film is the component that stores image information in conventional radiography The information causing silver to be precipitated in the film layers is carried by quanta (photons) of visible light or roentgen radiation Only a fraction of the total number of intercepted photons contributes to the final image the remainder being lost without being detected In all kinds of photography where the number of photons is limited such as high speed radiography efficiency in utilising the available photons is of primary interest An important characteristic of a photon detector therefore is its detective quantum efficiency (DQE) which plays a decisive role in determining the final image quality

The contribution to image quality made by the film has been only sparsely investigated since the films is considered not to give rise to significant image unsharpness (MORGAN et coll 1964) However accumulating evidence indicates that in screen film radiography unsharpness is not of the crucial importance hitherto believed (GRAY et coll 1978 REICHMANN et coll 1978 1979 a b SELIN & REICHMANN 1979 a b) Instead the creation of background noise from the relative shortage of image forming photons appears to be more important This inevitably leads to efforts being made to improve the detective quantum efficiency so that the available photons may be utilised as completely as possible

The detecting layers of a roentgen film contain large numbers of microscopic receptors the silver halide grains Each of these has a threshold level for excitation by intercepted photons When this level is exceeded the grain becomes developable On exposure to light several photons are required for the threshold to be reached whereas with roentgen radiation a single photon is sufficient due to the roentgen photon s greater energy content (e g TER POGOSSIAN 1967) When the film is used with intensifying screens the final image is indeed produced by light photons However due to the large number of light photons emitted by the screens on absorption of a single roentgen quantum the combined effect of the film screen system will be rather similar to the response of a non screen film

An individual receptor has two distinct modes of

Submitted for publication 27 September 1979

reaction (white and black) and the total number of receptors is finite Image detectors sharing these properties with photographic film have been analysed theoretically by DAINTY & SHAW (1974) showing receptor saturation to be an important feature of such detectors During exposure to photons an increasing number of silver halide grains in the film layers become developable which in turn means that they will not react to further exposure A photon arriving late in the exposure hitting a silver halide grain which has already become developable will not be able to transfer its information to the film—the receptor struck by this photon is already saturated The information carried by the photon is thus lost which implies a defect in the detective quantum efficiency When the density of the film increases an ever larger number of receptors become saturated which means decreasing detective quantum efficiency Still there may be so many receptors left unsaturated in the near vicinity that further increase of density may take place Actually in a first approximation for the optical density (D) amounting to 1 0 already 90 per cent of the film surface is covered with silver for an increase to D=2 0 only another 9 per cent need become covered and for a further increase to D=3 0 merely another 0 9 per cent Thus receptor saturation does not necessarily lead to decreasing contrast even though it will cause the recording of small object details having low attenuation differences (such as pulmonary vessels) to become increasingly defective when background density is increased This phenomenon was demonstrated experimentally by SELIN & REICHMANN (1977) and REICHMANN et coll (1978) In these investigations image details of the kind mentioned were recorded at low and high background density where the same contrast (gamma) occurred Despite identical contrast the recording was always clearly impaired at high density The loss of image quality was therefore denoted high density failure

In the present report are presented some computations on a simple model of photographic recording performed in order to increase the understanding of the interrelations between detective quantum efficiency and film density and contrast Certain simplifying assumptions were made so as to provide an analysis easy to survey Still the results demonstrate such good agreement with previous observations of high-density failure as to render the simplifications justified

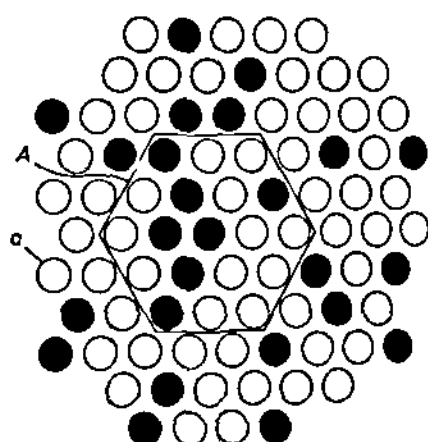


Fig 1 Part of model photographic detector being a uniform array of elementary receptors each of area a The image element to be resolved of area A is comprised of a large number (n) of receptors

A simplified mathematical approach for demonstrating receptor saturation

The features of a simple detecting model will be analysed essentially as outlined by DAINTY & SHAW (1974) The reader who is unfamiliar with stochastic variables is referred to the previous report (STRID 1980 Appendix) to which equation numbers prefixed with an A relate

Imagine a photographic detector composed of a large number of elementary receptors of area a uniformly distributed in a single layer over the detector plane (Fig 1) Each elementary receptor is assumed to possess the following properties

(1) Before exposure to roentgen radiation the receptor is perfectly transparent to light
(2) a roentgen photon hitting the receptor area will be absorbed by the receptor with probability η and
(3) the first time a roentgen photon is absorbed by the receptor the receptor will turn completely opaque (black)

These assumptions make a first-order approximation to the properties of a non screen roentgen film but the overall function of a film screen combination is roughly described by them as well

Density versus exposure characteristic Consider a region of the detector plane of area A containing n elementary receptors Suppose that p out of these are black Let the detector be viewed in transmitted light perpendicularly incident with intensity I_0 The region considered will then transmit on an average the intensity

$$I=I_0(1-pa/A) \tag{1}$$

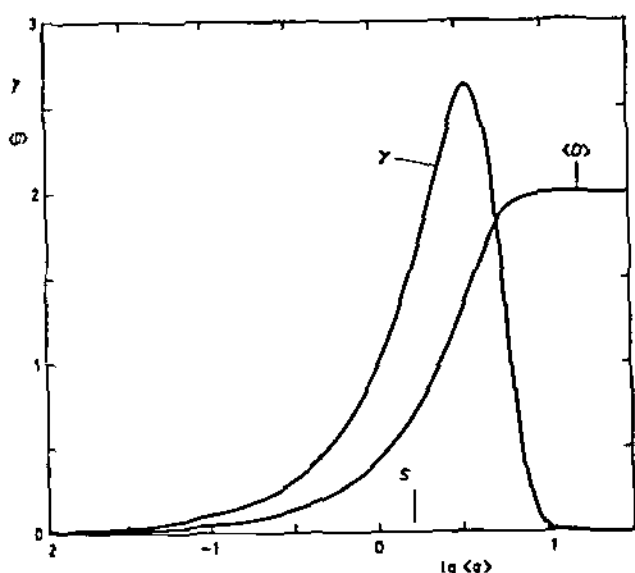


Fig 2 Characteristic of model photographic detector having $D_{max}=2\ 0$ showing density (D) versus the logarithm of the exposure and the associated contrast gradient (γ) The exposure is taken as the mean number of roentgen photons absorbed per elementary receptor $(\langle q \rangle)$ The exposure value at which maximum signal to noise ratio (S_m) obtains is indicated by a vertical bar

whence the optical density of the region is

$$D \equiv -\lg(I/I_0) = -\lg(1-pa/A)$$

If all the elementary receptors are black the density will attain its maximum value

$$D_{max} = -\lg(1-na/A) \qquad (2)$$

Suppose that the detector region of area A was exposed to the fluence Φ of roentgen photons Since the roentgen flux forms a Poisson-distributed stochastic process the number q of photons absorbed by any single elementary receptor is not a priori predictable however *its mean value is known* to be

$$\langle q \rangle = \eta \Phi a \qquad (3)$$

The probability that exactly m photons were absorbed is given by the Poisson-distribution frequency function (A 17) as

$$P(q=m) = \exp(-\eta\Phi a)(\eta\Phi a)^m / m!$$

In particular then the probability that no photon was absorbed is

$$P(q=0) = \exp(-\eta\Phi a) = \exp(-\langle q \rangle) \qquad (4)$$

leaving the probability

$$P(q \geq 1) = 1 - \exp(-\langle q \rangle) \qquad (5)$$

of at least one photon having been absorbed implying that the receptor has turned black Thus the mean number of black receptors in the region considered containing n receptors is found to be

$$\langle p \rangle = nP(q \geq 1) = n[1-\exp(-\langle q \rangle)] \qquad (6)$$

whence the mean value of the optical density will be

$$\langle D \rangle = -\lg\{1-(na/A)[1-\exp(-\langle q \rangle)]\} \qquad (7)$$

where $\langle q \rangle$ is given by eq (3) Eq (7) relating optical density D to incident fluence of roentgen photons Φ represents the characteristic of the detector In Fig 2 this relation is represented graphically for $D_{max}=2\ 0$ i e for $na/A = 0\ 99$ as seen from eq (2)

Contrast gradient The detector s ability to render contrast is described by its contrast gradient (gamma) being by definition the derivative of the optical density with respect to the common logarithm of the exposure $\gamma \equiv d\langle D \rangle / d \lg \Phi$ From eq (3) it follows that $d \lg \Phi = d \lg \langle q \rangle$ and hence

$$\gamma = d\langle D \rangle / d\lg\langle q \rangle = (\langle q \rangle / \lg e)\, d\langle D \rangle / d\langle q \rangle \qquad (8)$$

$\lg e \approx 0\ 4343$ being the common logarithm of the base of natural logarithms Differentiation of eq (7) and insertion into eq (8) yield

$$\gamma = \frac{(na/A)\langle q \rangle \exp(-\langle q \rangle)}{1-(na/A)[1-\exp(-\langle q \rangle)]}$$

which is displayed in Fig 2 for $na/A = 0\ 99$

Signal to noise ratio Consider the case where details of a radiographic object are projected onto contiguous detector regions 1 and 2 both of area A If the photon fluence at the detector plane has values Φ_1 and Φ_2 respectively in the two regions the radiation contrast is defined as

$$C \equiv \frac{|\Phi_1 - \Phi_2|}{\frac{1}{2}(\Phi_1 + \Phi_2)} \qquad (9)$$

Emission absorption and scattering of roentgen photons taking place stochastically no exact a priori statements can be made as to the numbers of photons actually intercepted by the two regions This uncertainty is the essence of quantum noise

The imaging quality of the radiation relief is described by the signal to noise ratio (cf STRID 1980) which for details of size A and contrast C obtains as

$$S=C\sqrt{\tfrac{1}{2}\Phi A} \qquad (10)$$

where

$$\Phi\equiv\tfrac{1}{2}(\Phi_1+\Phi_2) \qquad (11)$$

When interacting with the detector the radiation will produce p_1 and p_2 black receptors in regions 1 and 2 respectively Let the detector be viewed in transmitted light of incident intensity I_0 Then it follows from eq (1) that the light intensity transmitted will be $I_1=I_0(1-p_1a/A)$ and $I_2=I_0(1-p_2a/A)$ respectively in the two regions The signal thus produced will be

$$\delta I\equiv I_1-I_2=-I_0(a/A)(p_1-p_2) \qquad (12)$$

The numbers of black receptors being subject to stochastic uncertainty δI will not be a priori predictable however by eq (A 11) its mean value is known to be $\langle\delta I\rangle=-I_0(a/A)(\langle p_1\rangle-\langle p_2\rangle)$ and thus eqs (3) and (6) yield

$$\langle\delta I\rangle=I_0(na/A)[\exp(-\eta\Phi_1 a)-\exp(-\eta\Phi_2 a)]$$

Now the case of essential interest is that of faint contrast i e $C\ll 1$ then by the approximation

$$\exp x\approx 1+x \text{ for } |x|\ll 1 \qquad (13)$$

$$\exp(-\eta\Phi_i a)=\exp(-\eta\Phi a)\exp[-\eta(\Phi_i-\Phi)a]$$
$$\approx\exp(-\eta\Phi a)\eta(\Phi-\Phi_i)a$$

($i=1$ 2) where Φ is defined by eq (11) Thus the mean signal obtains as

$$\langle\delta I\rangle\approx I_0(na/A)\exp(-\eta\Phi a)\eta a(\Phi_2-\Phi_1) \qquad (14)$$

For the variance of δI being an appropriate measure of the stochastic uncertainty eqs (A 10) and (A 13) yield with eq (12)

$$\operatorname{var}(\delta I)=(I_0a/A)^2[\operatorname{var}(p_1)+\operatorname{var}(p_2)] \qquad (15)$$

For the calculation of the variance of the numbers p_1 and p_2 it is noted that the n receptors of a region are turned black independently of each other If the number of black receptors within a region is p then it follows from the repeated application of eq (A 13) that

$$\operatorname{var}(p)=n\operatorname{var}(p_0) \qquad (16)$$

p_0 being the response of a single receptor A receptor responds to exposure either with $p_0=0$ provided no photon has been absorbed by it or $p_0=1$ in case it has absorbed at least one photon Then according to the definition (A 2)

$$\operatorname{var}(p_0)=\mathrm{P}(p_0=0)(0-\langle p_0\rangle)^2+\mathrm{P}(p_0=1)(1-\langle p_0\rangle)^2 \qquad (17)$$

The mean response $\langle p_0\rangle$ equals the probability of the receptor being blackened given by eq (5) and the probabilities $\mathrm{P}(p_0=0)$ and $\mathrm{P}(p_0=1)$ are given by eqs (4) and (5) respectively Insertion into eq (17) and simplification yield

$$\operatorname{var}(p_0)=\exp(-\eta\Phi a)[1-\exp(-\eta\Phi a)]$$

From eqs (15) and (16) it is then found that

$$\operatorname{var}(\delta I)=(I_0a/A)^2n\{\exp(-\eta\Phi_1 a)[1-\exp(-\eta\Phi_1 a)]$$
$$+\exp(-\eta\Phi_2 a)[1-\exp(-\eta\Phi_2 a)]\}$$

whence since $\Phi_1\approx\Phi_2\approx\Phi$ the standard deviation of the signal comes out as

$$\sigma(\delta I)\approx I_0(a/A)\sqrt{2n\exp(-\eta\Phi a)[1-\exp(-\eta\Phi a)]} \qquad (18)$$

The signal to noise ratio which was defined by eq (10) in the previous report (STRID 1980) is then finally obtained for the recording process from expressions (14) and (18) as

$$S=\frac{\langle\delta I\rangle}{\sigma(\delta I)}=C\eta\Phi a\sqrt{\frac{n\exp(-\eta\Phi a)}{2[1-\exp(-\eta\Phi a)]}} \qquad (19)$$

where C is the object contrast defined by eq (9) and $\eta\Phi a$ is the mean number of roentgen photons absorbed by a single elementary receptor

Numerical evaluation shows that S given by eq (19) reaches a maximum value $S_{max}\approx 0\ 569C\sqrt{n}$ for $\eta\Phi a\approx 1\ 594$

Two limiting cases It is interesting to observe the behaviour of the signal to noise ratio at varying the exposure level

(a) Let the number of photons absorbed be small as compared to the number of receptors i e let $\eta\Phi a\ll 1$ Then by the approximation (13) eq (19) simplifies to

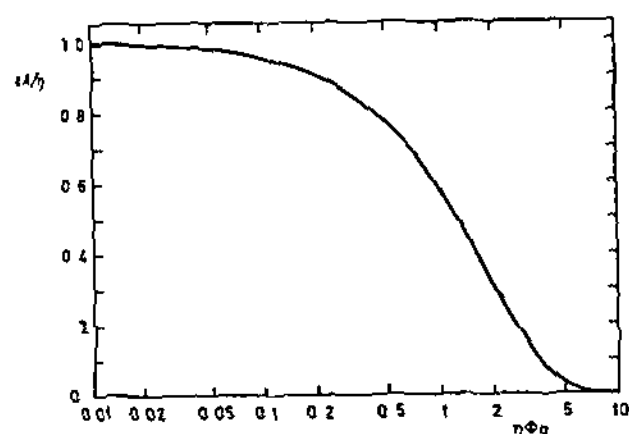


Fig 3 Detective quantum efficiency (ε) of model detector in Fig 1 normalised with regard to photons actually absorbed the factor $\eta na/A$ expressing the absorption efficiency $\eta\Phi A$ is the mean number of photons absorbed by an elementary receptor

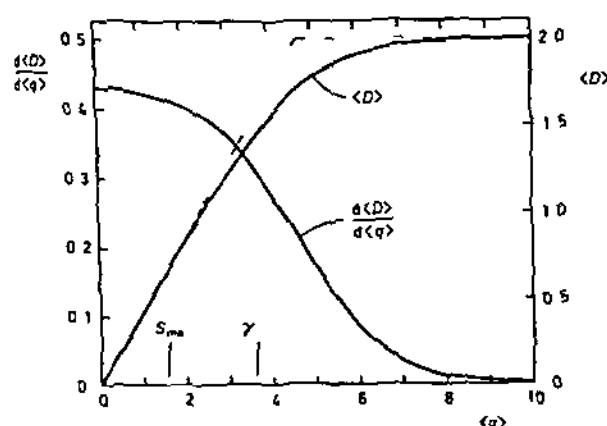


Fig 4 Characteristic of model detector with D_{max} = 2 0 and its first derivative represented linearly in respect of exposure The vertical bars indicate the exposure values at which maximum signal to noise ratio (S_m) and maximum contrast (γ_{max}) occur

$$S \approx C\sqrt{\tfrac{1}{2}\eta\Phi na}$$

For an ideal detector with elementary receptors covering the detective plane completely and with perfect absorbance $\eta na = A$ and then the detecting process renders the signal to noise ratio of the radiation relief given by eq (10)—the signal pattern is not impaired by the detecting process

(b) Let the number of photons absorbed be so large that $\eta\Phi a \gg 1$ Then $\exp(-\eta\Phi a) \to 0$ and eq (19) becomes

$$S \approx C\eta\Phi a\sqrt{\tfrac{1}{2}n}\exp(-\eta\Phi a)$$

For increasing values of Φ the exponential factor makes $S \to 0$ i e the detector will lose its recording capacity *This is the limit of receptor saturation* which means that the elementary receptors will not produce any further useful response to increased photon fluence

Detective quantum efficiency The quality of the quantum recording process is conveniently described by the detective quantum efficiency ε of the process (ROSE 1946 JONES 1959 DAINTY & SHAW §5 1) This quantity expresses how large a fraction of the photons actually contributes in the recording If a radiation relief of intrinsic signal to noise ratio S is recorded by a process yielding the ratio S then

$$S \approx \sqrt{\varepsilon}S \tag{20}$$

As long as $\varepsilon \approx 1$ the recording is close to ideal For decreasing values of ε an increasing amount of noise is created by the recording process leading to irreversible loss of information

For the recording process considered here eqs (10) (19) and (20) yield

$$\varepsilon = \frac{\eta na}{A} \times \frac{\eta\Phi a\exp(-\eta\Phi a)}{1-\exp(-\eta\Phi a)}$$

The first factor $\eta na/A$ expresses the absorption efficiency of the detector Actually in the limiting case where the elementary receptors cover the detector plane entirely and all impinging photons are absorbed this factor approaches unity The remaining factor being a function of $\eta\Phi a$ i e the mean number of photons absorbed by an elementary receptor is the mathematical expression of receptor saturation ε is a monotonously decreasing function of $\eta\Phi a$ (Fig 3)

Analysis

A somewhat different representation of the density versus exposure characteristic of the model film with D_{max}=2 0 is given in Fig 4 Contrary to usual practice the exposure is not indicated logarithmically on the horizontal axis but linearly Since a single roentgen photon is sufficent to make a silver halide grain developable a linear relationship is to be expected in such a diagram At low values of density this is seen to be the case Above $D \approx 0$ 65 the graph visibly deviates from linearity the deviation increasing with higher density However inspection of the first derivative of the characteristic discloses that there is no definite threshold density above which the film no longer responds linearly Still below $D \approx 0$ 65 the deviation from linearity is

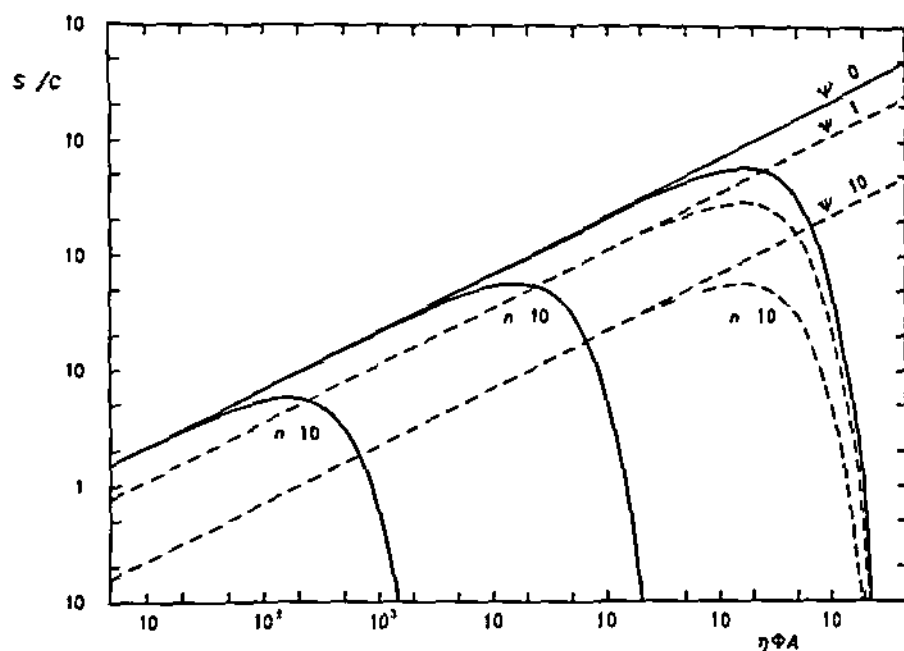


Fig 5 Signal to noise ratio normalised with regard to primary radiation contrast of the primary radiation relief (solid straight line) and of the recorded images produced in the absence of secondary radiation by photographic detectors having different numbers (n) of grains in the resolution element (solid curves) The influence of secondary radiation is demonstrated for n 10' by the dashed straight lines and curves for a moderate (ψ 1) and a high (ψ=10) value of the relative secondary radiation fluence

negligible The mechanism underlying the deviation is in fact receptor saturation which means that this phenomenon is essential in the density range 0 65 to 2 0

If the signal to noise ratio is assumed to be the factor determing image pattern visibility (STURM & MORGAN 1949 MOTZ & DANOS 1978 STRID 1980) the behaviour demonstrated in Fig 4 must be combined with appropriated knowledge of the complete radiographic process Increased exposure which yields increased precipitation of silver on the film goes together with increased fluence of roentgen photons which implies a decrease of quantum mottle in the radiation relief Then for the film whose characteristic appears in Fig 3 there must exist an optimum beyond which further exposure will lead to high-density failure due to receptor saturation of such a magnitude as to outweigh the reduction of quantum mottle In Fig 5 the logarithm of the signal to noise ratio is represented versus the logarithm of the exposure The solid straight line demonstrates the signal to-noise ratio of the roentgen relief proper steadily increasing with exposure Below this line three curves appear pertaining to three different grain sizes giving respectively 10- 10' and 10' grains within the area occupied in the image by a small object detail (the resolution element)

These graphs demonstrate the signal to noise ratio of the recorded film image so that at any particular exposure value the distance between the straight line and one of the curves demonstrates the effect of receptor saturation for the film considered The three curves behave similarly At low exposure values they follow the straight line closely at increased exposure they tend to deviate from the line and finally they drop catastrophically Each curve attains a maximum For the film having 10- silver halide grains per resolution element this occurs at exposure to 1 59×10 roentgen photons in the element similarly for 10' grains per resolution element the maximum occurs at 1 59×10' photons to the element and so on Obviously each of these values indicates the maximum value of the signal to noise ratio that may be obtained with the emulsion in question For exposure values below the maximum image quality is limited by quantum mottle and above this maximum receptor saturation is the decisive limitation

Fig 2 presents the characteristic of the film with D_{max}=2 0 in the conventional mode exposure being logarithmically indicated The first derivative of the characteristic i e the contrast gradient γ is also drawn Contrast is seen to attain a distinct maximum γ=2 63 at an average of 3 62 photons

bed per silver halide grain corresponding to 44 If contrast were the most important quan leterminıng recording quality then optimum :ring of the image would occur at this density

However the maximum of the signal to ratio is found at an average of 1 59 photons bed per grain giving merely $D=0$ 64

luence of secondary radiation The passage of tion through bodies inevitably entails the gen on of secondary (non informative) radiation due attering and fluorescence (cf STRID 1976) The ve fluence of secondary radiation is con ntly described by a parameter ψ denoting the between the exposure due to secondary radia and that due to primary (informative) radia In the presence of secondary radiation the gen relief will suffer from increased quantum le This impairment is reflected as a reduction e signal to noise ratio (STRID 1980) as indicated ashed lines in Fig 5 for a moderate case (ψ= g pulmonary radiography) and a severe case 10 e g abdominal radiography) The signal to- e ratio of the resulting recording is also shown ach of these cases for the film with 10^6 grains esolution element It is seen from the graph that impairment due to receptor saturation becomes e marked when the relative fluence of secondary ation increases

Discussion

reviously (SELIN & REICHMANN 1977 REICH NN et coll 1978) it was demonstrated experimen y that small image components of low contrast recorded by roentgen film not according to the trast gradient (gamma) value of the film but in a y suggesting that receptor saturation (i e high sity failure) may be of importance The present culations although pertaining to a simplified hematical model confirm the assumptions of se previous reports indicating that optimum re ding may be obtained at a density value where itrast is submaximal For a film having D_m = optimum density was calculated to be 0 64 This he value where the characteristic of Fig 4 is be ning to deviate visibly from linear response Even implifications are inherent in the mathematical ocedures the conclusion to be drawn from the sent analysis is that receptor saturation will be an portant source of impairment of the signal to ise ratio In fact the loss of information thus brought about should be considered more treach erous than noise of other origin If for example the quantum mottle is increased the image becomes visibly noisy and the mottle may be evaluated by microdensitometry Receptor saturation on the other hand does not manifest itself directly it merely leads to the disappearance of small low contrast details and inspection of the film itself does not give any clue as to the mechanism underlying the loss of information For this reason receptor saturation may very easily be overlooked and con sidered unimportant Therefore the present calcula tions may be valuable despite their inherent simpli fications since they provide an incentive to further exploration of receptor saturation as a source of im paired image quality

One aspect of receptor saturation is the reduction of the detective quantum efficiency of the film at high values of exposure As an illustration this effi ciency as calculated for the model film has been represented in Fig 3 It is evident that the detective quantum efficiency is essentially lost far below the region of maximum contrast Indeed even at the point of maximally attainable signal to noise ratio (with on the average 1 59 photons absorbed per grain) the efficiency is as low as 0 41 i e only 2 out of 5 absorbed photons will contribute to image formation whereas for maximum contrast rendering (where 3 62 photons are absorbed per grain) it has fallen to 0 099—only every tenth photon conveys useful information In the case of actual roentgen films the situation is still more unfavourable for silver halide grains are rather bad absorbers of roentgen photons therefore the detective quantum efficiency at maximum signal to noise ratio will be considerably lower of the order of perhaps 0 05

Another important point regarding receptor saturation concerns radiography with stationary scattered ray grids (REICHMANN & STRID 1976) Behind such a grid the radiation relief varies con siderably behind the lead lamellae very few photons appear leaving the film underexposed there However in routine practice the exposure is carried out so that the overall impression of the re cording is one of normal exposure But the film will still not contain any relevant information behind the lead lamellae whereas behind the inter spaces information will be unnecessarily lost due to receptor saturation

In standard textbooks on photography (MEES & JAMES 1966 FRIESER 1975) receptor saturation

is occasionally mentioned albeit in a somewhat casual way However roentgen photography operates at greater density values than most other types of photography which may render receptor saturation more important in this case To a certain degree the high density values encountered in radiography derive from the use of double emulsions on roentgen film Insofar as the results obtained in the present analysis may be applied to such films it may be expected that optimum density would be $D \approx 1\ 3$ for a film with $D_{max}=4\ 0$ since the two emulsions illuminated by diffuse light and separated by a certain distance may be assumed to operate independently of each other Above this density value *a rapid decline in film performance is to be expected* and indeed has been found to occur Still clinical films usually display density values of up to $\approx 2\ 0$ while the useful part of the characteristic bends off into the toe region at density values not very far below the optimum

SUMMARY

Roentgen film recording of small object details of low attenuation differences (e g pulmonary vessels) is regularly seen to be impaired when the film is exposed to yield high values of optical density (D) This high density failure is due to receptor saturation which implies that at high exposure values most silver halide grains of the film are made developable leaving few grains available to receive additional informative photons The receptor saturation is analysed by means of a mathematical model of a non screen film yielding $D_m = 2\ 0$ Optimum recording defined by maximum signal to noise ratio in the image is found at $D \approx 0\ 64$ corresponding to on an average 1 6 photons absorbed per grain On the other hand maximum contrast occurs at $D \approx 1\ 4$ where on the average 3 6 photons are absorbed per grain The detective quantum efficiency of the film i e the fraction of the photons actually contributing to the information content of the image drops from 41 per cent at maximum signal to-noise ratio to a mere 10 per cent at maximum contrast Receptor saturation does not manifest itself as mottle in the image—it is therefore easily overlooked The importance of adequate removal of secondary radiation is emphasised by these results

ACKNOWLEDGEMENT

This investigation was supported by a grant from the Swedish Medical Research Council (project No B79 291 5360)

REFERENCES

DAINTY J C and SHAW R Image science principles analysis and evaluation of photographic type imaging processes Academic Press London New York San Francisco 1974

FRIESER H Photographic information recording The Focal Press London New York 1975

GRAY J E TAYLOR K W and HOBBS B B Detection accuracy in chest radiography Amer J Roentgenol 131 (1978) 247

JONES R C Quantum efficiency of detectors for visible and infrared radiation *In* Advances in electronics and electron physics Vol 11 p 87 Edited by L Marton Academic Press New York London 1959

MEES C E K and JAMES T H (Editors) The theory of the photographic process 3rd ed The Macmillan Co New York London 1966

MORGAN R H BATES L M GOPALARAO U V and MARINARO A The frequency response characteristic of x ray films and screens Amer J Roentgenol 9? (1964) 426

MOTZ J W and DANOS M Image information content and patient exposure Med Phys 5 (1978) 8

REICHMANN S and STRID K G Adverse effects of stationary grids Acta radiol Diagnosis 17 (1976) 741

— ÅSTRAND K and LUNDIN L (a) Choice of screens in high speed angiography Acta radiol Diagnosis 0 (1979) 977

— — and STRID K G (b) *Relevance of radiographic* resolution capacity Acta radiol Diagnosis 20 (1979) 673

— HELANDER C G and SELIN K Medichrome film as an alternative to silver free recording systems Acta radiol Diagnosis 19 (1978) 513

ROSE A A unified approach to the performance of photographic film television pickup tubes and the human eye J Soc Motion Picture Eng 47 (19-6) 273

SELIN K and REICHMANN S High density failure of radiographic films Acta radiol Diagnosis 18 (1977) 95

— — (a) Visual evaluation of microscopic mottle Acta radiol Diagnosis 20 (1979) 551

— — (b) Influence of microscopic mottle on the definition of fine image details Acta radiol Diagnosis 20 (1979) 815

STRID K G Analysis of secondary screening with special reference to grids for abdominal radiography Acta radiol (1976) Suppl 351

— Significance of quantum fluctuations in roentgen imaging Acta radiol Oncology 19 (1980) 129

STURM R E and MORGAN R H Screen intensification systems and their limitations Amer J Roentgenol 62 (1949) 617

TER POGOSSIAN M M The physical aspects of diagnostic radiology Hoeber Medical Division Harper & Row New York Evanston London 1967

FROM THE DEPARTMENTS OF DIAGNOSTIC RADIOLOGY MUNICIPAL HOSPITAL OF AARHUS AND RHEUMATOLOGY UNIVERSITY OF AARHUS DK 8000 AARHUS DENMARK

RELATIONSHIP BETWEEN RADIOLOGIC AND CLINICAL FINDINGS IN RHEUMATOID ARTHRITIS

A DE CARVALHO and H GRAUDAL

In population surveys some discordance has been found between clinical radiologic and serologic evidence of rheumatoid arthritis (KELLGREN 1968) The relationship between radiologic and clinical criteria of rheumatoid arthritis has been discussed recently when applied to epidemiologic investigation (HENRARD 1979) It is also known that clinical manifestations of rheumatoid arthritis may be present without radiologic evidence (FLETCHER & ROWLEY 1952 ISEMEIN & FOURNIER 1964) This must be assumed always to be the case for a shorter or longer period at the beginning of the disease Radiologic involvement may also occur in the absence of local clinical manifestations (DE SEZE et coll 1964 DE HAAS et coll 1974 BROOK et coll 1977) but it is not known whether radiologic and clinical findings are concordant or not in different joints or to which extent

The present investigation was undertaken to elucidate the relationship between radiologic and clinical findings in the joints of patients with rheumatoid arthritis and the implications of this relationship The distribution of radiologic abnormalities in the same group of patients has been described previously (DE CARVALHO et coll 1980 a)

Material and Methods

The material consisted of the same 188 patients with definite or classical rheumatoid arthritis (ROPES et coll 1958) described previously (DE CARVALHO et coll 1980 a b DE CARVALHO & GRAUDAL 1980 a b) All the patients who had been hospitalized in the Rheumatism Research Unit and afterwards adequately followed for at least 3 years from 1965 onwards were included The maximum follow up period was 12 years the average being 6 2 years A full clinical radiologic and serologic assessment was performed at the beginning and the end of the observation period and on several occasions in between Most patients were given non steroid anti inflammatory drugs Many patients were treated with gold or chloroquine A few patients who were on long term corticosteroid treatment when first seen continued this therapy but treatment with corticosteroids cyclophosphamide or penicillamine was initiated only in exceptional cases It was not intended to relate the findings to the type of therapy

All clinical assessments during the observation period were performed by the same rheumatologist (H G) The following findings were recorded on special assessment forms synovial effusion slight or advanced soft tissue joint swelling (not recorded for the shoulder and hips) periarticular swelling bony enlargement crepitation tenderness on palpation pain on motion range of motion and subluxation In the present comparison with the radiologic findings tenderness and pain on motion were for the sake of clarity recorded under one heading and so were slight and advanced swelling any degree of limitation of movement contracture and subluxation Swelling was noted only when it was considered to be valid as an American Rheumatism Association (ARA) criterion (ROPES et coll) An attempt to decide the intra-observer variation of the clinical findings was considered to be illusory

Submitted for publication 3 March 1980

since it would require two examinations at a short interval the second of which might involve bias by the examiner s remembrance of the first find ings

In the assessments radiography of most limb joints was performed at an interval of less than one month from the clinical examination Intervening films of single joints were not included in the present analysis The relevant films were evaluated blindly by the same radiologist (A C) and classified accord ing to the system of LARSEN et coll (1977) as fol lows

Grade 0	normal findings
Grade 1	slight abnormality including periarticular soft tissue swelling juxta articular decalcification and slight narrowing of the joint space
Grade 2	early but definite abnormality bone erosion and most often dis tinct narrowing of the joint space in weight bearing joints a dis tinct narrowing of the joint space without bone erosion was also classified as grade 2
Grade 3 4 and 5	medium destructive severely de structive and mutilating changes respectively These grades were recorded together in the present analysis (Figure)

The inter and intra observer variation has previ ously been discussed in detail by LARSEN (1973 1974) and LARSEN et coll (1979) An evaluation of the discriminative power of the scoring system is reported separately (DE CARVALHO 1981)

It has previously been found (DE CARVALHO et coll 1980 a) that the limb joints can be arranged into 20 groups each with a uniform progression at radiography The relationship between radiologic and clinical findings was analysed for 13 of these 20 groups MCP 1 and IP of the thumb were combined with MCP and DIP 2 to 5 of the fingers respectively making a total of 11 groups

Abbreviations used MCP=metacarpo phalangeal joints PIP=proximal interphalangeal joints DIP=distal interphalangeal joints MTP=metatarso-phalangeal joints IP=interphalangeal joint



Joint involvement of varying degree MCP 4 = grade ? MCP5 grade 3 MCP 3 = grade 4

Results

The relationship between the degree of radiologic joint involvement and limitation of joint motion appears in Table 1 For all the joint groups examined a connection was found between the radiologic grade and the percentage of joints with limitation of motion which increased with radiologic progression

In grades 0 and 1 limitation of motion occurred particularly often in the MTP 2 to 5 This was generally a slight limitation or subluxation Limitation of motion also occurred frequently in the shoulders and PIP of the fingers but was rare in the hips knees and MCP

In grades 3+ limitation of motion was found in 76 to 93 per cent of the joints except the MCP the DIP of the fingers and the MTP 1

The motion of the PIP of the fingers was often limited both in the early and the advanced radiologic grades whereas normal motion was fairly often maintained in the MCP and the DIP of the fingers

The relationship between the grade of radiologic joint involvement and joint inflammation as evi denced by swelling or tenderness appears in Table 2 In this table the joint groups are arranged accord ing to the frequency of grade 2+ radiologic involve ment after one year of disease (DE CARVALHO et coll 1980 a)

In grades 0 and 1 swelling occurred in 25 per cent of the wrists and with decreasing frequency in the knees elbows PIP of the fingers MCP and ankles Swollen MTP and DIP of the fingers were rare However the absolute numbers of swollen PIP and

Table 1

…centage of joints with limitation of motion related to the …iologic grading. The percentages were calculated from the …al number of joints that were classified in the grade or grades in question

…nt group	Radiologic grading 0–1	2	3+	Total number of joints investigated clinically and radiologically
…oulder	26	47	90	1 077
…bow	15	46	93	981
…ist	19	46	87	1 176
…CP 1–5	5	12	49	5 754
…P 2–5 (fingers)	25	56	88	4 [illegible]88
…P 1–5 (fingers)	8	17	41	5 850
…p	3	28	83	1 070
…ee	6	23	76	1 019
…kle	15	41	77	1 073
…TP 2–5	40	52	80	4 297
…TP 1	11	30	61	1 049

Table 2

Percentage of joints with articular swelling and with tenderness only related to radiologic grades. The percentages were calculated from the total number of joints that were classified in the grade or grades in question. The joint groups are arranged according to the frequency of grade 2+ radiologic involvement after one year of disease

	Swelling			Tenderness		
Radiologic grading	0–1	2	3+	0–1	2	3+
Joint group						
Wrist	25	32	24	17	17	14
MCP 1–5	9	20	27	0 7	1	2
MTP 2–5	1 5	1 6	0 2	3	4	3
Shoulder	–	–	–	21	31	40
Elbow	13	37	55	1	1	7
Fingers PIP 2–5	12	21	23	0 6	1	2 5
Ankle	9	22	21	5	5	6
MTP 1	0 8	1 2	1	0 2	0 6	0
Knee	17	48	53	4	4	15
Hip	–	–	–	1	9	41
Fingers DIP 1–5	2	5	7	0 3	0 6	0 6

…ICP respectively were 5 3 and 3 8 times that of …wollen wrists

The percentage of swollen wrists remained fairly …onstant with progression to the grades 2 and 3+ In …ome joints the frequency of swelling increased …hen the disease had progressed from grades 0 and 1 … grade 2 but no further increase was associated …ith the progression to grade 3+ This was true of …ll the finger joints and the ankles Regarding the …houlders elbows hips and knees the frequency of …welling or tenderness increased with the progres…ion throughout the grades as did that of limitation …of motion In the MTP swelling and tenderness …emained rare throughout all radiologic grades

Tenderness occurred together with swelling in more than two thirds of the swollen wrists and in about half of other swollen joints Tenderness with out swelling was relatively rare except in the wrists and knees and in the shoulders and hips where the presence of swelling could not be evaluated

Discussion

The clinical findings recorded should not be regarded only as an expression of the natural course of the disease but may have been modified and mitigated by the treatment The radiologic abnormalities in rheumatoid arthritis reflect bone and cartilage destruction and may progress or become stationary but are mainly irreversible although what is regarded as healing phenomena do occur It is possible that remissions during treatment and spontaneous remissions may be followed by a cessation of the radiologic progression However no type of treatment has been proved to influence the course and progression of rheumatoid arthritis over many years Thus the radiologic progression can at the present time be considered to reflect the natural history of the disease

Transient limitation of passive motion may have several causes among which are intra articular effusion and synovitis Permanent limitation of motion may also be due to other intra and extra articular causes including fibrosis destruction of articular surfaces subluxation tightening of articular capsules and contractures of extra articular tissues It seems probable that the limitation of motion found in the absence of definite radiologic abnormalities is mainly due to synovitis Thus in MTP shoulders and hips limitation of motion would seem to be a principal physical indication of inflammation in early rheumatoid arthritis As for the shoulders elbows and ankles in grades 0 and 1 there was good agreement between limitation of motion and other signs of inflammation As for PIP DIP and particularly MTP limitation of motion was a much more sensitive physical indication of early involvement than were the conventional indications of inflammation

i e swelling and tenderness It is suggested that small amounts of pannus may have been present in many of these small joints even though no severe inflammatory exudation or tenderness was established This would be a prerequisite for the high frequency of erosions found after one year of disease particularly in MTP but also in PIP (DE CARVALHO et coll 1980 a) After one year of disease grade 3+ involvement occurred more often in MTP than in any other joint In contrast to this in grades 0 and 1 limitation of motion occurred less frequently in the wrist MCP and the knee than did swelling and tenderness and MCP unlike PIP preserved an almost astonishing mobility through the radiologic progression The reasons may be sought in the anatomy and the function of these joints but are not clear

The increasing frequency of limitation of motion in all joints together with radiologic progression suggests that in late rheumatoid arthritis the limitation of joint motion is mainly irreversible As for the shoulder McNAIR et coll (1969) reported similar observations

Joint swelling is the principal clinical indication of arthritis to which has been attributed the diagnostic importance of no less than three ARA criteria (ROPES et coll) Joint swelling is a generally reversible although often long standing feature of the individual joints in rheumatoid arthritis Remission may occur spontaneously or due to treatment with corticosteroids or with so called remittive drugs like gold compounds

Joint tenderness is another indication of local arthritic activity but still more fluctuating and susceptible to many influences including non steroid anti inflammatory drugs which may be the reason why definitely swollen joints are not always found to be tender Tenderness at clinical examination is not always a sensitive criterion since like swelling it is a relatively rare finding in MTP notwithstanding the fact that tenderness of the forefoot during walking is a common complaint

The presence of physical changes in about 40 per cent of the wrists (swelling or tenderness) and MTP 2 to 5 (limitation of motion) at the radiologic grades 0 and 1 agrees with the fact that these joints were often radiologically involved sometimes severely after one year of disease The absence of physical findings in the majority of joints in the early stage grades 0 and 1 implies that these joints had not yet been overtly attacked by the rheumatoid disease However the low frequency of swelling or tenderness in MTP MCP and PIP as compared with a fairly high frequency of radiologic involvement after one year of disease suggests that in many of these small joints small amounts of pannus may have been present not detectable by conventional clinical methods This would be in keeping with the opinion (CURREY 1978) that erosions are caused by marginal pannus and that subcapsular synovial inflammation although more easily detected is less important in this respect

The general absence of a uniform association between radiologic abnormalities and joint swelling or tenderness is in accordance with the reversibility of joint inflammation The finding of 4 modes of association seem to be interesting (1) in MTP a constantly low frequency of swelling or tenderness (2) in the wrists a constantly high frequency throughout the radiologic stages (3) in the finger joints and ankles an increase of frequency from grades 0 and 1 to grade 2+ and (4) in the large joints an increasing frequency throughout the radiologic stages The existence of swelling and tenderness in grades 2 and particularly 3+ connotes either that the arthritic activity has been of long duration or that relapses have occurred Conversely the absence of disease activity in many joints in these grades indicates that remission has taken place In the large joints the tendency to remission was distinctly less than for the small finger joints It is remarkable that in some small joints remission had occurred in more than 70 per cent

When the 20 groups of peripheral joints were arranged according to the frequency of radiologic involvement after one year of disease (DE CARVALHO et coll 1980 a) it was found that the joint groups of the upper limbs were more often involved than those of the lower limbs This was found in spite of the fact that the definition of grade 2 involvement different for weight bearing and non weight bearing joints might contribute to veil the difference Thus weight bearing does not seem to be essential for the early development of bone erosions As for the clinical findings at the grades 0 and 1 no significant difference was found with regard to their frequency in upper and lower limbs During walking MTP are both loaded and extremely dorsiflexed but the movements of the other joints are rather small Contrary to this the joints of the upper limbs are often moved through their whole range during normal function This will confer stress to the joint margins

the regions where early bone erosions usually occur In rheumatoid arthritis the finger joints of females are somewhat more involved than those of males (DE CARVALHO et coll 1980 b) The idea that movement may contribute to the development of erosions is also in agreement with this observation because in the work of males the power grip is often used whereas the traditional female occupations require movement more than power

It is a common opinion that the wrist MTP MCP and PIP of the fingers are the joints most often and most typically involved in rheumatoid arthritis (LARSEN 1976) Radiologically this was confirmed as regards the wrist and MCP Proportionally early involvement of the shoulder and the elbow was just as common as that of MTP and PIP of the fingers However the total number of MCP MTP and PIP involved was much higher because a much larger number of these joints were examined As regards the clinical finding of articular swelling single MCP PIP and particularly MTP were by far not so often involved as might have been expected But again the total number of PIP and MCP that were involved early was very high It seems that the involvement of some MCP PIP of the fingers or MTP both clinical and radiologic which is found early in any patients with rheumatoid arthritis as well as the frequent bilateral involvement of some of these joints may be explained statistically In each patient these joints constitute 28 of 50 joints which were evaluated radiologically and clinically in the present series

SUMMARY

A series of 188 patients with rheumatoid arthritis was followed up for 3 to 12 years An association was found between radiologic progression and limitation of motion for all the joints Remission of the inflammation occurred more often in the small joints Early radiologic involvement was most frequent in the upper limb joints and metatarso phalangeal joints Clinically no significant differences existed between upper and lower limbs in the early stages The single metatarso-phalangeal metacarpophalangeal and proximal interphalangeal joints of the fingers were not more often involved radiologically or clinically than many other joints Four different types of relationship between radiologic progression on one hand and articular swelling and tenderness on the other were observed

ACKNOWLEDGEMENT

The authors wish to express their gratitude to Anders Holst Andersen and Bent Jørgensen advisory statisticians for invaluable assistance This investigation has been supported by The Danish Medical Research Council and the Ferd and Ellen Hindsgaul s Foundation

REFERENCES

BROOK A FLEMING A and CORBETT M Relationship of radiological change to clinical outcome in rheumatoid arthritis Ann rheum Dis 36 (1977) 274

CARVALHO A DE Discriminative power of Larsen s grading system for assessing the course of rheumatoid arthritis To be published in Acta radiol Diagnosis 22 (1981)

— and GRAUDAL H (a) Sacroiliac joint involvement in classical or definite rheumatoid arthritis Acta radiol Diagnosis 21 (1980) 417

— — (b) Radiographic progression of rheumatoid arthritis related to some clinical and laboratory parameters Acta radiol Diagnosis 21 (1980) 551

— — and JØRGENSEN B (a) Radiologic evaluation of the progression of rheumatoid arthritis Acta radiol Diagnosis 21 (1980) 115

— — — (b) Evaluation of the progression of rheumatoid arthritis Significance of age at onset and sex Acta radiol Diagnosis 21 (1980) 545

CURREY H L F Aetiology and pathogenesis of rheumatoid arthritis *In* Copeman s textbook of the rheumatic diseases Fifth edition p 261 Churchill Livingstone Edinburgh 1978

DE HAAS W H D DE BOER W GRIFFIOEN F and OOSTEN ELST P Rheumatoid arthritis of the robust reaction type Ann rheum Dis 33 (1974) 81

DE SEZE S DEBEYRE N DJIAN A and MANUEL R The elbow joint *In* Proceedings of the International Symposium on the Radiological Aspects of Rheumatoid Arthritis p 115 Excerpta Medica Amsterdam 1964

FLETCHER D E and ROWLEY K A The radiological features of rheumatoid arthritis Brit J Radiol 25 (1952) 282

HENRARD J C Do radiological and clinical criteria of rheumatoid arthritis correspond with each other? *In* Laboratory tests in rheumatic diseases p 51 MTP Press Limited Lancaster 1979

ISEMEIN L and FOURNIER A M The foot *In* Procedings of the International Symposium on the Radiological Aspects of Rheumatoid Arthritis p 83 Excerpta Medica Amsterdam 1964

KELLGREN J H Clinical rheumatoid arthritis rheumatoid factor and erosive arthritis A critical examination of the inter relationship *In* Population studies of the rheumatic diseases p 151 Excerpta Medica Amsterdam 1968

LARSEN A Radiological grading of rheumatoid arthritis An interobserver study Scand J Rheum 2 (1973) 136

— A radiological method for grading the severity of rheumatoid arthritis Thesis Helsinki 1974

— The value of individual joints for radiologic assessment of rheumatoid arthritis Scand J Rheum 5 (1976) 119

— DALE K and EEK M Radiographic evaluation of rheumatoid arthritis and related conditions by standard reference films Acta radiol Diagnosis 18 (1977) 481
— EDGREN J HARJU E LAASONEN L and REITAMO T Interobserver variation in the evaluation of radiologic changes of rheumatoid arthritis Scand J Rheum 8 (1979) 109
MCNAIR M M BOYLE J A WATSON BUCHANAN W and DAVIDSON J K A clinical and radiological study of rheumatoid arthritis with a note on the findings in osteoarthrosis I The shoulder joint Clin Radiol 0 (1969) 269
ROPES M W BENNET G A COBB S JACOX R and JESSAR R A 1958 revision of diagnostic criteria for rheumatoid arthritis Bull rheum Dis 9 (1958) 157

FROM THE DEPARTMENT OF DIAGNOSTIC RADIOLOGY AND MEDICINE AARHUS KOMMUNEHOSPITAL DK 8000 AARHUS DENMARK

RENAL OSTEODYSTROPHY IN NON-DIALYSED PATIENTS WITH CHRONIC RENAL FAILURE

J ANDRESEN and H E NIELSEN

Skeletal abnormalities in renal osteodystrophy clude osteomalacia osteosclerosis metastatic lcification osteopenia and osteitis fibrosis cys ca Bone loss is the result of an imbalance between one resorption and bone formation the former ceeding the latter and at radiography appearing as ubperiosteal intracortical or endosteal resorption he subperiosteal resorption is nearly pathogno onic for hyperparathyroidism (MEEMA et coll 978)

The radiologically detectable bony manifestations chronic renal disease are well-documented KATZ et coll 1969) Though it is known that radio raphy frequently fails to demonstrate any signifi ant alteration of the mineral content in the morpho ogic structure of the skeleton radiologically lemonstrable bone disease develops in almost every patient with chronic renal failure (GRIFFITHS et coll 1977)

The present report describes radiologic bone lesions and metacarpal bone mass in a series of non dialysed patients with chronic renal failure The findings were correlated with the degree of renal failure type of renal disease and with changes in mineral metabolism In another series of non dialysed patients radiologic bone lesions were analysed prospectively

Material and Methods

The series analysed retrospectively consisted of 92 non-dialysed patients (41 males 51 females) aged 14 to 69 years (mean 38 7) with chronic renal failure 33 had a creatinine clearance at 10 to 50 ml/min 35 a clearance at 5 to 10 ml/min and 24 a creatinine clearance below 5 ml/min Twenty two had chronic glomerulonephritis 6 chronic obstructive pyelone phritis 15 analgetic nephropathy 11 congenital renal disease 7 polycystic kidney disease 15 chronic interstitial nephropathy non analgesic induced 5 nephrosclerosis 2 medullary kidney disease 1 diabetic nephropathy 1 nephrocalcinosis 1 mye loma kidney 1 renal tubular acidosis and in 5 cases the nature of the disease was unknown The pro spective series consisted of 20 patients (9 males 11 females) aged 22 to 56 years (mean 40 9) with chronic renal disease and were examined before and during a period of 1 to 8 years (mean 3 5 years)

Radiography of the skeleton excluding the ribs and the shaft of the long bones of the extremities was evaluated blindly with regard to rarefaction (osteoporosis) of the spine and subperiosteal ero sions The presence and extent of calcifications in soft tissue and vessels were also noted The cortical area of the second left metacarpal bone (D −d)/ D was used as an index of bone mass measuring the outer diameter to the bone width (D) and the dia meter of the medullary space (d) of the cortex at the midpoint of the shaft at right angles to the long axis of the base as described by DEQUEKER (1976) The results were expressed in absolute values and as per cent of reference values from patients of similar

Submitted for publication 23 August 1979

Table 1

Radiologic bone lesions and metacarpal bone mass in 9? non-dialysed patients with chronic renal failure Percentage in parentheses

Creatinine clearance (ml/min)	No of cases	Subperiosteal erosions	Rarefaction of the spine	Soft tissue calcifications	(D²−d²)/D (per cent)
<5	24 (26)	8 (31)	8 (31)	8 (31)	93 6
5–10	35 (38)	8 (?3)	18 (51)	14 (40)	90 8
11–50	33 (36)	4 (1?)	14 (4?)	8 (?4)	9? 8
Total	92	20 (22)	40 (43)	30 (3?)	9? ?

Table 2

Radiologic bone lesions in 20 non dialysed patients with chronic renal failure Prospective analysis Increased ↑ decreased ↓ unchanged →

No of cases	Rarefaction of spine				Subperiosteal erosions				Soft tissue calcifications			
	↑	↓	→	Total	↑	↓	→	Total	↑	↓	→	Total
9 men	1	0	3	4	1	0	1	2	4	1	1	6
11 women	3	1	5	9	3	0	0	3	3	0	1	4
Total	4	1	8	13	4	0	1	5	7	1	?	10

ge and sex given by GARN et coll (1971) The intra observer variation coefficient on (D²−d²)/D was 1 6 per cent and the inter-observer variation coefficient 2 4 per cent

Serum concentration of calcium phosphate and alkaline phosphatase were measured by auto analyzer methods Serum calcium was corrected for individual variation in serum protein concentration and calculated as the calcium concentration corresponding to a protein level of 7 g/100 ml serum (PEDERSEN 1973) Creatinine clearance was measured using 24 h urine collection

Results

At the beginning of the investigation 40 of 92 patients (43%) had a slight degree of rarefaction of the spine 20 (22%) had subperiosteal erosions and 30 patients (32%) soft tissue calcifications in 20 of these in the vessels The metacarpal bone mass was subnormal compared with the normal values given by GARN et coll

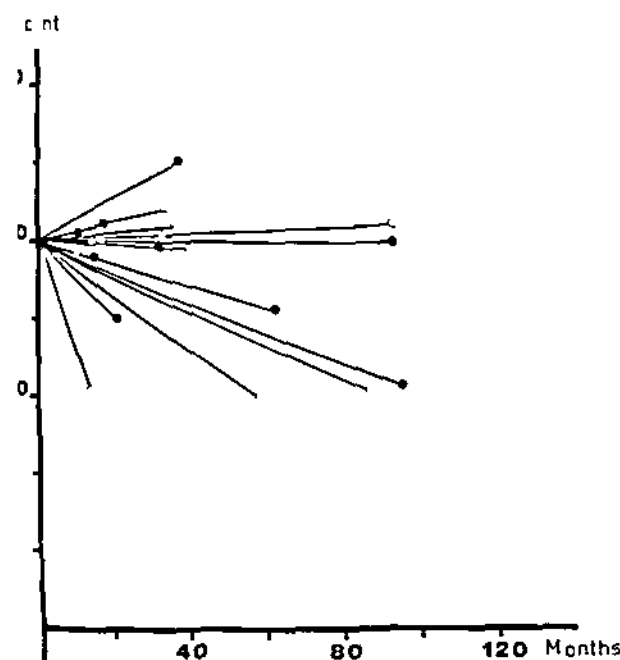
An increase in the frequency ($p=0.05$ χ^2 test) and in the degree of subperiosteal erosions could be observed with decreasing renal function (Table 1)

No difference was found in the incidence and degree of rarefaction of the spine or in soft tissue calcifications in patients with creatinine clearance of 10 to 50 ml/min as compared with patients with creatinine clearance below 5 ml/min

In patients with serum calcium within normal limits the frequency of soft tissue calcification was 40 per cent as compared with 24 per cent in patients with subnormal serum concentration No difference in the incidence and degree of subperiosteal erosions in rarefaction of the spine or in metacarpal bone mass existed between the two groups

The radiologic bone abnormalities and the metacarpal bone mass were unrelated to the serum concentrations of phosphate and alkaline phosphatase and to the kind of renal disease Furthermore the incidence and degree of subperiosteal erosions and rarefaction of the spine were unrelated to the sex as the subperiosteal erosions occurred in 9 men and in 11 women and rarefaction of the spine in 18 men and in 22 women On the other hand soft tissue calcifications occurred in 10 men and in 20 women

In the prospective series (Table 2) the incidence and degree of rarefaction of the spine increased Four patients developed radiologically detectabl



:tacarpal bone mass $(D^2-d^2)/D$ corrected for normal age nation in 0 non-dialysed patients with chronic renal failure ring a mean observation period of 3 5 years ● males O nales

:mineralization of the spine whereas the mineral ontent was unchanged in 8 patients and normalised one patient The frequency of subperiosteal ero ons increased from one to 5 of the 20 patients An icrease or new formation of soft tissue calcifica ons was noticed in 7 patients The metacarpal bone iass decreased in mean 2 per cent during the follow p period (per year 0 5% Figure)

Discussion

The findings at radiography of the skeleton were nalysed in relation to the degree of renal failure ype of renal disease and serum concentrations of calcium phosphorus A decrease in renal function vas associated with an increase in the frequency and legree of subperiosteal erosions whereas no rela ion could be demonstrated between these bone le sions and the serum concentrations of calcium phosphate and alkaline phosphatase or between the bone lesions and the type of renal disease The subperiosteal resorption is one of the most common skeletal abnormalities in patients with chronic renal failure (MEEMA et coll 1978) and nearly patho gnomonic for hyperparathyroidism (GENANT et coll 1975) In agreement with the results of HENDERSON et coll (1979) no relation could be demonstrated between the type of renal disease and the incidence and the degree of uremic bone disease

Osteoporosis in non-dialysed patients has been considered uncommon (STANBURY 1969) In the present series an incidence of 45 per cent of rare faction of the spine was found as compared with an incidence of only 12 per cent in the report by MEEMA et coll (1972) On the other hand they found a higher frequency of bone resorption (14%) and soft tissue calcification (59%)

In a prospective series with an observation period of mean 3 5 years an increase was observed in the incidence and the degree of subperiosteal erosions in rarefaction of the spine and in soft tissue calcifi cations and a decrease in metacarpal bone mass

MEEMA et coll demonstrated progression of bone resorption in 9 of 20 patients during an observation period of 23 4 months This progression was fre quently followed by spontaneous fractures In con trast to this finding none of the present patients developed spontaneous fractures during the ob servation period The decrease in metacarpal bone mass was lower (0 5% per year) than the 1 5 per cent per year observed in patients on chronic hemodialysis (ANDRESEN et coll 1980) However ANDRESEN et coll found that renal transplant patients who developed osteonecrosis or sponta neous fractures after transplantation had a higher frequency and severity of radiologic bone lesions (rarefaction of the spine subperiosteal erosions) before the time of transplantation as compared with renal transplant patients who did not develop such bone lesions (unpublished data)

Previous reports have given extremely variable incidence and degree of bone lesions in patients with chronic renal disease (MEEMA et coll 1972) This may largely be due to factors related to duration of the disease degree of renal insufficiency hemo dialysis and other kinds of treatment The present results indicate a relation between the severity of renal failure duration of renal disease and the inci dence and degree of radiologic bone lesions in non dialysed patients with chronic renal failure

SUMMARY

Radiologic bone lesions in 92 non-dialysed patients with chronic renal failure are described The bone disease in creased with the severity of renal failure In a prospective series of 20 patients progression of osteodystrophy and decrease in metacarpal bone mass were demonstrated

REFERENCES

ANDRESEN J NIELSEN H E and JOHANNESEN A Renal osteodystrophy Effect of chronic hemodialysis and 1α hydroxy vitamin D_3 on bone lesions and metacarpal bone mass Acta radiol Diagnosis 21 (1980) 541

DEQUEKER J Quantitative radiology Radiogrammetry of cortical bone Brit J Radiol 49 (1976) 912

GARN S M POZNANSKI A K and NAGY J M Bone measurement in the differential diagnosis of osteo penia and osteoporosis Radiology 100 (1971) 509

GENANT H K KOZIN F and BEBERMAN G The reflex sympathetic dystrophy syndrome Radiology 117 (1975) 21

GRIFFITHS H J ZIMMERMAN R E LAZARUS M LOWRIE E GOTTLIEB M M PHILLIPS E and POMERANTZ K The long term follow up of 195 pa tients with renal failure A preliminary report Radiology 122 (1977) 643

HENDERSON R G RUSSELL R G G EARNSHAW M J LEDINGHAM J G G OLIVER D O and WOODS C G Loss of metacarpal and iliac bone in chronic renal failure Influence of haemodialysis parathyroid activity type of renal disease physical activity and heparin consumption Clin Sci 56 (1979) 317

KATZ A I HAMPERS C L and MERRILL J P Sec ondary hyper parathyroidism and renal osteo- dystrophy in chronic renal failure Medicine 48 (1969) 333

MEEMA H E OREOPOULOS D G and MEEMA S A roentgenologic study of cortical bone resorption in chronic renal failure Radiology 126 (1978) 67

— RABINOVICH S MEEMA S LLOYD G J and OREO POULOS D G Improved radiological diagnosis of azotemic osteodystrophy Radiology 102 (1972) 1

PEDERSEN K O Calcium in human serum Biochemical and clinical aspects Thesis Aarhus 1973

STANBURY S W Azotaemic osteodystrophy and the problem of the dialyzed patient J Bone Jt Surg 51B (1969) 576

FROM THE DEPARTMENTS OF DIAGNOSTIC RADIOLOGY (DIRECTOR H LODIN) AND RADIATION PHYSICS (DIRECTOR J CEDERLUND) AKADEMISKA SJUKHUSET S 750 14 UPPSALA SWEDEN

NOISE AND NOISE TEXTURE IN CT IMAGES BEFORE AND AFTER POST PROCESSING

A HEMMINGSSON B JUNG and C YTTERBERGH

The properties of the computed tomographic (CT) image are the result of a compromise between partially conflicting objectives such as high spatial resolution low statistical noise and good perceptibility by the eye brain system at a low absorbed radiation dose to the patient It cannot be expected that the standard compromise within the limits settled by the manufacturer and selected by the operator will necessarily yield the best solution in all clinical situations and the means of changing the point of operation in retrospect are limited However by image processing techniques spatial resolution can be traded for noise reduction and vice versa

Image filtering does not in itself alter the actual information content of the image but may change the ability of the eye brain system to evaluate the image correctly It is also conceivable that appropriate image processing may be a good initial stage in automatic pattern recognition Such procedures might be of interest for organ delineation and computed dose planning in radiation therapy

Material and Techniques

An Ohio-Nuclear Delta 50 FS with associated software was employed

The calculations were carried out on PDP 11/10 11/35 and 11/40 computers run under RT 11 whereas the scanner computer (PDP 11/34) was run under DOS

Three phantoms were used two cylindrical homogeneous water phantoms with diameters of 23 and 35 cm respectively and one cylindrical liquid phantom diameter 20 cm with spheres of acryl nitrit butadiene styrene (1 07 g/cm³) in the scanning plane with diameters of 5 7 5 10 15 20 and 25 mm These phantoms are referred to as the two homogeneous phantoms and the inhomogeneous one respectively Water glucose solutions of various concentrations were used for varying the attenuation ratio between the liquid and the spheres in the inhomogeneous phantom (HEMMINGSSON et coll to be published)

Filters The program package delivered with the scanner contains two image filtering procedures FI and SP SMOOTH

FI is a simple 3×3 pixels averaging filter with the optional feature of discarding in the arithmetic mean pixels with Hounsfield numbers (Hn) outside a selectable band around the central element This possibility was abolished in the present experiments by setting the discrimination level at 1000 Hn thereby securing a stationary filter

SP SMOOTH is referred to in the scanner manual as Gaussian The filtering is stated to be performed in the spatial domain with a convolution matrix of 9×9 (maximum) pixels the elements of which are obtained by the expression $m = S2/(2^{r/R2}) + S4/(2^{r/R4})^4$ where S2 and S4 are strength parameters R2 and R4 cut off radii and r is

Submitted for publication 22 January 1980

Table 1

Matrix elements in some filters (normalized to 100 in the central element) Only one octant of the matrix is given

Filter				
FI	100	100	100	
	100	100		
	100			
SP SMOOTH	6	4	0	
(R2=R4=1	50	25		
S2=1	100			
S4=0)				
SP SMOOTH	4	4	4	
(R2=R4=2	21	18	11	4
S2=1	50	39	25	
S4=0)	82	68		
	100			
SP SMOOTH	50	50		
(R2=R4=4	67	67	58	50
S2=1	83	83	75	
S4=0)	100	92		
	100			

the distance from the central element In the experiments S4 was generally set equal to 0 which reduces parameter space due to normalisation constraints to one free parameter S2

Since the example of the filtering matrix presented in the scanner manual does not comply with the formula given the actual matrix elements were found by letting the computer associated with the scanner filter a faked image and print out the result on a Versatec plotter (Table 1) The faked image contained pixels corresponding to water everywhere except in one central element

Noise Images of the homogeneous phantoms were obtained for all combinations of the scanner parameters SPEED (time for complete scan) SLIT (slice thickness and detector aperture) and DIA (scan and reconstruction diameter) giving a total of 16 images The noise in these images was obtained with the RMSD (root mean square deviation) program provided with the scanner over a central circular region of interest The RMSD values were found to depend on the number of pixels in the region decreasing somewhat with increasing radius As a compromise a standard region of interest (ROI) containing 1 076 pixels was adopted

Four parameter combinations of particular clinical interest were selected for filtering (Table 4) For these the originals were filtered with the FI and SP SMOOTH procedures the latter with several values of R2 The RMSD values over the central circular region containing 1076 pixels were tabulated

Noise character and point spread function According to METZ & BECK (1973) the texture of the noise is reflected in the autocovariance matrix calculated over a flat region of the image TANAKA &

Table 2

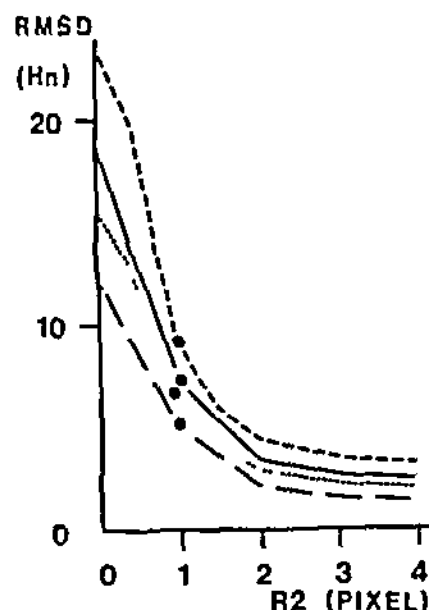
Mean attenuation and RMSD noise in images of a homogeneous water phantom with a diameter of 35 cm (Scanner settings SLIT 13.3 DIA 42 6 cm STANDARD SPEED=18 s)

Number of points in region of interest	Mean (Hn)	RMSD (Hn)
30 404	−2	12 1
9 774	−3	14 2
4 876	−3	15 2
1 076	−4	15 8
12	−3	16 0
52	−4	16 4

Table 3

Mean attenuation and RMSD noise in images of homogeneous water phantoms as functions of scanner settings and phantom diameter (SLIT is indicated as nominal slice thickness in mm and nominal beam width in mm) Standard speed = 18 s half speed 36 s Tube potential 140 kV anode current 35 mA

Slit	Speed	Mean (Hn)	RMSD (Hn)
Phantom Ø 35 cm			
Scan DIA 42 6 cm			
8 3	Standard	−8	23 4
8 5	Standard	−4	19 3
8 3	Half	−5	16 1
13 3	Standard	−4	15 8
8 5	Half	−2	13 0
13 5	Standard	−2	12 3
13 3	Half	−1	11 1
13 5	Half	−1	8 8
Phantom Ø 23 cm			
Scan DIA 25 2 cm			
8 3	Standard	8	16 4
8 5	Standard	9	13 1
13 3	Standard	−1	10 9
8 3	Half	7	10 6
13 5	Standard	7	9 2
8 5	Half	8	8 9
13 3	Half	4	7 1
13 5	Half	2	5 9



Noise (RMSD) after filtering with SP SMOOTH with $S4=0$ and $R2=R4$ as a function of R2 The noise after ; with FI is indicated by dots Slice thickness and beam 3 8 5 — 13 3 and 13 5 – – mm

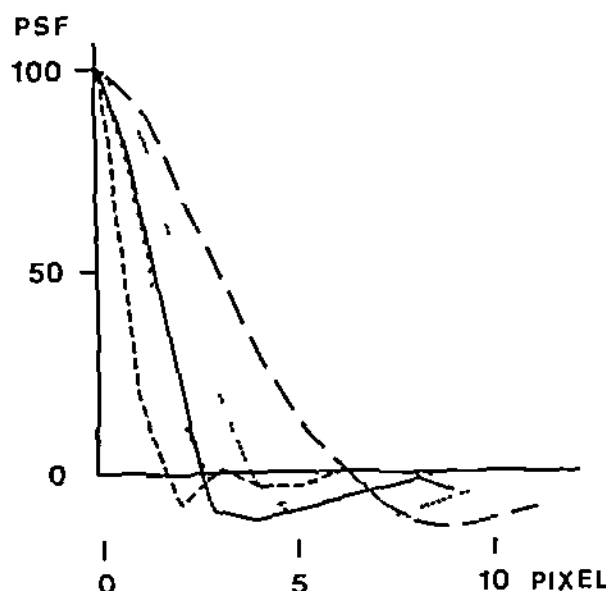


Fig 2 Point spread functions for unfiltered and filtered images The functions were derived from autocovariance matrices and therefore do not include physical effects original — FI SP SMOOTH ♦♦♦ R2=R4=1 R2=R4=2 – – – R2=R4=4

Table 4

RMSD noise in images of a homogeneous water phantom (diameter 35 cm) with various scanner settings (DIA 42 6 cm STANDARD SPEED)

Slit	RMSD (Hn)									
	Original	FI	SP SMOOTH (R4=R2 S4=0 S2=1)							
			R2=0 5	1 0	1 5	2 0	2 5	3 0	3 5	4 0
8 3	23 4	8 3	19 7	8 9	5 7	4 1		3 1		2 9
8 5	19 3	6 9		7 2		3 2		2 3		2 1
13 3	15 8	6 1	13 4	6 3	4 1	3 0	2 5	2 2	2 1	2 0
13 5	12 3	4 6		4 8		1 9		1 3		1 3

MA (1975) state that the autocovariance matrix gives the point spread function of the recon ction algorithm


e elements in the autocovariance matrix were ined from the expression COVAR (m n) = ERAGE ((EL(i j) – MEAN) × (EL(i–m j–n) – AN)) where EL(i j) is the matrix element with ments i and j MEAN is the mean of the matrix ents that are taken into account in the averaging edure and AVERAGE i the average (over i and a central circular region containing 1 076 pixels e image matrix

inimum detectable sphere Images of the in ogeneous phantom were recorded with the four scanner settings and displayed on the video monitor The minimum detectable sphere was noted from the *original images and also after filtering with FI* and SP SMOOTH

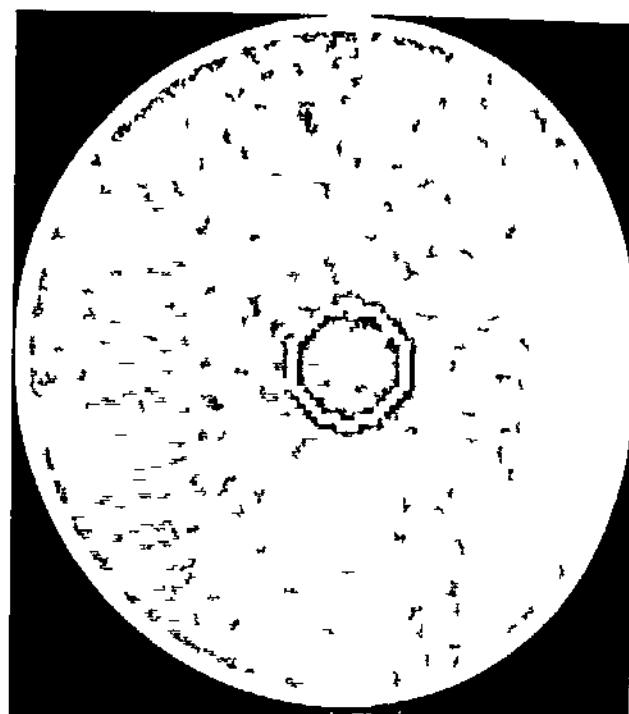
Results

The filter matrix elements for FI and some R2 R4 S2 and S4 combinations in SP SMOOTH are given in Table 1

Noise The results of the noise measurements for one scanner parameter combination as a function of the number of pixels in the region of interest are presented in Table 2 Similar results are given in




a



b

Fig 3 CT image of Ø 35 cm water phantom Reconstruction diameter 42 6 cm slice thickness 13 mm beam width 5 mm scanning time 18 s a) Original b) Processed with SP SMOOTH (R2=R4=4 S2=1 S4=0)



a



b

Fig 4 CT images of the inhomogeneous phantom a) Unfiltered Largest sphere barely visible b) After filtering with SP SMOOTH (R2=R4=4 S2=1 S4 0) The two largest spheres visible

Table 3 for the standard ROI (1 076 pixels) and various scanner parameter combinations The results of filtering with FI and SP SMOOTH appear in Table 4 and Figs 1 to 4 A considerable reduction of noise (by a factor of about 8) is evident The computing time for FI was about 15 s and those for SP SMOOTH with R2=1 R2=2 and R2=4 were 75 165 and 165 s respectively

Table 5

Autocovariance matrices for unfiltered images and images fil ltred with FI and SP SMOOTH with R2 =R4=1 R?=R4=? and R=R4=4 and S2=1 and S4=0 The data given are means for four noise originals Circular symmetry was assumed and only one octant of the matrices is given Elements less than 5 in absolute value were arbitrarily put as equal to 0 because of uncertainties in the calculations The central element is nor mali ed to 100*

Original	−7	−5	FI	6			
	20	−5		−8	−6		
	100			−11	−9	−6	
				−9	−10	−9	−7
				25	13	0	
				68	45		
				100			
SP SMOOTH	−5						
(R?=R4=1	−8	−6					
S?=1	−9	−8	−6				
S4=0)	−5	−6	−8	−7			
	18	9	−4				
	68	45					
	100						
SP SMOOTH	−7	−6	−6				
(R2=R4=2	−10	−9	−8				
S?=1	−13	−11	−9	−6			
S4=0)	−10	−10	−9	−6	−5		
	2	−2	−	−4			
	?7	?2	13	−			
	59	52	33				
	88	78					
	100						
SP SMOOTH	−9	−9	−8	−7	−5		
(R2=R4=4	−11	−11	−9	−8	−6		
S =1	−14	−13	−1	−9	−7		
S4=0)	−14	−14	−13	−1	−8	−5	
	−1?	−11	−10	−10	−8	−6	
	0	0	0	−5	−7	−7	−5
	11	9	6	0	0	−5	
	29	?6	0	14	6		
	48	46	37	?6			
	69	65	54				
	88	81					
	100						

oise character and point spread function The covariance was calculated for a matrix of 19×19 ls for the four scanner settings The central re of the matrix was quite similar in all cases and nearly circular symmetry This was also true for nents outside the central region but here the ad in the values was considerable on a relative s The result is given in Table 5 as a mean of the r modes under the assumption of circular sym ry Elements not significantly different from 0 are not given Identical calculations were also made for filtered versions of the originals The results were similar and are given in Table 5 for the same conditions as for the originals

Discussion and Conclusions

The noise in the original reconstruction is highly dependent on the scanner settings the more photons detected the lower the noise Considerable reduc tion of the noise level is achieved by the filtering programs delivered with the scanner Filter FI gives about the same result as SP SMOOTH with R2=1 while with R2 greater than 1 a further noise reduc tion is achieved The spatial correlation in the noise is low in the original images and increases after filtering This gives a coarser structure to the pro cessed images which may lead to a greater risk of erroneous evaluation if the observer is not aware of this effect

The point spread functions of the filtered images are widened as demonstrated by the autocovariance matrices This is probably not a serious problem for lesions with minor attenuation gradients provided they are not too small

The limited ability of the eye–brain system to de tect mean attenuation variations over extended re gions is evidenced by the fact that the minimum detectable sphere was smaller in filtered images than in the original ones

SUMMARY

Two homogeneous water phantoms were recorded un der various CT scanner settings and the reducing effect of various convolution filters on the noise level was evaluated The change in noise texture introduced by the filtering process was assessed for a limited range of scan ner settings by noise analysis of the autocovariance matrix before and after filtering The results indicate that reduc tion of noise expressed as RMSD by a factor of about 8 is possible with the filters available in the software package of the Ohio-Nuclear Delta 50 FS tomograph with some sacrifice in spatial resolution Results of pr liminary ex periments with an inhomogeneous phantom are in agree ment with this finding and indicate that fil ering allows smaller lesions to be detected

ACKNOWLEDGEMENT

The investigation was supported by grants from the Swedish Cancer Society

REFERENCES

HEMMINGSSON A JUNG B and YTTERBERGH C Perceptibility of experimental and clinical lesions in the CT image with and without image processing To be published in *Acta radiol Diagnosis*

METZ C E and BECK R N Quantitative effects of stationary linear image processing on noise and resolution of structure in radionuclide images J nucl Med 15 (1973) 164

TANAKA E and IINUMA T A Correction functions for optimising the reconstructed image in transverse section scan Phys in Med Biol 20 (1975) 789

BOOK REVIEWS

)RONARY ANGIOGRAPHY AND ANGINA PECTORIS Sympo ım of the European Society of Cardiology Hanover ermany Edited by P R Lichtlen Georg Thieme Verlag uttgart 1976

The first section of the volume is devoted to technical pects JOTTEN gives a review about equipment and wer supply an equipment now however replaced by new generation a fact reflecting the rapid technical velopment in the field of cardioangiography GUDDEN HOFMANN discuss the modulation transfer function and applicability for example in evaluating progress in age intensifiers

A number of authors report experiences with their own chniques of coronary angiography but no comparison tween different methods is attempted It is surprising read about the difficulties encountered by SONES in iding the most useful projections In his hospital 6000 tients are submitted to coronary angiography every year id one third have normal arteries The frequency of mplications is very low

Myocardial infarction and angina pectoris in patients ith normal coronary arteries and Prinzmetal angina also patients with normal arteries are discussed in the fol wing section Coronary spasm during angiography is viewed by LICHTLEN He claims that in accordance with ernoulli s pressure law the velocity of the blood flow is aximmaly increased in the part of the vessel narrowed y the spasm for maintenance of a normal flow This ssumption may be contested however—it is probably ore correct to conclude that the mean flow is reduced ı spite of an increased flow velocity in the constricted art KALTENBACH and associates report ST elevation uring physical exercise angiography revealed athero-clerosis of the descedning branch if the coronary artery rather uncommon phenomenon

MOCCETTI et coll deal with progression of coronary rtery disease assessed from cineangiography In 84 pa ents who were re submitted to coronary angiography fter an average interval of 19 2 months the coronary rtery disease had clearly progressed in about 50 per cent ı the other half no change had occurred They concluded hat the course of this disease is not a uniform one and hat at least two groups of patients can be distinguished ne with stepwise progressing disease periods of progres ion alternating with longer intervals of stability and one roup with rapid and continuous progress This conclu sion seems to be open to discussion however It may be rgued that their results are based upon data from the groups as a whole in which certain factors may have been overlooked e g the stage of the disease at which the initial examination was performed in the individual pa tients Thus in patients who are operated upon this is usually done at a late stage when the disease is progress ing less rapidly whereas in the non-operated patients the initial angiography was performed at an earlier more rapidly progressing stage of the disease—the repeat examination being performed later when they are at a stage requiring surgery

BRUSCHKE et coll discuss the prognosis of coronary artery disease on the basis of angiographic observations The survival rate was found to be considerably low then two or more branches of the coronary arteries are in volved

The third section deals with evaluation of the heart chambers at coronary artery disease Investigations requir ing highly sophisticated technical equipment for example for determination of changes in the diameters of the left ventricle are reported This is of scientific interest but has only minor significance in routine practice A group from Hammersmith Hospital London recommends that left evaluation of the left ventricle be performed during phys ical work when possible in order to better reveal scars and non functioning segments of the left ventricular wall The application of this procedure for postoperative evalua tion has not yet been reported In case that the patient is not able to carry out physical work the heart rate should be increased by pacing and the use of drugs

The fourth part of the volume deals with coronary angio-graphy and left ventricular angiography after surgery especially revascularization It has been claimed that fol lowing attachment of a bypass to a coronary artery the atherosclerosis of the part of the artery proximal to the anastomosis increases This opinion is criticized by AMIEL and associates Their findings indicate that this may be merely a question of flow competition when the contrast medium injected into the bypass does not reach the proxi mal part of the coronary artery this may be due to a counter flow in this artery giving the impression of an occlusion Between 1967 and 1973 bypass operations were performed in 6 375 patients at the Cleveland Clinic and the long term results are reported by SONES The mortality from bypass surgery has decreased to 1 5 per cent If 75 per cent of the grafts are still open and functioning at the 5 year level this should be considered a good result The Cleveland Clinic has the most extensive experience of by pass surgery in the world but follow up angiography is not carried out to a desirable extent which is to be re gretted

Left ventricular cardioangiography after surgery is discussed by several authors BOURASSA et coll found that an ejection fraction below 0 50 was associated with a much higher postoperative mortality than one exceeding this value The ejection fraction was not significantly increased postoperatively in patients with patent grafts They con clude that myocardial revascularization is probably not indicated in patients in whom the myocardium is severely injured

SCHÖNBECK reports an increase in left ventricular func tion including the ejection fraction after bypass surgery with patent grafts and NEUHAUS et coll arrived at similar results

A session was devoted to special techniques in relation to coronary angiography A morphometric analysis of the

coronary arteries is presented by RAFFLENBEUL and associates One interesting observation was that post stenotic dilatation of the left ventricular artery is usually found only in constrictions of less than 60 per cent Thus post stenotic dilatation should indicate an obstruction of lesser severity However in general the evaluation of coronary morphology on angiography is inadequate and often leads to an overestimation of obstruction The equipment used allowed an accurate measurement of the arterial diameters Such equipment is not generally available in clinical practice and there is much subjective influence in the evaluation of coronary artery stenosis

RUTISHAUSER and associates consider that only a determination of the regional flow in relation to local wall motion will provide an adequate understanding of the true character of coronary heart disease

Comparisons of left ventricular dimensions obtained at angiography and echo-cardiography are also presented The results are not well correlated and this is also true for comparisons between measurements made in two dimensions and those made in one

The volume ends with a report including considerations on collateral arterial formation and new principles of drug treatment the influence of calcium upon cardiac function being one of the topics

Thus this volume offers an excellent review of the present state of the research and therapy of angina pectoris

Uno Erikson

ROENTGEN VIDEO-TECHNIQUES FOR DYNAMIC STUDIES OF STRUCTURE AND FUNCTION OF THE HEART AND CIRCULATION Second International Workshop Conference Edited by P H Heintzen and J H Bursch 273 figures 17 tables Georg Thieme Verlag Stuttgart 1978

The proceedings of this second Symposium organized by Professor P H Heintzen in Kiel include 80 contributors and give a comprehensive view of the development of videometry and videodensitometry

A new technique for the measurement of total and regional blood flow in organs is described by Erikson et coll Their technique permits both relative and absolute measurements of total and regional blood flow in organs with good spatial resolution and without need for measuring vessel diameters

Videometry is still used for measurements of cardiac volume in spite of the well known difficulties encountered in the geometrical calculations Automatic videometric determination of the outlines of cardiac chambers facilitates the measurement

Videodensitometric determination of volumes of the cardiac chamber is described in several reports With this technique no assumption of regular geometrical shape of the cardiac chambers is needed and irregularly shaped ventricles can be measured accurately In the future videodensitometry will probably become the standard procedure for measuring the volume of cardiac chambers calculating ejection fractions and also as reported in this symposium for the estimation of insufficiency of cardiac valves

One section of the symposium dominated by E H Wood and his collaborators deals with the theoretical and practical solutions of the problem of obtaining high temporal resolution trans axial sections of the heart in living subjects They propose and have under construction a general purpose scanner with 28 separate radiation sources The technical development in this field progresses rapidly now a little over two years after the symposium new types of roentgen tubes are under construction permitting more simple and much less expensive solutions

The symposium also illustrates the importance of the development of inexpensive micro-computers and memories for the videodensitometric technique The development goes in the direction of modularly built videodensitometric instruments for specific and well-defined examinations with micro-computers providing the necessary calculating capacity

Another question is whether all information should be digitalized The experience of the Uppsala group seems to indicate that the inexpensive analogue technique can be used for many purposes

In summary the book gives a comprehensive and complete survey of the present state of videodensitometry It is recommended to everyone interested in the development of physiologic and quantitative radiology

Lars Bjork

RÖNTGENOLOGISCHE DIFFERENTIALDIAGNOSTIK Band II Erkrankungen der Bauchorgane Fifth edition By W Teschendorf and W Wenz 638 pages with 734 illustrations and 43 tables Georg Thieme Verlag Stuttgart 19 8

The fourth edition of this in Germany well established work is twelve years old Since then the development of diagnostic radiology has proceeded rapidly and new techniques of angiography isotope examinations ultrasound and computer tomography have been introduced which has made this new edition necessary Since twelve co-authors participate in this edition the quality and style of the chapters differ but in general the editors have succeeded in giving the chapters a uniform shape

An introductory chapter on acute abdominal diseases is followed by 13 chapters on diseases of the different abdominal organs including a chapter on the operated stomach A further chapter deals with the retroperitoneal space and includes general considerations on the diagnosis of abdominal masses Each chapter is introduced by a short description of the examination methods which the author considers relevant for the specific organ A description of the normal roentgen anatomy is followed by the developmental anomalies and a discussion of pathologic processes

Relevant methods of operation developmental anomalies and morphologic changes are often schematically demonstrated in diagrams The majority of tables listing indications clinical symptoms and radiologic find

e instructive and valuable The illustrations are al ... tive and of high quality

chapters on the stomach and the bowel give an ... ent presentation of single and double-contrast ... examinations

he chapters on gallbladder and bile ducts th ... am ... is nomenclature for cholegraphy and cho ... is confusing Carcinoma of the head of the pancreas ... he list of contra indications for percutaneous tra... c cholangiography but is in the opinion of t e r ... r in fact one of the main indications

chapters on liver spleen and pancreas ... ed for a complete clearly and concisely ... of diseases examination methods and d ff ... e ... osis The percutaneous transhepatic punctur ... vein would seem to be more pertinent th ... bed splenoportal and transumbilical exam... ds

general the role of ultrasound and compute... s is not exhaustively treated A more exten... n especially in the chapters on the kidne... glands urinary bladder and retroperit... have been desirable

book can be recommended for postgra... and for clinical reference

Wolf ann Rei

ES SERIES DU CORPS HUMAIN ANATOMIE RADI... SCANNER. By J Gambarelli G Guennel L ... ot M Mattei et collaborateurs 290 pages 550 fig En coedition Masson et Springer Paris/Berlin 1977 195 F

s volume is an atlas on sectional anatomy of the ... n body as displayed by computer tomography (CT) ... introductory comments on the theory and practical ... gement of whole body CT scanning

head and upper neck regions are presented in 16 ... verse and 16 coronal sections the neck and male ... in 63 consecutive transverse sections with 10 addi... sections of the female pelvis Finally the arm and ... e represented by a few selected sections

ch section is displayed on two facing pages sized ... 24 cm×31 cm with a lay-out consistently used ... ghout the book one diagram indicating the level of ... ection one legend with French and Latin names of ... ered structures one conventional film of a specimen ... on and one CT image of a corresponding section ... two are of equal size 50 to 100 per cent larger than ... ommon CT images on Polaroid film one larger dia... of the conventional film provides extensive number ... ing of various anatomic structures in the section ... abelled diagrams use no less than 12 coded patterns ... ifferent types of tissue such as bone fat nerves ... ls organs etc In roughly half of the head and torso ... ons a colour reproduction of a corresponding speci... section has been inserted size as large as the dia... According to the authors colour displays have been ... lied primarily in anatomically complex difficult re... of the head and torso While the diagrams are made from and are thus identical with the specimen sections displayed as conventional films the colour sections as well as the CT images represent approximately corresponding sections

The concept of presentation is logical the net result is in part educational and easy of access However there is also cause for criticism. The conventional film display of the head sections is rather pointless as the sensitivity of this mode is so low as to exclude most of the anatomic detail of the brain It is a little surprising that the reproduced CT images do not offer much improvement On the other hand such is not the case with the body sections in conventional radiography which demonstrate topographic relationships in considerable detail

The CT images have been photographed from the screen of a TV monitor using a technique that enhances a disturbing line pattern sometimes with a deleterious effect on the image The overall impression of the CT images is that of suboptimum quality in contrast and resolution The numbering of structures on the CT images appears unnecessarily extensive as adequate labelling is provided in the diagrams

The poor quality of the CT images makes the reader feel that having the fraction of conventional body section films expanded at the expense of the CT reproductions would have been advantageous in the head more space could have been available for high quality CT images with the omission of conventional film sections Notwithstanding the valuable information contained in the anatomic specimen displays and the diagrams the drawbacks are serious in an atlas at such a high price

Ulf Bergvall

CLINICAL RADIOLOGY IN THE TROPICS By Peter Cockshott and Howard Middlemiss 2.2 pages Churchill Livingstone Edinburgh 1979 Price £17 –

All radiologists who have worked in the tropics have felt a great need for a modern textbook which could provide guidance on the many occasions when a radiologist from the industrialized countries experiences uncertainty in the face of entirely unfamiliar roentgen images The old bible of tropical radiology (Tropical Radiology 1961 edited by Howard Middlemiss) has long been out of print and only copies battered almo t to the point of extinction are now to be found at some of the larger departments of radiology in the tropics It is therefore an event of considerable importance that two of the world's most experienced tropical radiologists have now published a new modern textbook in this field

This new book differs from its predecessor in two important respects It includes not only tropical diseases but also conditions which previously were common everywhere but which still persist as considerable problems in developing countries in the tropics Among such conditions for instance are the more unusual forms of tuberculosis which are seldom or never encountered in countries with advanced health and medical services The hemoglobin abnormalities constitute another example of

conditions not intrinsically allied to the tropics but occurring predominantly in those regions

Another important difference compared with the old textbook of tropical radiology is the classification according to organs (previously according to diseases) In the reviewer s opinion the presentation of the information has benefited by this change the book having thereby become easier to use as a manual in the daily work

The book is not intended as a sophisticated encyclopedia for those wishing to carry out research in the field of tropical radiology It does not go into subtle details of interest mainly to scientists but on the other hand it is a high-class textbook for radiologists engaged in practical work in the tropics

It contains a large number of illustrations of surprisingly high quality considering the technical standard prevailing in the countries from which they were collected

This book must be regarded as an exceedingly important and valuable complement to all medical libraries in the tropics Nobody working with diagnostic radiology in those regions should fail to make use of it and it should also be indispensable at hospitals in industrialized countries handling patients with tropical diseases a clientele which is increasing steadily with the expansion of tourism and service in developing countries

Georg Fredrik Saltzman

CASE STUDIES IN ULTRASOUND By Royal J Bartrum Jr and Harte C Crow 435 pages W B Saunders Company Philadelphia London Toronto 1979 Price £14 95

Even though several good books on abdominal ultrasound examination are already available the present publication meets a demand and as the authors point out in the preface the book can be used for many purposes as a textbook an atlas of pathologic conditions a reference source or a means of self testing

The book consists of descriptions of separate cases It is not divided into subject areas as could be expected The collected material includes 176 cases concerned mainly with abdominal pathology including gynecology and obstetrics but dealing also with pathology of the thyroid testes and prostate All the cases are presented with proven pathologic diagnoses

The construction of the book makes it possible to use it for self testing Each case begins on a right hand page with a presentation of one or more selected scans followed by clinical data and specific questions to be answered On the following left hand page the same scans are to be found this time together with diagnosis and comments by the authors and with references corresponding to the problem for further reading However the cases in the book do not appear in any logical order

Many positive things may be said about the book In particular the brief but adequate comments on each case containing technical and diagnostic considerations and practical advice are very useful Admittedly many of these diagnostic points are well known to experienced examiners but the book is a good recapitulation and an excellent source of practical and theoretic information for those undergoing training in ultrasound

The cases are well selected with a wide spectrum of pathology presented in a pleasant way In the preface the authors state that this is important in order to stimulate the reader s interest The aim of the authors appears to have been achieved

Although a wide spectrum of abdominal pathology is presented a more detailed description of kidney rejection and some short remarks on abdominal biopsy and its contra indications and complications would have increased the value of the book

The illustrations are of reasonable quality and all of them are displayed as dark dots on a light background

All the cases contain numerous references

This book is highly recommended for experienced examiners as a recapitulation and it is also valuable for education in ultrasound

Wilhelm Karp

ACTA RADIOLOGICA

FOUNDED IN 19'1 BY GOSTA FORSSELL
PUBLISHED BY THE SOCIETIES OF MEDICAL RADIOLOGY IN DENMARK FINLAND NORWAY AND SWEDEN

DIAGNOSIS

MEDICAL IMAGING AND PHYSIOLOGIC RADIOLOGY

INDICES

Volume 21 (1980)

Printed in Sweden by Almqvist & Wiksell, Uppsala 1981

CONTENTS OF VOLUME 21 (1980)—DIAGNOSIS

SUBJECT INDEX TO VOLUME 21 (1980)—DIAGNOSIS

ROENTGEN DIAGNOSIS

Nervous system

Digestive tract (incl. biliary tract and spleen)

Heart and Vessels (incl. lymphatic system)

Lungs Pleura Mediastinum and Chest wall

Bones and Joints (incl soft tissue)

Ear Nose and Throat

Uro-genital system

ISOTOPES

COMPUTER TOMOGRAPHY

ULTRASOUND

TECHNIQUE

CONTRAST MEDIA

Lungs Pleura Mediastinum and Chest wall

Bones and Joints (incl soft tissue)

Ear, Nose and Throat

Uro-genital system

LIST OF AUTHORS

LIST OF SUPPLEMENTS TO ACTA RADIOLOGICA

Nos 201–363

(Issued 1980)

For Suppl Nos 1–200 inclusive see list issued 1979 in Vol 20 Fasc 6

The supplements are published from time to time and are not included in the subscription rate Prices and year of publication of numbers already issued are detailed below

201 GIOVANNI DI CHIRO RISA encephalography and conventional neuroradiologic methods A comparative study 1961 *Price Sw Kr 35*

202 LARS BJÖRK Velopharyngeal function in connected speech Studies using tomography and cineradiography synchronized with speech spectrography 1961 *Price Sw Kr 25*

203 BENGT O NYLÉN Cleft palate and speech A surgical study including observations on velopharyngeal closure during connected speech using synchronized cineradiography and sound spectrography 1961 *Price Sw Kr 25*

204 S R KJELLBERG B NORDENSTRÖM U RUDHE V O BJÖRK and G MALMSTRÖM Cardioangiographic studies of the mitral and aortic valves 1961 *Price Sw Kr 30*

205 GUNNAR CARLBERGER Kinetics and distribution of radioactive cobalt administered to the mammalian body 1961 *Price Sw Kr 30*

206 HANS MOËLL Kidney size and its deviation from normal in acute renal failure A roentgendiagnostic study 1961 *Price Sw Kr 25*

207 LEIF KULD HANSEN Micturition cystourethrography with automatic serial exposures An opinion on the value of the method 1961 *Price Sw Kr 30*

208 FINN LUNDWALL Cancer of the vulva A clinical review 1961 *Price Sw Kr 30*

209 ILMARI LINDGREN Anatomical and roentgenologic studies of tuberculous infections in BCG vaccinated and non vaccinated subjects with biophysical investigations of calcified foci 1961 *Price Sw Kr 25*

210 PER ERIK E BERGNER The significance of certain tracer kinetical methods especially with respect to the tracer dynamic definition of metabolic turnover 1962 *Price Sw Kr 30*

211 P VUORINEN P ANTTILA U WEGELIUS A KAUPPILA and E KOIVISTO Renal cortical index and other roentgenographic renal measurements 1962 *Price Sw Kr 25*

212 LARS ANDRÉN Pelvic instability in newborns with special reference to congenital dislocation of the hip and hormonal factors A roentgenologic study 1962 *Price Sw Kr 30*

213 NILS MAGNUS OHLSSON Left heart and aortic blood flow in the dog Precision motion analysis of high speed (270 frames/sec) cinefluorographic recordings 196[illegible] *Price Sw Kr 35*

214 BENGT TJERNBERG Lymphography An animal study on the diagnosis of V ×2 carcinoma and inflammation 1962 *Price Sw Kr 35*

215 PAAVO KLAMI Periarthrosis calcarea of the shoulder joint Its differentiation from other stiff and painful shoulders 1962 *Price Sw Kr 30*

216 P EDHOLM I FERNSTRÖM K LINDBLOM and S I SELDINGER Roentgen television in practice with special regard to puncture examinations 1962 *Price Sw Kr 35*

217 FOLKE EDSMYR Carcinoma of the vulva An analysis of 560 patients with histologically verified squamous cell carcinoma 1962 *Price Sw Kr 30*

218 P SOILA M GRÖNROOS O KAUPPILA und L PYYKÖNEN Wasserlösliche viskosierte wasserlösliche und jodölige Kontrastmittel in der Hysterosalpingographie Vergleichende Untersuchungen 1962 *Price Sw Kr 25*

219 STIG SANDMARK Hiatal incompetence Studies on mechanics and principles of examination for hiatus hernia and gastro oesophageal reflux 1963 *Price Sw Kr 25*

220 MAX LUNDBERG Free movements in the temporomandibular joint A cineradiographic study 1963 *Price Sw Kr 30*

221 ÅKE NORHAGEN Selective angiography of the hepatic veins Experimental investigations of basal circulatory dynamics 1963 *Price Sw Kr 35*

222 ERLING HAMMER JACOBSEN Genetically significant radiation doses in diagnostic radiology 1963 *Price Sw Kr 35*

223 ASTRID BROHULT Alkoxyglycerols and their use in radiation treatment An experimental and clinical study 1963 *Price Sw Kr 30*

224 CARL-OLOF OVENFORS Pulmonary interstitial emphysema—An experimental roentgendiagnostic study 1964 *Price Sw Kr 35*

225 GEORG THEANDER Variation in shape of gallbladder during cholecystography 1964 *Price Sw Kr 30*

226 HUGO BOKREN The composition and structure of human gallstones 1964 *Price Sw Kr 30*

227 LARS NORDQVIST The sagittal diameter of the spinal cord and subarachnoid space in different age groups—A roentgenographic post mortem study 1964 *Price Sw Kr 25*

266 GÖRAN NYLANDER Vascular response to vasopressin as reflected in angiography—An experimental study in the dog 1967 *Price Sw Kr 35*

267 JOHAN FOLIN Angiography in renal tumours—Its value in diagnosis and differential diagnosis as a complement to conventional methods 1967 *Price Sw Kr 35*

268 EERO TALA Carcinoma of the lung—A retrospective study with special reference to pre diagnosis period and roentgenographic signs 1967 *Price Sw Kr 35*

269 CARL O HENRIKSON Iodine 125 as a radiation source for odontological roentgenology 1967 *Price Sw Kr 35*

270 CATIONS IN INTRAVASCULAR CONTRAST MEDIA AND DEVELOPMENT OF SPECIFIC METRIZOATE FORMULAS — PHARMACOLOGIC AND CLINICAL STUDIES Proc Symposia at Copenhagen November 1964 and Sandefjord September 1966 1967 *Price Sw Kr 40*

271 ERNA TARKIAINEN Intracostal vein meningorachidography—A technical anatomic and clinical study 1967 *Price Sw Kr 35*

272 ALLAN LUNDERQUIST Arterial segmental supply of the liver—An angiographic study 1967 *Price Sw Kr 35*

273 KAI SETALA MAX SINRALA OTTO NYYSSÖNEN and ERNA TARKIAINEN Quantitative three dimensional scintillography of the stomach with technetium (^{99m}Tc) 1967 *Price Sw Kr 30*

274 PER BERGSJÖ Radiation induced early changes in size and vascularity of cervical carcinoma—A colpophotographic and clinical study 1968 *Price Sw Kr 35*

275 SUNE ERICSON The parotid gland in subjects with and without rheumatoid arthritis 1968 *Price Sw Kr 40*

276 ROLF JENSEN Anterior teeth relationship and speech —Studies using cineradiography synchronized with speech recording 1968 *Price Sw Kr 35*

277 SVEN AHLBÄCK Osteoarthrosis of the knee—A radiographic investigation 1968 *Price Sw Kr 35*

278 IRÈNE SJÖGREN KJELL BERGSTRÖM and HERMAN LODIN Echoencephalography in infants and children Comparison with cerebral pneumography in measuring ventricular size 1968 *Price Sw Kr 35*

279 BERTIL JARPLID Radiation induced asymmetry and lymphoma of thymus in mice 1968 *Price Sw Kr 35*

280 ERKKI M LAASONEN Information transmission in roentgen diagnostic chains—Experimental and clinical studies 1968 *Price Sw Kr 35*

281 RASMUS STENSTRÖM Arthrography of the knee joint in children—Roentgenologic anatomy diagnosis and the use of multiple discriminant analysis 1968 *Price Sw Kr 35*

282 KARL KARLSTEDT Carcinoma of the uterine corpus—Factors bearing on the curability 1968 *Price Sw Kr 35*

283 LEO STJERNVALL Pharmacodynamic response of epidermal hyperplasias to topical vinblastine treatment 1968 *Price Sw Kr 35*

284 HANS FLODH Distribution and kinetics of labelled vitamin B_{12} 1968 *Price Sw Kr 35*

285 ERKKI KOIVISTO Comparative study of roentgen diagnostic classifications—Computer analysis of 124 496 roentgen reports 1969 *Price Sw Kr 35*

286 JORGEN JENSEN Malformations of the inner ear in deaf children—A tomographic and clinical study 1969 *Price Sw Kr 35*

287 PENTTI J TASKINEN Radiotherapy and TNM classification of cancer of the larynx—A study based on 1447 cases seen at the Radiotherapy Clinic of Helsinki during 1936–1961 1969 *Price Sw Kr 35*

288 ROBERT T NASH Decision processes employing radioisotope scanning 1969 *Price Sw Kr 35*

289 SIRKKA WILJASALO Lymphographic polymorphism in Hodgkin s disease—Correlation of lymphography to histology and duration 1969 *Price Sw Kr 35*

290 ULF WELANDER Multicolor combination images in subtraction angiography—A new photographic method and its applications 1969 *Price Sw Kr 40*

291 ILONA SCHRECK PUROLA Failure of malignant epidermal cells to respond to vinblastine sulfate—A study in skin tumor resistant mice 1969 *Price Sw Kr 35*

292 GIOVANNI RUGGIERO GIANFRANCO CRISTI and CLAUDIO TREVISAN Clinical aspects of encephalography 1969 *Price Sw Kr 30*

293 PEKKA VIRTAMA and TAPIO HELELÄ Radiographic measurements of cortical bone—Variations in a normal population between 1 and 90 years of age 1969 *Price Sw Kr 20*

294 L STJERNVALL E E NISKANEN and J TARKKANEN Penetration of cytoplasmic barrier in malignant epidermal hyperplasia by colchicine in dimethyl sulfoxide—A polarization microscopic study in skin tumor resistant mice *1969 Price Sw Kr 20*

295 KAARINA TOURU KAISILA Heart size determination by photofluorography 1970 *Price Sw Kr 35*

296 HANS ROVSING Otosclerosis—A tomographic-clinical study 1970 *Price Sw Kr 35*

297 PER LANGELAND Population screening for female breast tumours A clinical investigation 1970 *Price Sw Kr 35*

298 JOHAN EDGREN Effect of cysteine on chromosome aberrations induced by radiation of human lymphocytes in vitro 1970 *Price Sw Kr 30*

299 RUNE SUNDGREN Selective angiography of the left gastric artery 1970 *Price Sw Kr 35*

300 NIELS KROIGAARD The lower urinary tract in infancy and childhood—Micturition cinematography with simultaneous pressure flow measurement 1970 (Out of print)

301 M VIIKERI Ultrasound examination of pleural plaques—Experimental pathologic and clinical studies 1970 *Price Sw Kr 35*

302 INGEMAR JOELSSON Radiotherapy of carcinoma of the uterine cervix with special regard to external irradiation 1970 *Price Sw Kr 35*

303 KAARINA AANTA Location of the placenta — A comparison between radiography ultrasound thermography isotopes 1971 *Price Sw Kr 25*

304 LENNART DIENER Intraosseous phlebography of the lower limb—Postmortem investigation of thrombotic venous disease 1971 *Price Sw Kr 40*

305 BERNDT STRÖMBERG The normal and diseased superficial flexor tendon in race horses—A morphologic and physiologic investigation 1971 *Price Sw Kr 35*

306 TRYGVE AAKHUS Angiography in acute mechanical obstruction of the small intestine 1971 *Price Sw Kr 40*

307 PERTTU METSALA Effect of dimethyl sulfoxide (DMSO) on cytoplasmic barrier of malignant epidermal cells—An investigation in skin tumor resistant mice 1971 *Price Sw Kr 35*

308 JORGEN RYGÅRD Mechanism of blood clearance of colloidal gold in mice—An atoxic clinical investigation using activation analysis 1971 *Price Sw Kr 35*

309 LAURI PATOMAKI A mathematical model for radiation fields of telecobalt treatment units—With special reference to the isodoses of Rocus 1971 *Price Sw Kr 35*

310 RADIOBIOLOGIC INVESTIGATIONS Edited by Erik Lindgren and Bernhard Tribukait 1971 *Price Sw Kr 45*

311 HALVOR VERMUND Enhancement of radiation effects by chemotherapy 1971 *Price Sw Kr 35*

312 PERTTI KASKI Osteomedullography of the tibia 1971 *Price Sw Kr 40*

313 PROCEEDINGS OF THE SIXTH CONFERENCE OF THE NORDIC ASSOCIATION OF CLINICAL PHYSICS held in Århus Denmark 1970 Edited by C B Madsen and K Lidén 1972 *Price Sw Kr 45*

314 BIRGER HELIN Heart volume in human kidney transplantation 1972 *Price Sw Kr 25*

315 UNO WEGELIUS Angiography of the hand Clinical and postmortem investigations 1972 *Price Sw Kr 35*

316 P E S PALMER Haemangiosarcoma of Kaposi 1972 *Price Sw Kr 35*

317 JUHANI RAUSTE Lymphographic findings in granulomatous inflammations and connective tissue diseases—Differential diagnosis between these diseases and lymphomas 1972 *Price Sw Kr 30*

318 OVE MATTSSON Formation of the tomographic image—With special reference to blurring 1972 *Price Sw Kr 35*

319 PROGRESS IN VETERINARY RADIOLOGY Proceedings of the 2nd International Conference of Veterinary Radiologists held in Stockholm 1970 Edited by Sten Erik Olsson 1972 *Price Sw Kr 45*

320 TJAKKO KUIPERS Carcinoma of the uterine cervix Aspects of clinical oncology in patients referred for radiation therapy 1972 *Price Sw Kr 50*

321 BO LUNDSTRÖM Angiographic abnormalities following percutaneous needle biopsy of the kidney 1972 *Price Sw Kr 40*

322 LARS BLOMQUIST Mode of accumulation of iodophenylalanines in the exocrine pancreas and certain tumours 1972 *Price Sw Kr 40*

323 INGER BROLIN Radiologic reporting 1973 *Price Sw Kr 40*

324 TIMO TELARANTA The role of host tissue in skin carcinogenesis—An investigation with skin tumor resistant and skin tumor susceptible mice 1973 *Price Sw Kr 35*

325 NILS GUNNAR LINDQUIST Accumulation of drugs on melanin 1973 *Price Sw Kr 40*

326 JOHN ERIK JOHNSSON Hysterography and diagnostic curettage in carcinoma of the uterine body 1973 *Price Sw Kr 40*

327 ERIC BERGQUIST Tentorial notch and adjacent major vessels in carotid angiography 1973 *Price Sw Kr 45*

328 O HASSLER and S O HIETALA Angiographic abnormalities in the urinary bladder wall after irradiation Part I Animal experiments Part II Clinical investigation 1973 *Price Sw Kr 45*

329 OLOF ECKERDAL Tomography of the temporomandibular joint—Correlation between tomographic image and histologic sections in a three-dimensional system 1973 *Price Sw Kr 40*

330 JORMA RANTANEN Radiation injury of connective tissue—A biochemical investigation with experimental granuloma 1973 *Price Sw Kr 40*

331 FRANZ PAUL PROBST Congenital defects of the corpus callosum—Morphology and encephalographic appearances 1973 *Price Sw Kr 50*

332 GUDRUN ALM CARLSSON Dosimetry at interfaces—Theoretical analysis and measurements by means of thermoluminescent LiF 1973 *Price Sw Kr 40*

333 MATTI VALLE Postoperative coronary angiography 1973 *Price Sw Kr 40*

334 I JOELSSON A SANDRI and H L KOTTMEIER Carcinoma of the uterine corpus—A retrospective survey of individualized therapy 1973 *Price Sw Kr 40*

335 METRIZAMIDE A NON IONIC WATER SOLUBLE CONTRAST MEDIUM—Experimental and preliminary clinical investigations 1973 *Price Sw Kr 50*

336 SVEN SCHELLER and LARS MÅRTENSON Traumatic dislocation of the patella A radiographic investigation 1974 *Price Sw Kr 50*

337 OSSI KORHOLA Myocardial scintigraphy and estimation of regional blood flow with xenon 133 1974 *Price Sw Kr 40*

338 KURT ÅSTRAND and SVEN REICHMANN Optimised tomography Theoretical and practical analyses of the elimination of depiction errors in tomography 1974 *Price Sw Kr 40*

339 ILKKA SURAMO Lymphography in tuberculosis 1974 *Price Sw Kr 40*

340 EEVA NORDMAN ^{75}Se sodium selenite scintigraphy in diagnosis of tumours 1974 *Price Sw Kr 45*

341 ILPO LAUTEALA Pelvimetry with image intensifier camera A low radiation dose method 1974 *Price Sw Kr 50*

342 ANDERS MÖLLER Pneumography in paraventricular and intraventricular tumours of the posterior fossa 1974 *Price Sw Kr 60*

343 HÅKAN JORULF Roentgen diagnosis of intraperitoneal fluid A physical anatomic and clinical investigation 1975 *Price Sw Kr 55*

344 Skeletal development growth rate and hip dysplasia Experimental investigations with special reference to the effect of estrogens growth hormone and nutrition Edited by Sten Erik Olsson 1975 *Price Sw Kr 70*

345 HANS KUISK and FAIZ M KHAN Nominal standard dose and tumor standard dose Tables for radiation therapy planning and analysis 1975 *Price Sw Kr 65*

346 Computer tomography of brain lesions Edited by Erik Lindgren 1975 *Price Sw Kr 73*

347 Tenth Symposium Neuroradiologicum Edited by Erik Lindgren 1975 *Price Sw Kr 148*